

**DATE**

11/29/21

PRESENTING CLINICAL SIGNS

History: Elevated ALT and bile acids.

Lab Results: ALT = 442 (10-125); Bile acids preprandial = 8 (0-15); Bile acids postprandial = 75.8 (0-30).

Attached separately.

PATIENT

Bugs Powell

Date of Previous IntraPet Ultrasound: No previous IntraPet scans.

Sedation: Not required to complete full diagnostic ultrasound.

Stat Report: Not requested.

SPECIES

Canine

ULTRASONOGRAPHIC EXAMINATION OF THE ABDOMEN**Urinary System**

The **urinary bladder**, trigone, and pelvic urethra presented normal thicknesses and normal tone. The ureters were not visible which is normal. No uroliths or sediment were visualized and anechoic urine was present. No evidence of inflammatory or neoplastic changes was noted. Ureteral papillae were normal.

BREED

Maltese Mix

The residual prostate was slightly heterogenous and appears to be adequately regressing for a recently neutered patient. The prostate measured 1.3 cm.

SEX

Neutered male

The **kidneys** revealed normal size and structure, corticomedullary definition and ratio for this age. The cortices presented largely uniform texture with normal echogenic relationship to liver and spleen. Medullary structure differed distinctly from the cortex and no evidence of pelvic dilation was present. The capsules were acceptably uniform without significant irregularities. The right kidney measured 3.56 cm.

AGE

10/12/20

Adrenal Glands

Both **adrenal glands** were visualized and recognized as having normal shape, size, position and echogenicity for this breed. The phrenic vasculature, glandular echogenicity and detail were unremarkable. Capsule, cortex, and medullary definition were normal for this age patient. The right adrenal gland measured 1.75 x 0.46 cm at the caudal pole and 0.44 cm at the cranial pole. The left adrenal gland measured 1.51 x 0.52 cm at the caudal pole and 0.42 cm at the cranial pole.

WEIGHT

6 lbs

INTERPRETED BYEric Lindquist, DMV
DABVP, Cert. IVUSS**Spleen**

The **spleen** presented a smooth homogeneous parenchyma hyperechoic to liver and renal cortical parenchyma. The capsule was smooth without noticeable expansion or deviation from within the spleen or adjacent pathology. The splenic vasculature demonstrated normal volume without signs of congestion or thrombosis. No sonographic evidence of acute or chronic inflammatory, neoplastic, or infarctual changes was noted.

IMAGING PERFORMED BY

Rachel Brillhart RDMS

HOSPITAL NAME

Bay Country VH

Liver

The **liver** was uniform and fairly normal to slightly subnormal in size at 3.0 cm in short axis. The portal vein to vena cava to aortic ratio was 1:1:1 and each measured 0.5 cm. The gallbladder and common bile duct and the internal vascularity all appeared normal.

REFERRING VET

Dr. McLean

Gastrointestinal

Examination of the **gastrointestinal tract** revealed a stomach and intestine free of stasis, of normal wall thickness, acceptable curvilinear mural detail, and peristaltic activity. Small and large intestine demonstrated normal luminal chyme and stool consistency respectively. No obstructive or overt infiltrative disease was noted. No associated abnormal lymphatic activity was noted.

INVOICE

94181

Pancreas

The base and limbs of the **pancreas** were observed to be largely isoechoic to surrounding omental fat. Pancreatic duct and capsular contour were acceptably normal and parenchyma respected normal curvilinear patterns. No overt evidence of active inflammatory or neoplastic disease was noted.

ULTRASONOGRAPHIC FINDINGS

Minor microhepatica.

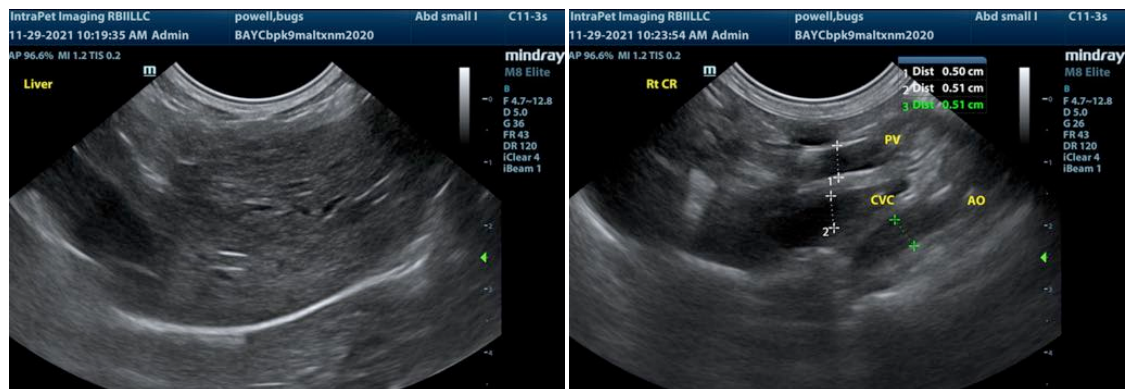
Undefined, low-grade inflammatory hepatopathy, possible microvascular dysplasia/portal hypoplasia.

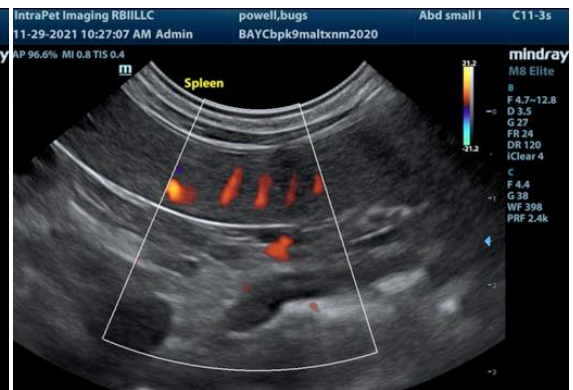
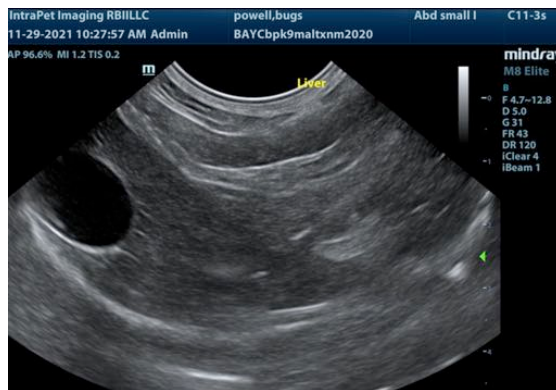
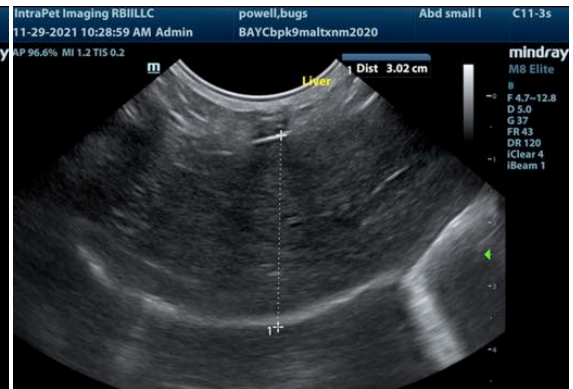
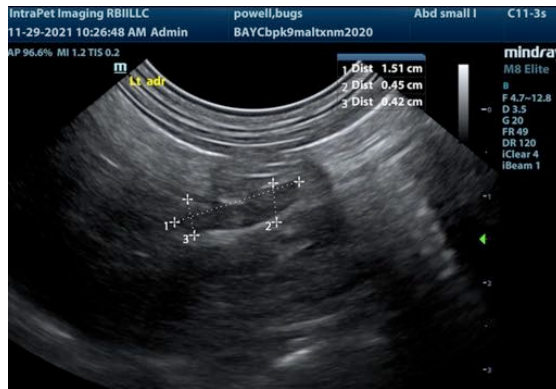
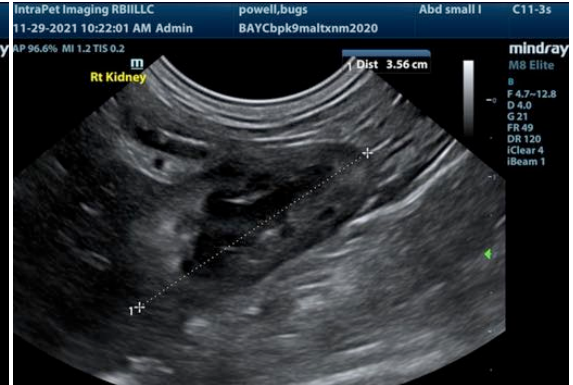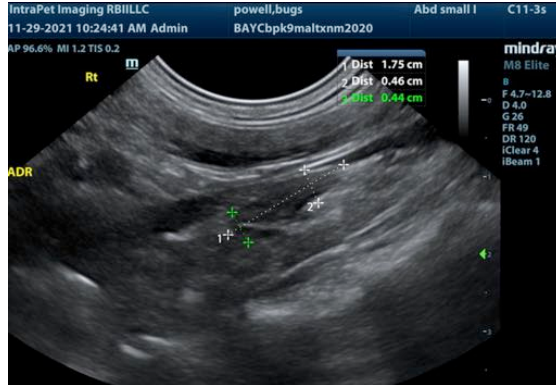
INTERPRETATION OF THE FINDINGS & FURTHER RECOMMENDATIONS

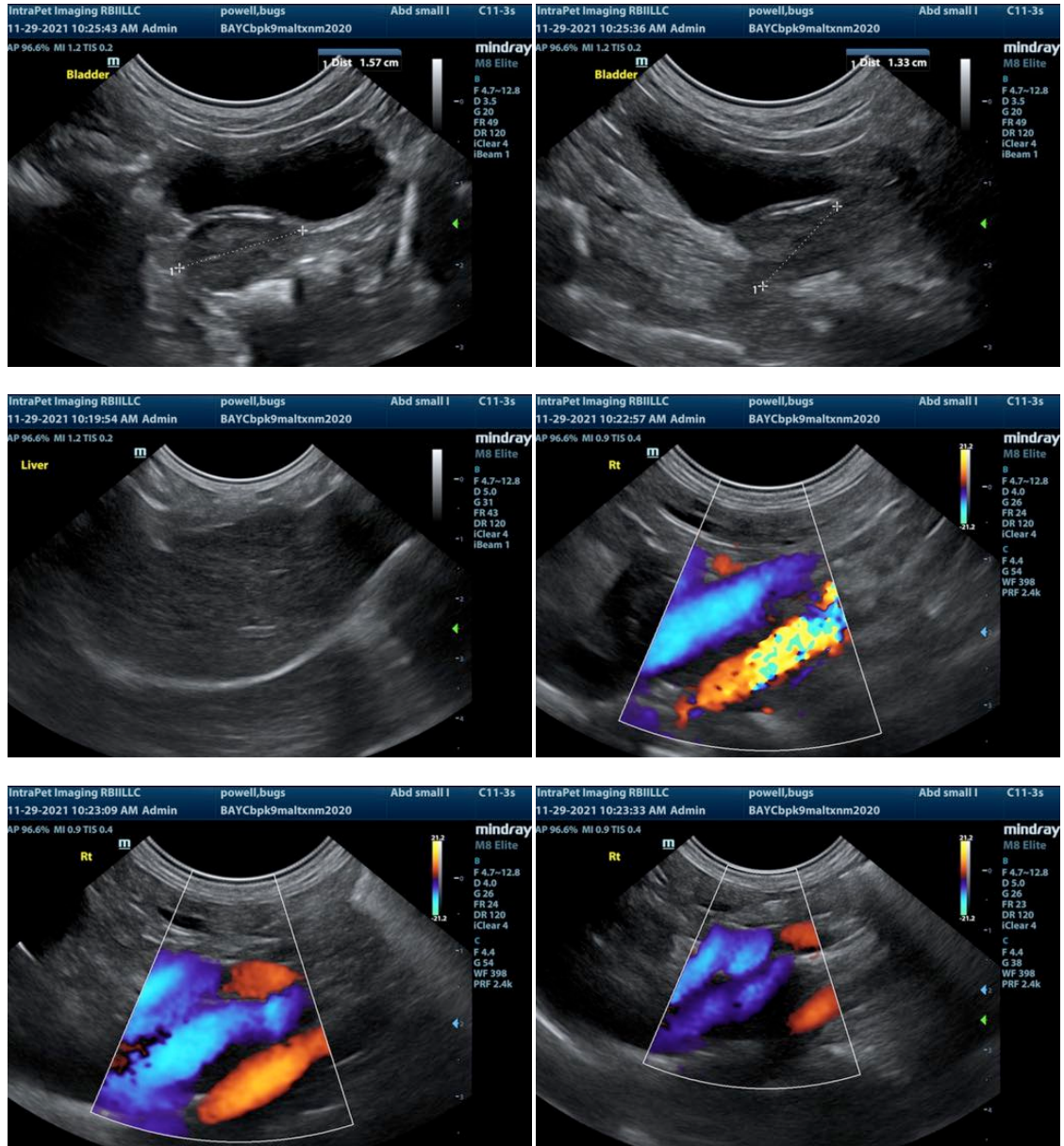
There was no evidence of macroscopic shunting. Leptospirosis titers +/- FNA or core biopsy is indicated for further definition.

Hepatic Support for Bile Acid Elevation +/- Hepatic Encephalopathy

Royal Canin Hepatic Support diet or Hills L/D, Metronidazole (7.5 mg/kg PO bid) over the next 14 days, Lactulose (Oral: 3.1-3.7 g/5 ml lactulose in a syrup base) long term to target 2-3 soft stools/day, with a high-quality protein supplement of minor amount of yogurt or cheddar cheese. Monitor bile acids, with attention paid to dropping albumin, BUN or cholesterol. SAME and nutraceuticals as needed. **Ursodiol (10-15 mg/kg p.o. q24h)** can be considered as hepatoprotectant and to enhance bile flow. **Zinc** serum level keep between 200–500 ug/dl. If deficient then Tx zinc acetate 1-3 mg/kg/day. Gastrointestinal protectants are recommended if the patient is anorexic.







The information and recommendations provided are based on the images presented by the referring veterinarian. No evaluation can be communicated regarding pathology that was not visible in the image/video clips provided.

Thank you for this referral. If the clinical or image interpretation does not parallel your findings or if I can be of any further assistance please contact me.

Eric Lindquist, DMV, DABVP, Cert. IVUSS, CEO of SonoPath.com
 Eric.Lindquist@SonoPath.com