



PATIENT

Fred Obarr

SPECIES

Canine

BREED

Basset Hound

SEX

Neutered male

AGE

9 years

WEIGHT

50 lbs

INTERPRETED BY

Eric Lindquist, DMV
DABVP, Cert. IVUSS

IMAGING PERFORMED BY

Kathleen Laux

HOSPITAL NAME

Rondout Valley VA

REFERRING VET

Dr. Page

INVOICE

69151

DATE

11/28/25

PRESENTING CLINICAL SIGNS

History: Patient has been having hematuria.
Abnormal PE/Chem/CBC/UA Results: sp Gr 1.050, RBC 168/hpf

ULTRASONOGRAPHIC EXAMINATION OF THE ABDOMEN

Urinary System

The **urinary bladder** revealed apical wall thickening with a trace amount of sand. The bladder wall measured 0.84 cm.

The **kidneys** revealed normal size and structure, corticomedullary definition and ratio for this age. The cortices presented largely uniform texture with normal echogenic relationship to liver and spleen. Medullary structure differed distinctly from the cortex and no evidence of pelvic dilation was present. The capsules were acceptably uniform without significant irregularities. The right kidney measured 6.82 cm. The left kidney measured 5.65 cm.

Adrenal Glands

Both **adrenal glands** were visualized and recognized as having normal shape, size, position and echogenicity for this breed. The phrenic vasculature, glandular echogenicity and detail were unremarkable. Capsule, cortex, and medullary definition were normal for this age patient. The left adrenal gland measured 2.6 x 0.67 cm at the cranial pole and 0.65 cm at the caudal pole. The right adrenal gland measured 2.17 x 0.5 cm at the cranial pole and 0.51 cm at the caudal pole.

Spleen

The **spleen** presented a smooth homogeneous parenchyma hyperechoic to liver and renal cortical parenchyma. The capsule was smooth without noticeable expansion or deviation from within the spleen or adjacent pathology. The splenic vasculature demonstrated normal volume without signs of congestion or thrombosis. No sonographic evidence of acute or chronic inflammatory, neoplastic, or infarctual changes was noted.

Liver

The **liver** images submitted revealed subjectively normal liver size, contour, and structure. Parenchymal echogenicity was naturally coarse and hypoechoic to the spleen. Vascular and biliary tracts were of normal volume with no evidence of congestion. The gallbladder presented acceptably thin walls with primarily anechoic content. The cystic and common bile ducts were normal. No pathological hepatic lymphadenopathy was evident. No overt structural evidence of inflammatory, infiltrative or regenerative pathology was evident.



PATIENT

Fred Obarr

SPECIES

Canine

BREED

Basset Hound

SEX

Neutered male

AGE

9 years

WEIGHT

50 lbs

INTERPRETED BY

Eric Lindquist, DMV
DABVP, Cert. IVUSS

IMAGING PERFORMED BY

Kathleen Laux

HOSPITAL NAME

Rondout Valley VA

REFERRING VET

Dr. Page

INVOICE

69151

DATE

11/28/25

Gastrointestinal

Examination of the **gastrointestinal tract** revealed a stomach and intestine free of stasis, of normal wall thickness, acceptable curvilinear mural detail, and peristaltic activity. Small and large intestine demonstrated normal luminal chyme and stool consistency respectively. No obstructive or overt infiltrative disease was noted. No associated abnormal lymphatic activity was noted.

Pancreas

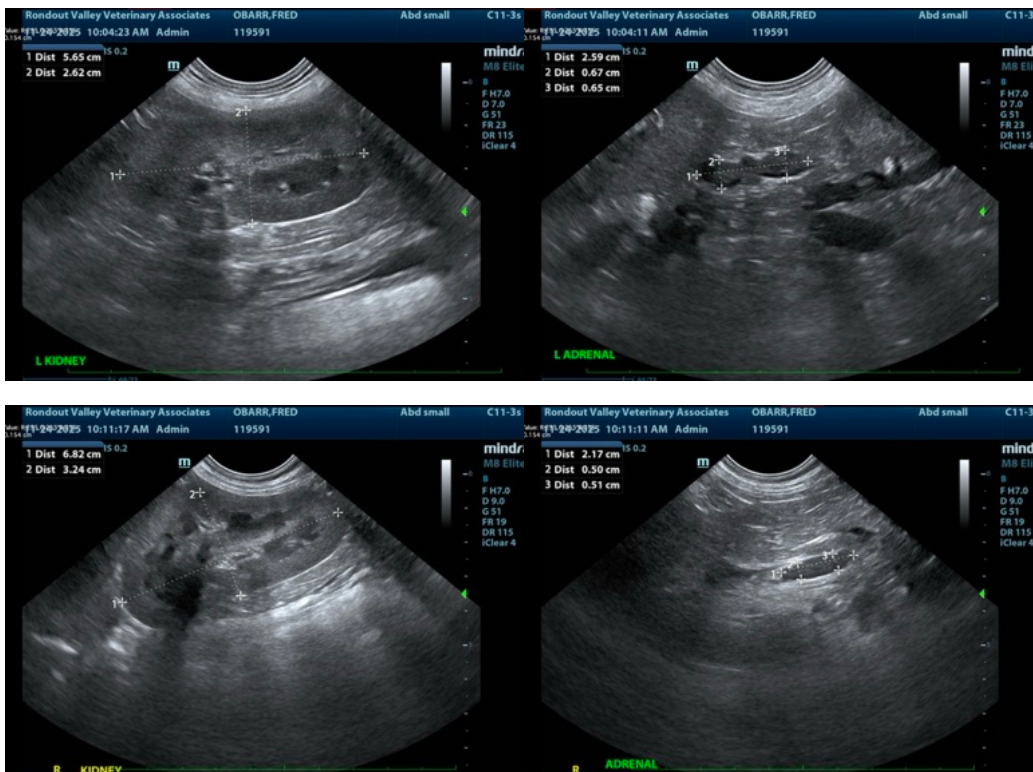
The base and limbs of the **pancreas** were observed to be largely isoechoic to surrounding omental fat. Pancreatic duct and capsular contour were acceptably normal and parenchyma respected normal curvilinear patterns. No overt evidence of active inflammatory or neoplastic disease was noted.

ULTRASONOGRAPHIC FINDINGS

Mild bladder thickening, non-specific. Trace bladder sand and minor cystitis pattern.

INTERPRETATION OF THE FINDINGS & FURTHER RECOMMENDATIONS

I cannot rule out pelvic urethra or prostatic pathology. Further imaging of the pelvic urethra SDEP 3 position is indicated given the patient's history.





PATIENT

Fred Obarr

SPECIES

Canine

BREED

Basset Hound

SEX

Neutered male

AGE

9 years

WEIGHT

50 lbs

INTERPRETED BY

Eric Lindquist, DMV
DABVP, Cert. IVUSS

IMAGING PERFORMED BY

Kathleen Laux

HOSPITAL NAME

Rondout Valley VA

REFERRING VET

Dr. Page

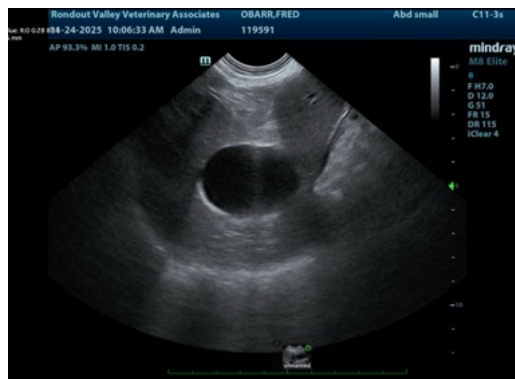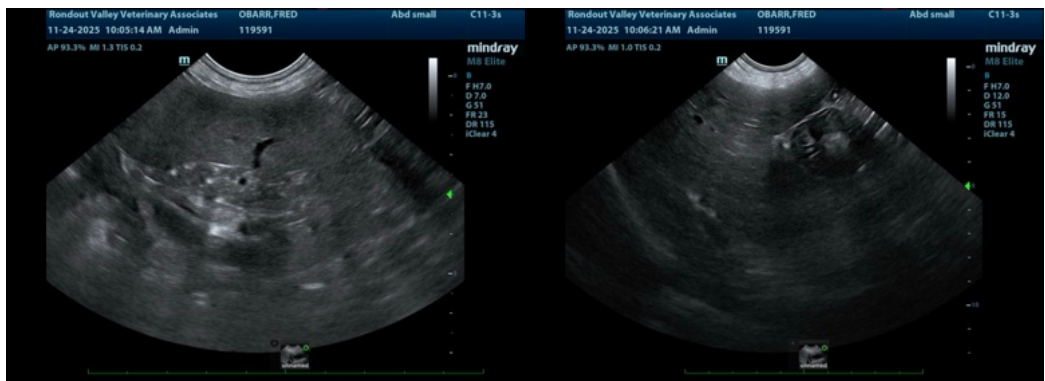
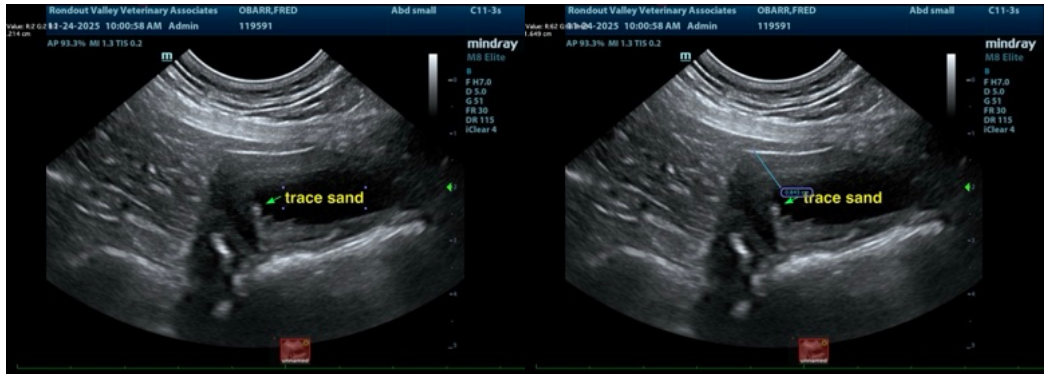
ADDENDUM 11/28/25

INVOICE

69151

DATE

11/28/25



The pelvic urethra and prostate were within the normal limits. The prostate measured 1.0 cm



PATIENT

Fred Obarr

SPECIES

Canine

BREED

Basset Hound

SEX

Neutered male

AGE

9 years

WEIGHT

50 lbs

INTERPRETED BY

Eric Lindquist, DMV
DABVP, Cert. IVUSS

IMAGING PERFORMED BY

Kathleen Laux

HOSPITAL NAME

Rondout Valley VA

REFERRING VET

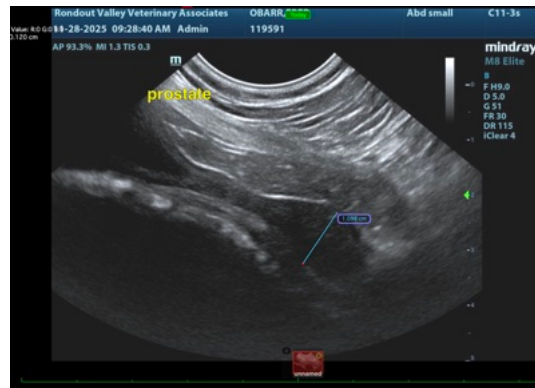
Dr. Page

INVOICE

69151

DATE

11/28/25



The information and recommendations provided are based on the images presented by the referring veterinarian/sonographer. No evaluation can be communicated regarding pathology that was not visible in the image/video clips provided.

Thank you for this referral. If the clinical or image interpretation does not parallel your findings or if I can be of any further assistance please contact me.

Eric Lindquist, DMV, DABVP (CFM), Cert. IVUSS, CEO of SonoPath.com

info@SonoPath.com