



PATIENT

Maylo Corredor Rivera

SPECIES

Feline

BREED

DSH

SEX

Intact Male

AGE

7 Months

WEIGHT

8.9 Pounds

INTERPRETED BY

Eric Lindquist, DMV
DABVP, Cert. IVUSS

IMAGING PERFORMED BY

Dr. G. Ferrer, DVM

HOSPITAL NAME

Paseos VC

REFERRING VET

Dr. Ramos

INVOICE

18852

DATE

11/28/22

PRESENTING CLINICAL SIGNS

History: The patient has been referred for an urgent Thorax Non-cardiac ultrasound due to respiratory distress and pleural effusion. Fluids was aspirated at another clinic and it is pending. FNA of thoracic masses were done and they are pending.

Abnormal PE/Chem/CBC/UA Results: CBC: HCT 45.86; PLT 93 FeLV: Positive Thoracic rads added as supporting document

LIMITED ULTRASONOGRAPHIC EXAMINATION

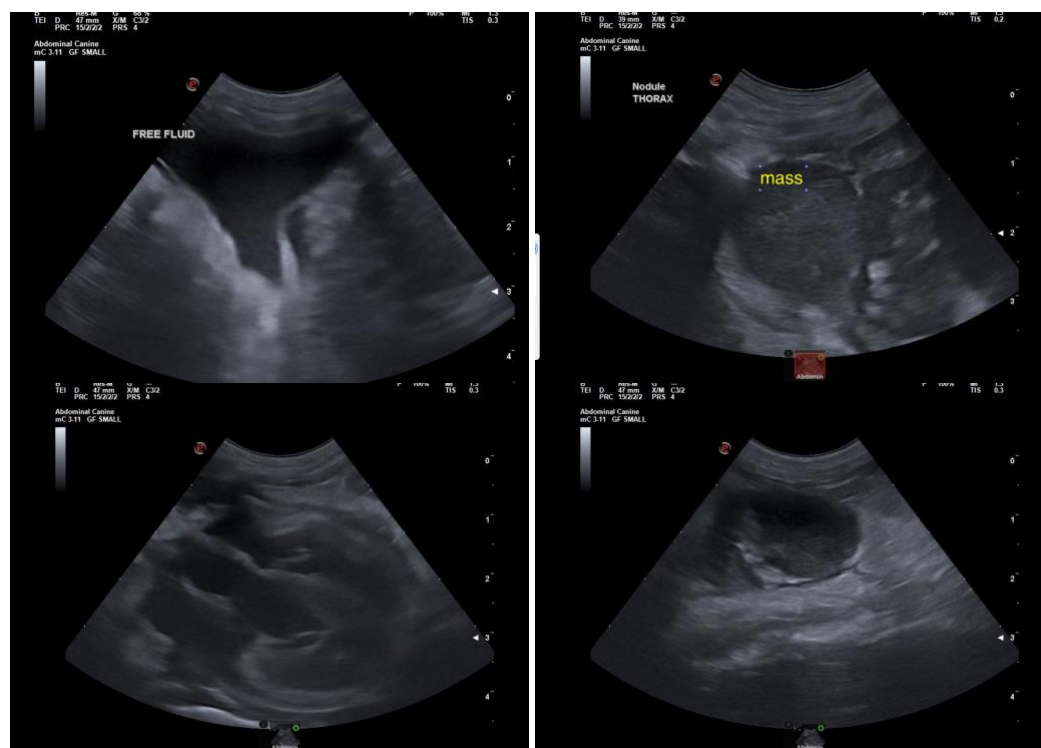
A large amount of echogenic free fluid was noted in the thorax of this patient. Multifocal parenchymal masses were noted, coalescing to approximately 4.0 cm. The heart appeared to be volume contracted. No evidence of primary cardiac disease present causing the pleural effusion. Cranial mediastinal lymph nodes are enlarged, rounded, hypochoic and irregular.

ULTRASONOGRAPHIC FINDINGS

- Thoracic neoplasia or FIP type presentation

INTERPRETATION OF THE FINDINGS & FURTHER RECOMMENDATIONS

Treatment based on FNA results is recommended. No evidence of cardiac involvement. Minor potential for diffuse thoracic infectious disease such fungal, cryptococcus or similar.



The information and recommendations provided are based on the images presented by the referring veterinarian. No evaluation can be communicated regarding pathology that was not visible in the image/video clips provided.



PATIENT

Maylo Corredor Rivera

Thank you for this referral. If the clinical or image interpretation does not parallel your findings or if I can be of any further assistance please contact me.

SPECIES

Feline

Eric Lindquist, DMV, DABVP, Cert. IVUSS, CEO of SonoPath.com
info@SonoPath.com

BREED

DSH

SEX

Intact Male

AGE

7 Months

WEIGHT

8.9 Pounds

INTERPRETED BY

Eric Lindquist, DMV
DABVP, Cert. IVUSS

**IMAGING
PERFORMED BY**

Dr. G. Ferrer, DVM

HOSPITAL NAME

Paseos VC

REFERRING VET

Dr. Ramos

INVOICE

18852

DATE

11/28/22