



PATIENT

Fatteh Suliman

SPECIES

Feline

BREED

Domestic Shorthair

SEX

Spayed female

AGE

2 years

WEIGHT

3.62 lbs

INTERPRETED BY

Eric Lindquist, DMV
DABVP, Cert. IVUSS

IMAGING PERFORMED BY

Dr. Samad Khan

HOSPITAL NAME

The Veterinary Surgery

REFERRING VET

Dr. Khan

INVOICE

69151

DATE

11/27/25

PRESENTING CLINICAL SIGNS

History: Fatteh is a 2-year-old DSH spayed, weighing 3.62 kgs, with a history of vomiting, losing weight, not doing well, a small fluid-like opacity at the base of the heart and on auscultation, arrhythmia

ULTRASONOGRAPHIC EXAMINATION OF THE HEART

Rapid view of the heart revealed biatrial enlargement with slight pericardial effusion, hypocontractility with smoke. Septal and free wall thicknesses were normal to thin. Pleural effusion was also noted. Significant arrhythmia was noted.

FELINE CARDIAC PARAMETERS	BODY WEIGHT	HR (BPM)	IVSd (cm)	LVIDd (cm)	LVWd (cm)	FS (%)	EF (%)
NORMAL PARAMETER	-----	150-240	0.3-0.6	1.0-2.1	0.25-0.6	35-67	80-100
PATIENT	3.62 lbs	180	0.47	1.25	0.55	20-30%	NM
FELINE CARDIAC PARAMETERS	LA/AO (M-mode)	LA/AO HEART BASE (Sisson)	LAD LA MAX 4 Chamber		LVOT VEL. (m/s)	RVOT VEL. (m/s)	IVRT (m/)
NORMAL PARAMETER	<1.5	1.6	0.7-1.7		<1.6	<1.3	40-60
PATIENT	NM	NM	NM		NM	NM	NM
Adapted from June Boon, Veterinary Echocardiography, 1998 Sisson D et al. JVIM 1991; 5: 232, Jacobs et al. Am J Vet Res 1985; 46:1705							

ULTRASONOGRAPHIC FINDINGS

Bilateral heart failure, DCM or UCM type presentation with smoke.

Significant arrhythmia.

INTERPRETATION OF THE FINDINGS & FURTHER RECOMMENDATIONS

Quadrotherapy is recommended with Pimobendan at 0.3 mg/kg b.i.d. off label, Lasix at 12.5 mg b.i.d. diminishing to 6.25 mg b.i.d. Plavix therapy is indicated as well as ace inhibitor therapy. Prognosis is extremely guarded. Taurine supplementation may be appropriate.



PATIENT

Fatteh Suliman

SPECIES

Feline

BREED

Domestic Shorthair

SEX

Spayed female

AGE

2 years

WEIGHT

3.62 lbs

INTERPRETED BY

Eric Lindquist, DMV
DABVP, Cert. IVUSS

IMAGING PERFORMED BY

Dr. Samad Khan

HOSPITAL NAME

The Veterinary Surgery

REFERRING VET

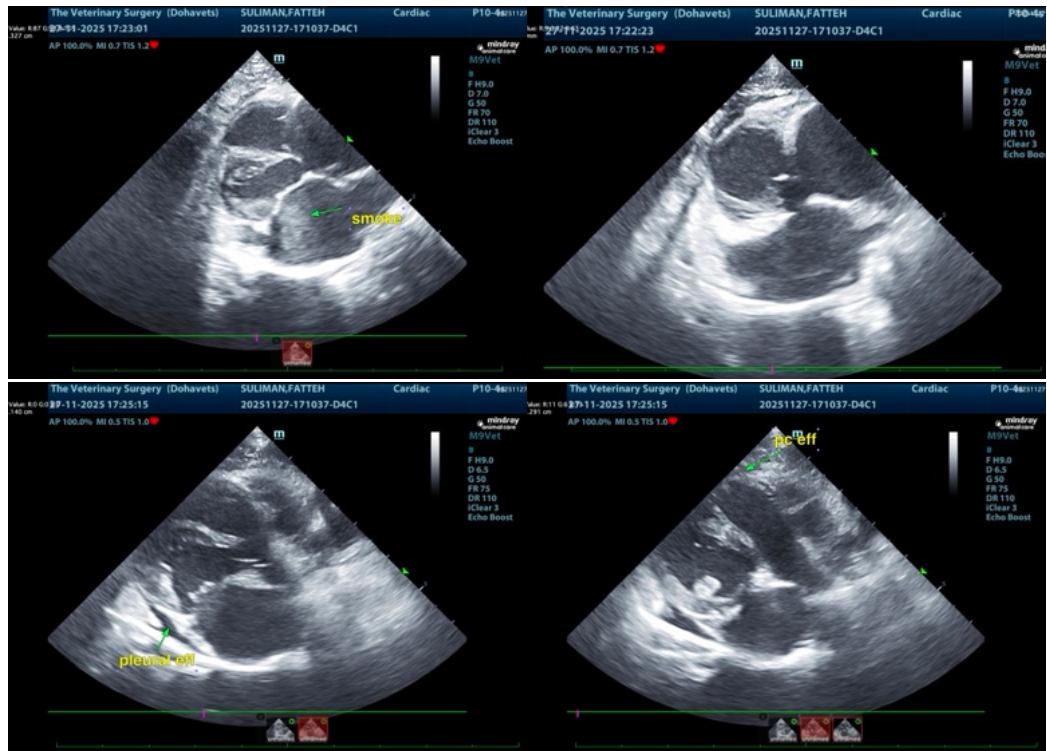
Dr. Khan

INVOICE

69151

DATE

11/27/25



The information and recommendations provided are based on the images presented by the referring veterinarian/sonographer. No evaluation can be communicated regarding pathology that was not visible in the image/video clips provided.

Thank you for this referral. If the clinical or image interpretation does not parallel your findings or if I can be of any further assistance please contact me.

Eric Lindquist, DMV, DABVP (CFM), Cert. IVUSS, CEO of SonoPath.com

info@SonoPath.com