

**DATE**

11/27/22

PRESENTING CLINICAL SIGNS

History: Presenting Complaint: Anorexia. Pancreatitis. Lethargic

PATIENT

History: Date: 11-26-2022 Notes: Was fine all day Thursday - around 10p was acting strange - does get specific treats at ed time, did eat the treats - afterwards would not settle down Started having diarrhea then turned into vomiting Friday AM was seen with rdvm - bw: Plt 734 - Cpl abnormal - gave SQ fluids, cerenia, metronidazole, gabapentin, cefpodoxime Did vomit after drinking before vet appointment - has not had any vomiting since his appointment This AM: would not eat or drink anything, syringed water - only medication he got On hills urinary c/d diet and treats Will occasionally get a bit of ice cream or bread - did not get anything on thursday - has no interested in people food yesterday - did try boiled chicken and rice as well Has had pancreatitis around 5 years ago Known bladder stones Known cushings Current medication: - Urosodial - got friday morning - Trilostane - last given thursday, 8-9a, 4-5p - Cerenia - got this AM, around 930 - Gabapentin -got friday pm - Metro - got friday around 4p - Cefpodoxime - Mometomax 2x/week Assessment: Anorexia. Lethargy. Abdominal pain.

Buster Wisner

SPECIES

Canine

BREED

Yorki-poo

SEX

Neutered Male

AGE

2009

WEIGHT

25 Pounds

Current Medications: Buprenorphine, Metronidazole, Vetoryl (Trilostane), Pantoprazole (Protonix), Dextrose 50% Solution Injection.

Lab Results: Attached.

Date of Previous IntraPet Ultrasound: No previous.

Sedation: Not required to complete full diagnostic ultrasound.

Stat Report: Not requested.

Imaging Performed By: Rachel Brillhart, RDMS.

INTERPRETED BY

Eric Lindquist, DMV
DABVP, Cert. IVUSS

Urinary System

The **urinary bladder** revealed a 7.0 mm acoustic shadowing calculus. The bladder itself was unremarkable.

HOSPITAL NAME

Animal Emergency
Hospital

The **kidneys** revealed largely normal size and structure, corticomedullary definition and ratio (cortex 1/3 of medulla) were essentially maintained with some mild age-related loss of curvilinear patterns regarding the capsule and C/M junction. The cortices presented largely uniform texture with some increased echogenicity expected for his age patient. Medullary structure differed distinctly from that of the cortex and no evidence of pelvic dilation was present. The left kidney measured 5.46 cm with multifocal hyperechoic punctiform inclusions related to likely Cushings disease. The right kidney measured 5.75 cm.

REFERRING VET

Dr. Nacke-Horney

Adrenal Glands

The **adrenal glands** appeared slightly enlarged and swollen. No evidence of focal capsular expansion or invasion into the phrenic veins were noted. No overt suspicion of neoplasia was noted. This is considered likely a hyperplastic change associated with stress or adrenal endocrinopathy (PDH). If isosthenuria is persistently present and the patient morphologically suggests Cushing's disease then ACTH testing would be indicated. The right adrenal gland measured 2.24 cm x 1.0 cm at the caudal pole and 0.9 cm at the cranial pole. The left adrenal gland measured 2.91 cm x 1.08 cm at the caudal pole and 1.03 cm at the cranial pole.

INVOICE

18844

Spleen

The **spleen** was normal size and relatively normal contour with multifocal hyperechoic areas of mineralization. This is a benign change; however, can be related to Cushing's disease or other endocrinopathies.

Liver

The **liver** was enlarged with coalescing hypoechoic micronodular changes with generalized swelling and hyperechoic parenchyma with attenuating sound beam. The gallbladder was distended extensively with striating bile consistent with mucocele formation, measuring 9.4 cm x 4.0 cm in long axis. A mixed hypoechoic mass was noted in the right medial liver, expansive, measuring 2.5 cm overlying the pancreas. Exact derivation from the liver or pancreas cannot be made.

Gastrointestinal

Examination of the **gastrointestinal tract** revealed a stomach and intestine free of stasis, of normal wall thickness, acceptable curvilinear mural detail, and peristaltic activity. Small and large intestine demonstrated normal luminal chyme and stool consistency respectively. No obstructive or overt infiltrative disease was noted. No associated abnormal lymphatic activity was noted.

Pancreas

The base and limbs of the **pancreas** were observed to be largely isoechoic to surrounding omental fat. Pancreatic duct and capsular contour were acceptably normal and parenchyma respected normal curvilinear patterns. No overt evidence of active inflammatory or neoplastic disease was noted. *See liver section.

Free Abdomen

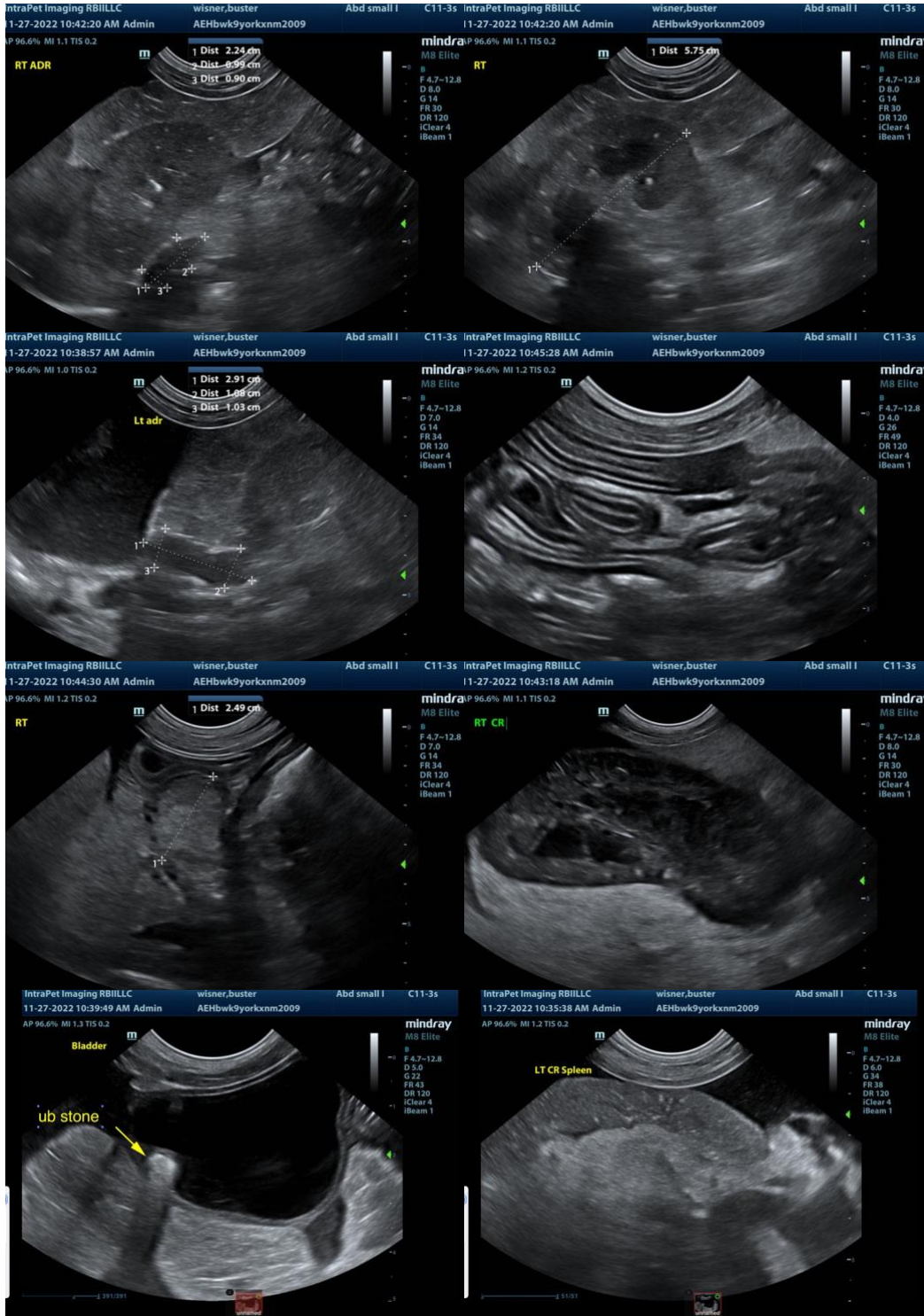
Undifferentiated hypoechoic 3.0 cm tissue was noted in the caudal **abdomen**, consistent with omentum. Other areas of irregular nodular omentum was noted in the cranial and caudal abdomen. A large amount of free fluid was noted.

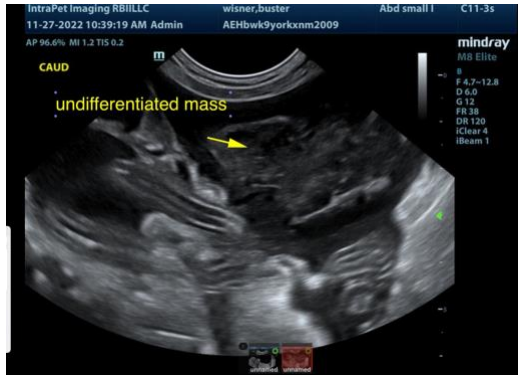ULTRASONOGRAPHIC FINDINGS

- Gallbladder mucocele
- Undefined nodular hepatic changes
- Ascites
- Mineralized splenic and renal parenchyma secondary to endocrinopathy
- Undefined hypoechoic tissue in the caudal abdomen
- Urinary bladder calculus
- Bilateral adrenal hypertrophy

INTERPRETATION OF THE FINDINGS & FURTHER RECOMMENDATIONS

Strong concern for carcinomatosis or similar neoplasia given the omental changes. Abdominocentesis and immediate cytospin and slide preparation for assessment of the cytology is warranted. Otherwise, direct exploratory surgery would be necessary, however, the irregular omental tissue does not appear to be cleanly resectable. Prognosis is very guarded to poor depending upon cytology results.





The information and recommendations provided are based on the images presented by the referring veterinarian. No evaluation can be communicated regarding pathology that was not visible in the image/video clips provided.

Thank you for this referral. If the clinical or image interpretation does not parallel your findings or if I can be of any further assistance please contact me.

Eric Lindquist, DMV, DABVP, Cert. IVUSS, CEO of SonoPath.com
info@SonoPath.com