



PATIENT	PRESENTING CLINICAL SIGNS
BB Petrunak/Crisafi	History: p presented for seizures that started this AM. P is known diabetic. p V+ 2 days ago and has not eaten since. O has been giving insulin despite not eating.
SPECIES	Abnormal PE/Chem/CBC/UA Results: BW NSF U/A pending FPL pending
Feline	ULTRASONOGRAPHIC EXAMINATION OF THE ABDOMEN
BREED	Urinary System
Main Coone	The urinary bladder , trigone, and pelvic urethra presented normal thicknesses and normal tone. The ureters were not visible which is normal. No uroliths or sediment were visualized and anechoic urine was present. No evidence of inflammatory or neoplastic changes were noted. Ureteral papillae were normal.
SEX	
Neutered Male	The kidneys revealed largely normal size and structure, corticomedullary definition and ratio (cortex 1/3 of medulla) were essentially maintained with some mild age-related loss of curvilinear patterns regarding the capsule and C/M junction. The cortices presented largely uniform texture with some increased echogenicity expected for his age patient. Medullary structure differed distinctly from that of the cortex and no evidence of pelvic dilation was present. The left kidney measured 3.47 cm. The right kidney measured 3.97 cm.
AGE	
15 Years	
WEIGHT	Adrenal Glands
13.21 Pounds	The regions of the adrenal glands revealed no evident pathology.
INTERPRETED BY	Spleen
Eric Lindquist, DMV DABVP, Cert. IVUSS	A hyperechoic lipogranulomatous nodule was noted in the spleen , measuring 4.0 mm at the caudal pole. The spleen was unremarkable otherwise.
IMAGING PERFORMED BY	Liver
Dr. Carver	The liver revealed mildly increased portal markings and coarse architecture. The gallbladder and common bile duct were unremarkable.
HOSPITAL NAME	Gastrointestinal
Animal Emergency Hospital, Deland	The stomach itself was unremarkable. Minor areas of spastic small intestine were noted with minor intestinal thickening noted. The GI tract was otherwise unremarkable.
REFERRING VET	Pancreas
Dr. A. Carver	Slight enhanced mesentery was noted in the adjacent to the left pancreatic limb with minor coarse architecture. Subxiphoid palpation is recommended to assess for pain or discomfort associated with the pancreas.
INVOICE	Free Abdomen
18835	The mesenteric lymph nodes (5.0 mm) presented normal length to width ratio with slight, swollen contour. There was no loss of parenchymal detail. This is most consistent with reactive lymphadenitis or lymphatic hyperplasia.
DATE	
11/27/22	



PATIENT

BB Petrunak/Crisafi

SPECIES

Feline

BREED

Main Coone

SEX

Neutered Male

AGE

15 Years

WEIGHT

13.21 Pounds

INTERPRETED BY

Eric Lindquist, DMV
DABVP, Cert. IVUSS

IMAGING PERFORMED BY

Dr. Carver

HOSPITAL NAME

Animal Emergency
Hospital, Deland

REFERRING VET

Dr. A. Carver

INVOICE

18835

DATE

11/27/22

ULTRASONOGRAPHIC FINDINGS

- Minor spastic bowel
- Possible very low grade pancreatitis
- Age-related renal changes
- A hyperechoic lipogranulomatous nodule in the spleen
- Mild increased portal markings and coarse architecture in the liver
- Reactive mesenteric lymph nodes

INTERPRETATION OF THE FINDINGS & FURTHER RECOMMENDATIONS

Subxiphoid palpation is recommended to confirm pancreatitis.

Potential Causes of Diabetic Dysregulation

This is a suggestive checkoff list when faced with an unregulated diabetic patient:

UTI

Dietary indiscretion/intolerance

Pancreatitis

Hyperthyroidism/hypothyroidism

Exogenous steroids (including topical eye meds)

Cushing's

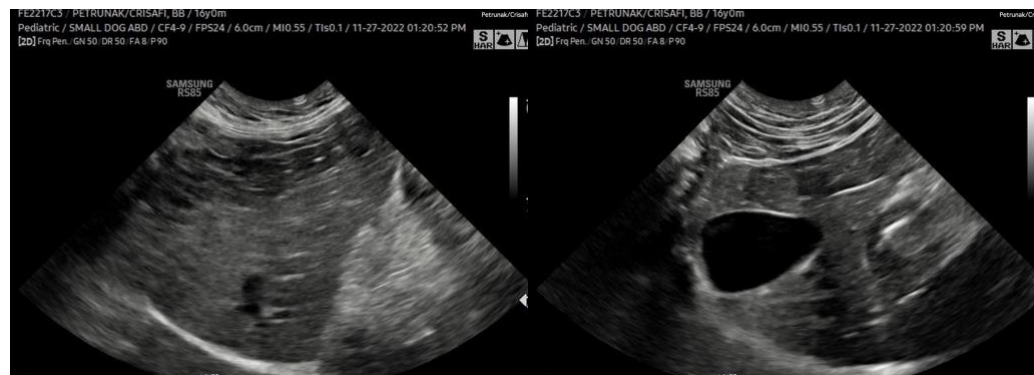
Acromegaly

Owner compliance

Insulin quality issues

Antibodies to insulin

Underlying Neoplasia





PATIENT

BB Petrunak/Crisafi

SPECIES

Feline

BREED

Main Coone

SEX

Neutered Male

AGE

15 Years

WEIGHT

13.21 Pounds

INTERPRETED BY

Eric Lindquist, DMV
DABVP, Cert. IVUSS

IMAGING PERFORMED BY

Dr. Carver

HOSPITAL NAME

Animal Emergency
Hospital, Deland

REFERRING VET

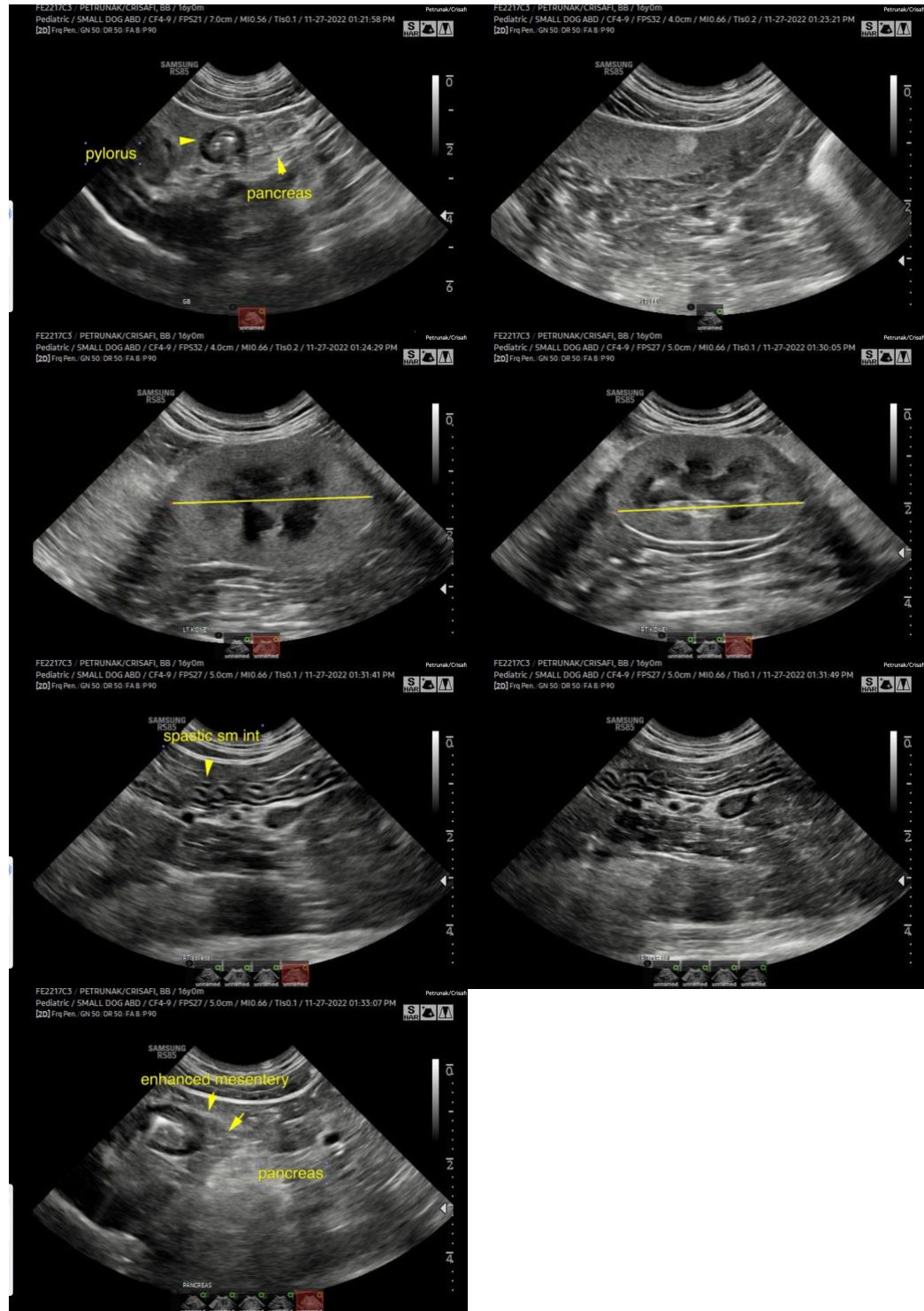
Dr. A. Carver

INVOICE

18835

DATE

11/27/22



The information and recommendations provided are based on the images presented by the referring veterinarian. No evaluation can be communicated regarding pathology that was not visible in the image/video clips provided.

Thank you for this referral. If the clinical or image interpretation does not parallel your findings or if I



PATIENT

can be of any further assistance please contact me.

BB Petrunak/Crisafi

SPECIES

Feline

BREED

Main Coone

SEX

Neutered Male

AGE

15 Years

WEIGHT

13.21 Pounds

INTERPRETED BY

Eric Lindquist, DMV
DABVP, Cert. IVUSS

**IMAGING
PERFORMED BY**

Dr. Carver

HOSPITAL NAME

Animal Emergency
Hospital, Deland

REFERRING VET

Dr. A. Carver

INVOICE

18835

DATE

11/27/22