



PATIENT

Gaia Draper

SPECIES

Canine

BREED

Mixed

SEX

Spayed Female

AGE

2 Years 5 Months

WEIGHT

47 Pounds

INTERPRETED BY

Eric Lindquist, DMV
DABVP, Cert. IVUSS

IMAGING PERFORMED BY

Sarah Green

HOSPITAL NAME

Healing Spirit AW

REFERRING VET

Sarah Green

INVOICE

18840

DATE

11/26/22

PRESENTING CLINICAL SIGNS

History: History of intermittent vomiting over the past 5 days. Anorexic this morning

Abnormal PE/Chem/CBC/UA Results: Kyphotic posture, tense abdomen, painful on palpation. CBC, chemistry, Spec cPL all WNL

ULTRASONOGRAPHIC EXAMINATION OF THE ABDOMEN

Urinary System

The **urinary bladder**, trigone, and pelvic urethra presented normal thicknesses and normal tone. The ureters were not visible which is normal. No uroliths or sediment were visualized and anechoic urine was present. No evidence of inflammatory or neoplastic changes were noted. Ureteral papillae were normal. The pelvic urethra was imaged 1.0 cm beyond the cystourethral junction.

The **kidneys** revealed normal size and structure, corticomedullary definition and ratio for this age. The cortices presented largely uniform texture with normal echogenic relationship to liver and spleen. Medullary structure differed distinctly from the cortex and no evidence of pelvic dilation was present. The capsules were acceptably uniform without significant irregularities. The left kidney measured 6.0 cm. The right kidney measured 6.0 cm.

Adrenal Glands

Both **adrenal glands** were visualized and recognized as having normal shape, size, position and echogenicity for this breed. The phrenic vasculature, glandular echogenicity and detail were unremarkable. Capsule, cortex, and medullary definition were normal for this age patient. The right adrenal gland measured 0.5 cm. The left adrenal gland measured 0.5 cm.

Spleen

The **spleen** presented a smooth homogeneous parenchyma hyperechoic to liver and renal cortical parenchyma. The capsule was smooth without noticeable expansion or deviation from within the spleen or adjacent pathology. The splenic vasculature demonstrated normal volume without signs of congestion or thrombosis. No sonographic evidence of acute or chronic inflammatory, neoplastic, or infarctual changes were noted.

Liver

The **liver** images submitted revealed subjectively normal liver size, contour, and structure. Parenchymal echogenicity was naturally coarse and hypoechoic to the spleen. Vascular and biliary tracts were of normal volume with no evidence of congestion. The gallbladder presented acceptably thin walls with primarily anechoic content. The cystic and common bile ducts were normal. No pathological hepatic lymphadenopathy was evident. No overt structural evidence of inflammatory, infiltrative or regenerative pathology was evident.

Gastrointestinal

The **stomach** presented a minor amount of luminal fluid and hyperperistalsis. Nonspecific gastritis/gastric irritation noted. The cecum was fluid filled. Excessive gas was noted.

Pancreas



PATIENT

Gaia Draper

The base and limbs of the **pancreas** were observed to be largely isoechoic to surrounding omental fat. Pancreatic duct and capsular contour were acceptably normal and parenchyma respected normal curvilinear patterns. No overt evidence of active inflammatory or neoplastic disease was noted.

SPECIES

Canine

ULTRASONOGRAPHIC FINDINGS

- Nonspecific gastritis presentation with fluid filled cecum and excessive gas

BREED

Mixed

INTERPRETATION OF THE FINDINGS & FURTHER RECOMMENDATIONS

Dietary indiscretion, food intolerance, structurally insignificant inflammatory bowel or occult parasitism and occult Addison's are all potentials. A clinical trial of the following may prove effective. Otherwise, endoscopy with mucosal biopsies would be indicated. Mid abdominal palpation is recommended to assess for any discomfort. Enterotoxins should be considered and empirical treatment.

SEX

Spayed Female

Helicobacter/Gastritis protocol

AGE

2 Years 5 Months

A clinical trial of **Zithromax (Dogs: 5-10 mg/kg p.o. q24h. May increase dosing interval to q48h after 3-5 days of treatment)**, **Metronidazole (10-20 mg/kg p.o. b.i.d.)**, **Pepcid (0.5-1 mg/kg s.i.d.)** and **Sucralfate (0.5-2 g/dog PO) or Omeprazole (1 mg/kg p.o. s.i.d.)** over the next 3 weeks along with a **novel-protein or hydrolyzed diet** with slurry feeding b.i.d./t.i.d. over the next 2-4 days and then increase to canned diet bid. Dry food should be avoided over the next 4 weeks. A recheck sonogram to assess GI improvement or progression would be ideal in 4 weeks.

WEIGHT

47 Pounds

INTERPRETED BY

Eric Lindquist, DMV
DABVP, Cert. IVUSS

IMAGING PERFORMED BY

Sarah Green

HOSPITAL NAME

Healing Spirit AW

REFERRING VET

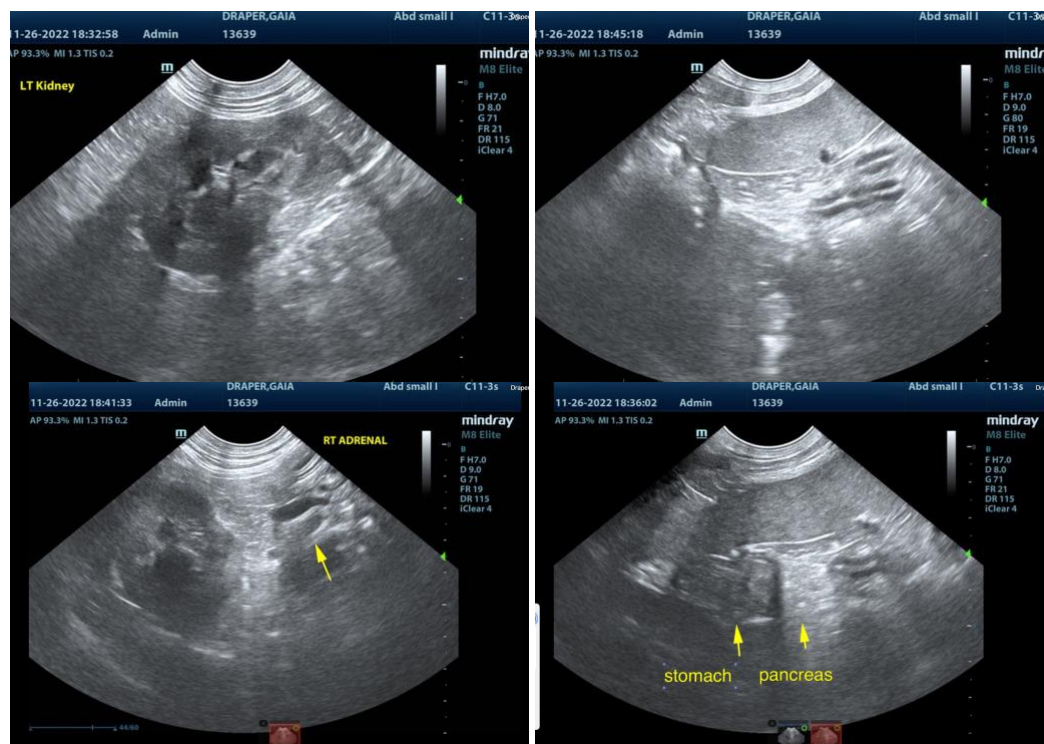
Sarah Green

INVOICE

18840

DATE

11/26/22





PATIENT

Gaia Draper

SPECIES

Canine

BREED

Mixed

SEX

Spayed Female

AGE

2 Years 5 Months

WEIGHT

47 Pounds

INTERPRETED BY

Eric Lindquist, DMV
DABVP, Cert. IVUSS

IMAGING PERFORMED BY

Sarah Green

HOSPITAL NAME

Healing Spirit AW

REFERRING VET

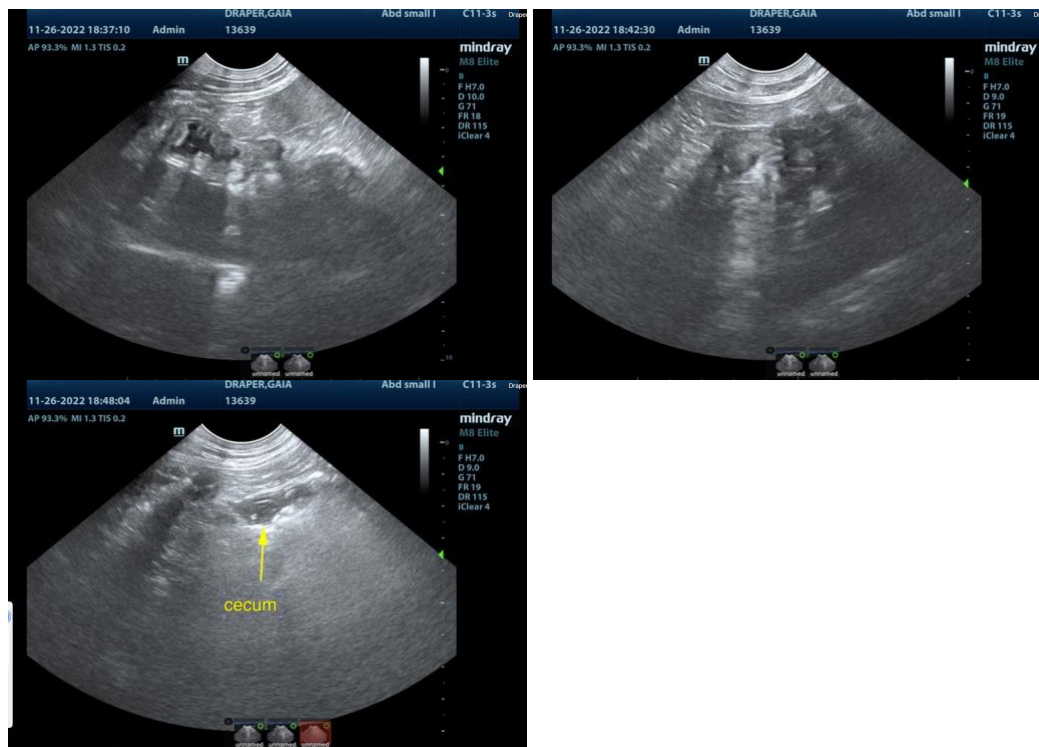Sarah Green

INVOICE

18840

DATE

11/26/22



The information and recommendations provided are based on the images presented by the referring veterinarian. No evaluation can be communicated regarding pathology that was not visible in the image/video clips provided.

Thank you for this referral. If the clinical or image interpretation does not parallel your findings or if I can be of any further assistance please contact me.

Eric Lindquist, DMV, DABVP, Cert. IVUSS, CEO of SonoPath.com
info@SonoPath.com