



PATIENT PRESENTING CLINICAL SIGNS

Bomber Ingenito

History: Pulmonary edema, history of lymphoma (CHOP protocol). Current treatments: O2 chamber support, CHOP protocol for lymphoma, lasix, spironolactone, Enalapril, vetmedin, and theophylline. Abnormal PE/Chem/CBC/UA Results: ALP 845.

SPECIES

Canine

ULTRASONOGRAPHIC EXAMINATION OF THE HEART

BREED

English Bulldog

The cardiac presentation in this patient presented tachyarrhythmia with hypocontractility. The left atrial size is at the upper limits of normal. The right atrial and left atrial ratio was 1:1. EPSS was excessive. The parameters are consistent with dilated cardiomyopathy. The hepatic veins were not dilated.

SEX

Neutered male

AGE

6 years

WEIGHT

80 lbs

INTERPRETED BY

Eric Lindquist, DMV
DABVP, Cert. IVUSS

CANINE CARDIAC PARAMETERS	MR VMAX (m/s)	TR VMAX (m/s)	LA/AO (Boon method)	LA/AO (Heart Base; Swe)	FS (%)	EF (%)	EPSS (cm)
NORMAL PARAMETER	4.5-5.5	<2.7	1.3	<1.6	28-40	40-100	<0.6
PATIENT	5.0		NM	1.6	22	55	1.0
CANINE CARDIAC PARAMETERS	HR (BPM)	AV VMAX (m/s)	PV MAX (m/s)	BODY WEIGHT	LA (2D short axis Base view) (cm)	LVIDd (Avg; 2D and m-mode short axis) (cm)	LVIDs (Avg; 2D and m-mode short axis) (cm)
NORMAL PARAMETER	50-100	0.7-1.7	0.7-1.6				
PATIENT	108	1.0	0.82	80 lbs	3.7 max	4.84	

ULTRASONOGRAPHIC FINDINGS

DCM type presentation.
Mild volume overload and moderate hypocontractility.

INTERPRETATION OF THE FINDINGS & FURTHER RECOMMENDATIONS

Arrhythmogenic activity is likely contributing to the subnormal contractility. I recommend STAT EKG. Antiarrhythmic medications are likely necessary. Regarding the current protocol I would not adjust the current quadratherapy. A recheck echocardiogram is recommended in 1-3 months depending upon clinical presentation.

REFERRING VET

Dr. Murphy

INVOICE

94118

DATE

11/26/21



PATIENT

Bomber Ingenito

SPECIES

Canine

BREED

English Bulldog

SEX

Neutered male

AGE

6 years

WEIGHT

80 lbs

INTERPRETED BY

Eric Lindquist, DMV
DABVP, Cert. IVUSS

IMAGING PERFORMED BY

Kelly Vazquez, CVT

HOSPITAL NAME

Westwood Regional
VH

REFERRING VET

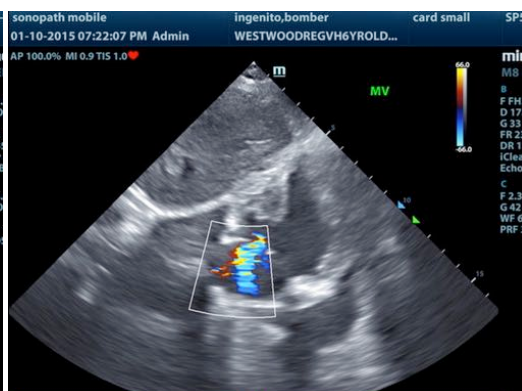
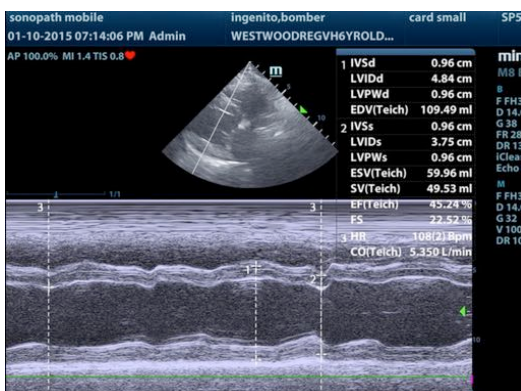
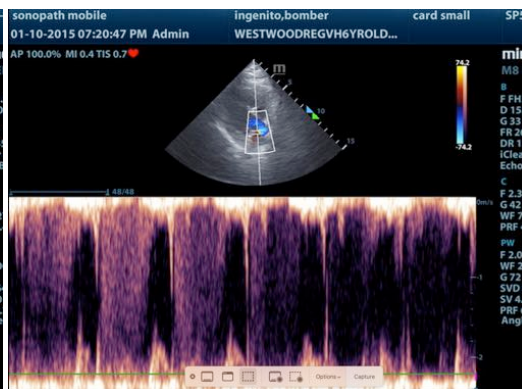
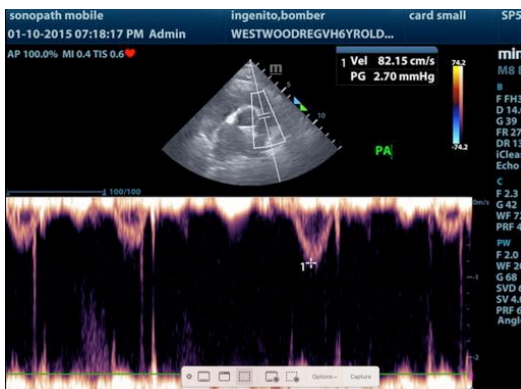
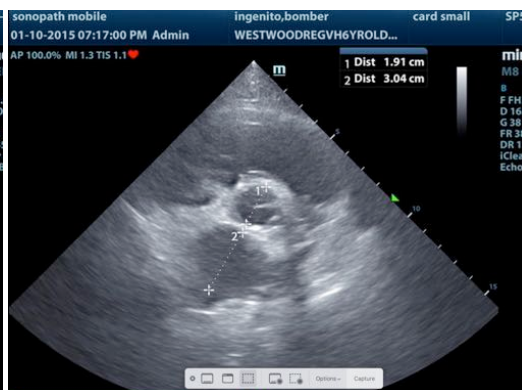
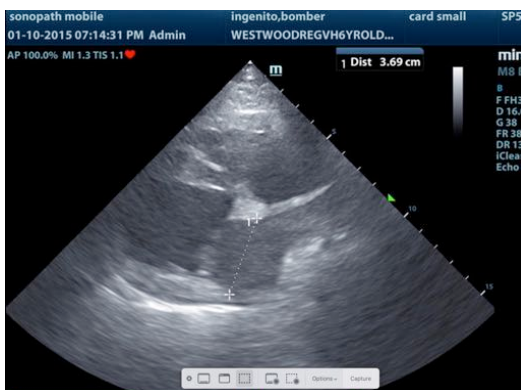
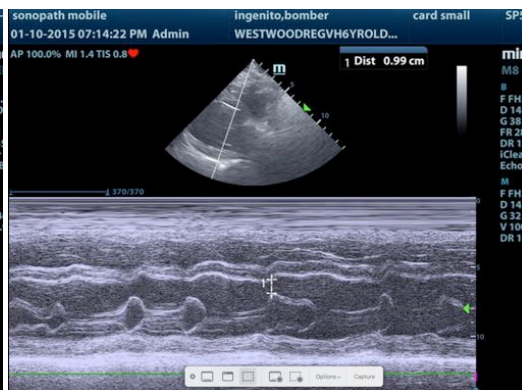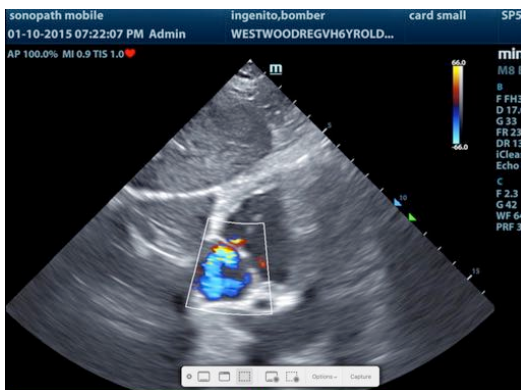
Dr. Murphy

INVOICE

94118

DATE

11/26/21





PATIENT

Bomber Ingenito

SPECIES

Canine

BREED

English Bulldog

SEX

Neutered male

AGE

6 years

WEIGHT

80 lbs

INTERPRETED BY

Eric Lindquist, DMV
DABVP, Cert. IVUSS

**IMAGING
PERFORMED BY**

Kelly Vazquez, CVT

HOSPITAL NAME

Westwood Regional
VH

REFERRING VET

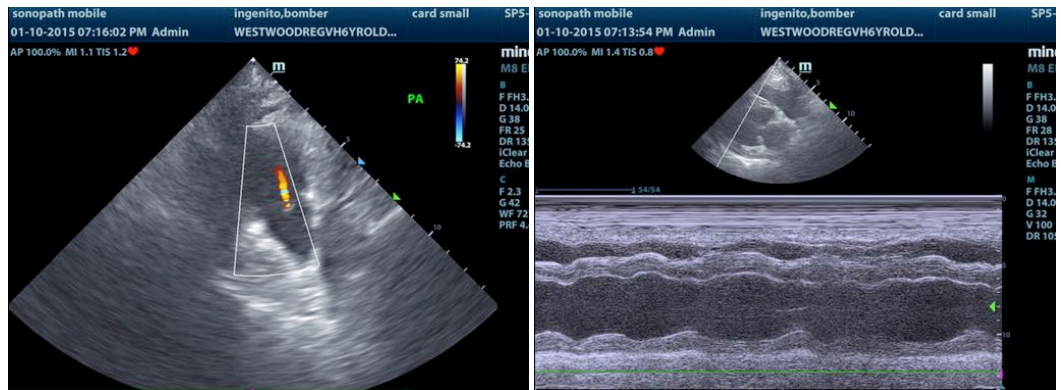
Dr. Murphy

INVOICE

94118

DATE

11/26/21



The information and recommendations provided are based on the images presented by the referring veterinarian. No evaluation can be communicated regarding pathology that was not visible in the image/video clips provided.

Thank you for this referral. If the clinical or image interpretation does not parallel your findings or if I can be of any further assistance please contact me.

Eric Lindquist, DMV, DABVP, Cert. IVUSS, CEO of SonoPath.com
info@SonoPath.com