



PATIENT

Princess Lewis

SPECIES

Feline

BREED

Domestic Shorthair

SEX

Spayed female

AGE

10 years

WEIGHT

8.12 lbs

INTERPRETED BY

Eric Lindquist, DMV
DABVP, Cert. IVUSS

IMAGING PERFORMED BY

Dr. Andrew Beachy

HOSPITAL NAME

Linn VH

REFERRING VET

Dr. Beachy

INVOICE

69054

DATE

11/25/25

PRESENTING CLINICAL SIGNS

History: On 8/22/25 Pt presents for chronic vomiting for the past 6 years. Pt has been vomiting 5 out of 7 days a week, and is defecating more often (5-6 times a day and they are malodorous) PT is also more vocal than normal, and has an Increased appetite.

Abnormal PE/Chem/CBC/UA Results: Normal physical exam on 8/22/25 Senior screen done 8/22/25 CBC NSF, K+ 5.4, Na:K ratio 28. Chem NSF, Chol 55 Urinalysis Pro 2+, Bld/hgb 3+, RBCs >100, Amm. Phosp. crystals 2+ (6-20/hpf) T4 WNL FeLV/FIV/HW Negative

ULTRASONOGRAPHIC EXAMINATION OF THE ABDOMEN

Urinary System

The **urinary bladder**, trigone, and pelvic urethra presented normal thicknesses and normal tone. The pelvic urethra was imaged 1.0 cm beyond the cystourethral junction and appeared normal. The ureters were not visible which is normal. No uroliths or sediment were visualized and anechoic urine was present. No evidence of inflammatory or neoplastic changes was noted. Ureteral papillae were normal.

The **kidneys** revealed normal size and structure, corticomedullary definition and ratio for this age. The cortices presented largely uniform texture with normal echogenic relationship to liver and spleen. Medullary structure differed distinctly from the cortex and no evidence of pelvic dilation was present. The capsules were acceptably uniform without significant irregularities. The left kidney measured 3.5 cm. The right kidney measured 3.13 cm.

Adrenal Glands

Both **adrenal glands** were visualized and recognized as having normal shape, size, position and echogenicity for this breed. The phrenic vasculature, glandular echogenicity and detail were unremarkable. Capsule, cortex, and medullary definition were normal for this age patient.

Spleen

The **spleen** revealed multi-focal, hyperechoic nodules were noted and measured up to 0.5 cm.

Liver

The **liver** revealed increased portal markings with uniform parenchyma. The gallbladder and common bile duct were unremarkable. The cystic duct was slightly tortuous.

Gastrointestinal

The **gastrointestinal** presentation revealed mild uniform prominence of the gastric mucosa as well as areas of "ropey" small intestinal wall with slight disruption of the normal 1:3 muscularis/mucosal ratio.



PATIENT

Princess Lewis

SPECIES

Feline

BREED

Domestic Shorthair

SEX

Spayed female

AGE

10 years

WEIGHT

8.12 lbs

INTERPRETED BY

Eric Lindquist, DMV
DABVP, Cert. IVUSS

IMAGING PERFORMED BY

Dr. Andrew Beachy

HOSPITAL NAME

Linn VH

REFERRING VET

Dr. Beachy

INVOICE

69054

DATE

11/25/25

The intestinal submucosa was slightly irregular, thickened and hyperechoic suggestive of low grade, chronic disease. No concerning lymphadenopathy was visible. No evidence of obstruction was present. Chronic inflammatory bowel disease is likely with a low possibility of an early neoplastic event such as lymphoma. Full thickness tissue biopsies via open laparotomy, ideally guided by intraoperative ultrasound in order to obtain the most representative mural sample, would be necessary to rule out this possibility.

Pancreas

The base and limbs of the **pancreas** were observed to be largely isoechoic to surrounding omental fat. Pancreatic duct and capsular contour were acceptably normal and parenchyma respected normal curvilinear patterns. No overt evidence of active inflammatory or neoplastic disease was noted.

ULTRASONOGRAPHIC FINDINGS

Diffuse intestinal thickening.

IBD GI Pattern.

Minor hepatic remodeling.

Splenic nodules, consistent with lipogranulomas

Otherwise, unremarkable abdomen.

INTERPRETATION OF THE FINDINGS & FURTHER RECOMMENDATIONS

Inflammatory bowel, food intolerance and occult parasitism are all potentials in this patient. Full thickness GI biopsies would be ideal for long term management. There was no evidence of suspicion of neoplasia.

Internal medicine consult can be utilized through SonoPath.com. You can select the internal medicine drop down at <http://spa.sonopath.com/>.

One of the world's top internists & SonoPath associate Dr. Remo Lobetti BVSc, MMedVet, PhD, DECVIM can evaluate your case through SonoPath. <https://sonopath.com/resources/sonopath-services/internal-medicine-teleconsultation-services>



PATIENT

Princess Lewis

SPECIES

Feline

BREED

Domestic Shorthair

SEX

Spayed female

AGE

10 years

WEIGHT

8.12 lbs

INTERPRETED BY

Eric Lindquist, DMV
DABVP, Cert. IVUSS

IMAGING PERFORMED BY

Dr. Andrew Beachy

HOSPITAL NAME

Linn VH

REFERRING VET

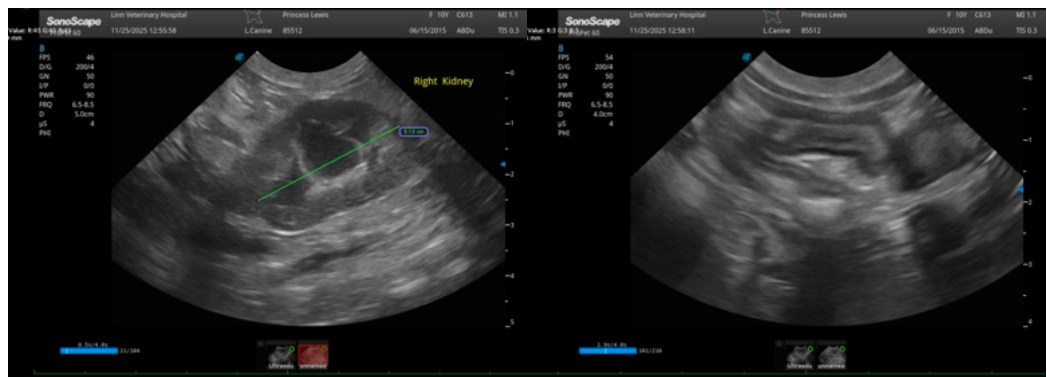
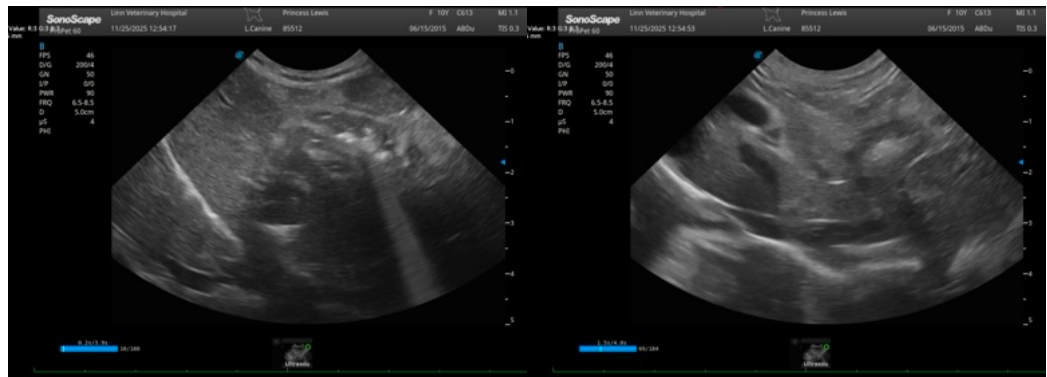
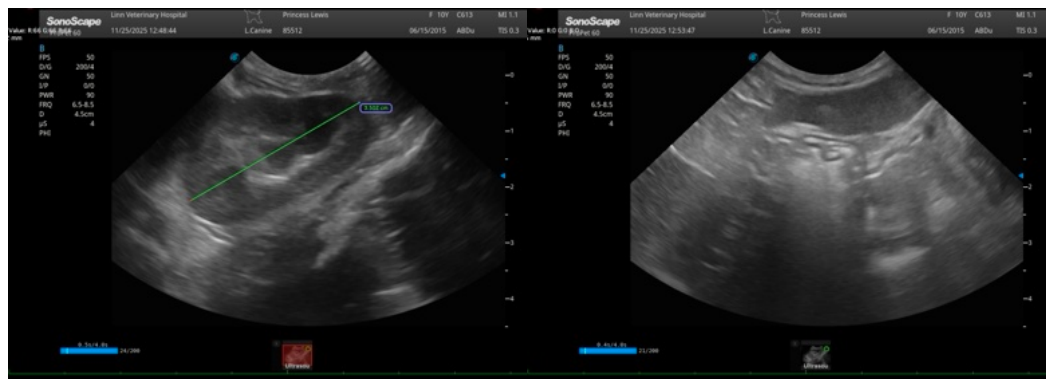
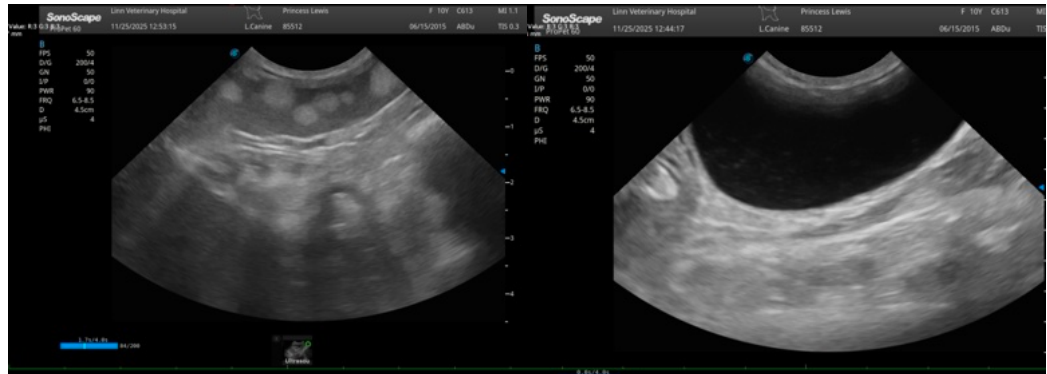
Dr. Beachy

INVOICE

69054

DATE

11/25/25





PATIENT

Princess Lewis

SPECIES

Feline

BREED

Domestic Shorthair

SEX

Spayed female

AGE

10 years

WEIGHT

8.12 lbs

INTERPRETED BY

Eric Lindquist, DMV
DABVP, Cert. IVUSS

IMAGING PERFORMED BY

Dr. Andrew Beachy

HOSPITAL NAME

Linn VH

REFERRING VET

Dr. Beachy

INVOICE

69054

DATE

11/25/25

The information and recommendations provided are based on the images presented by the referring veterinarian/sonographer. No evaluation can be communicated regarding pathology that was not visible in the image/video clips provided.

Thank you for this referral. If the clinical or image interpretation does not parallel your findings or if I can be of any further assistance please contact me.

Eric Lindquist, DMV, DABVP (CFM), Cert. IVUSS, CEO of SonoPath.com

info@SonoPath.com