



PATIENT

Carmelle Schimoler

SPECIES

Canine

BREED

Cockapoo

SEX

Spayed Female

AGE

8 Years

WEIGHT

21 lbs

PRESENTING CLINICAL SIGNS

Recheck echo last done 5/15/25, grade 3 HM bilateral

ULTRASONOGRAPHIC EXAMINATION OF THE HEART

CANINE CARDIAC PARAMETERS	MR VMAX (m/s)	TR VMAX (m/s)	LA/AO (M-Mode)	LA/AO (Heart Base; Swe)	FS (%)	EF (%)	EPSS (cm)
NORMAL PARAMETER	4.5-5.5	<2.7	1.3	Up to 1.6	28-40	40-100	<0.6
PATIENT	5.5	--	1.1	1.2	46	78	0.1
CANINE CARDIAC PARAMETERS	HR (BPM)	AV VMAX (m/s)	PV MAX (m/s)	BODY WEIGHT (lbs)	LAD LA MAX 4 Chamber	LVIDd Avg; 2D and m-mode short axis (cm)	LVIDs Avg; 2D and m-mode short axis (cm)
NORMAL PARAMETER	50-100	0.7-1.7	0.7-1.6				
PATIENT	80	1.25	1.0	21	2.9	2.99	--

INTERPRETED BY

Eric Lindquist, DMV, DABVP (CFM), Cert. IVUSS

IMAGING PERFORMED BY

Meghan Morse, LVT, CVT

HOSPITAL NAME

Black River Veterinary Hospital

REFERRING VET

Dr. Hill

INVOICE

72088

DATE

11/25/25

E-wave velocity = 0.9

Cardiac Presentation

The cardiac presentation presented no evidence of volume overload in any of the four changes. Moderate mitral insufficiency noted. Slight prolapse of the anterior mitral valve leaflet noted. Trivial tricuspid insufficiency noted. Contractility was adequately compensatory. No pericardial or pleural effusion. No evidence of passive congestion in the liver.

ULTRASONOGRAPHIC FINDINGS

- Stable B1 valvular disease

INTERPRETATION OF THE FINDINGS & FURTHER RECOMMENDATIONS

The heart is stable without clinical disease. No overt contraindication for anesthesia of brief to moderate duration. I suggest Torbutrol premed, Propofol induction, Isoflo maintenance or similar protocol if anesthesia is desired. Blood pressure, EKG and chest radiographs are recommended if not already performed. Target white coat negative systolic pressure of < 160 mmHg. If higher than this ACE-inhibitor is suggested to reach this level. Recheck echocardiogram is recommended in 6 months, earlier if murmur grade increases or clinical signs initiate.



PATIENT

Carmelle Schimoler

SPECIES

Canine

BREED

Cockapoo

SEX

Spayed Female

AGE

8 Years

WEIGHT

21 lbs

INTERPRETED BY

Eric Lindquist, DMV,
 DABVP (CFM), Cert.
 IVUSS

IMAGING PERFORMED BY

Meghan Morse, LVT,
 CVT

HOSPITAL NAME

Black River Veterinary
 Hospital

REFERRING VET

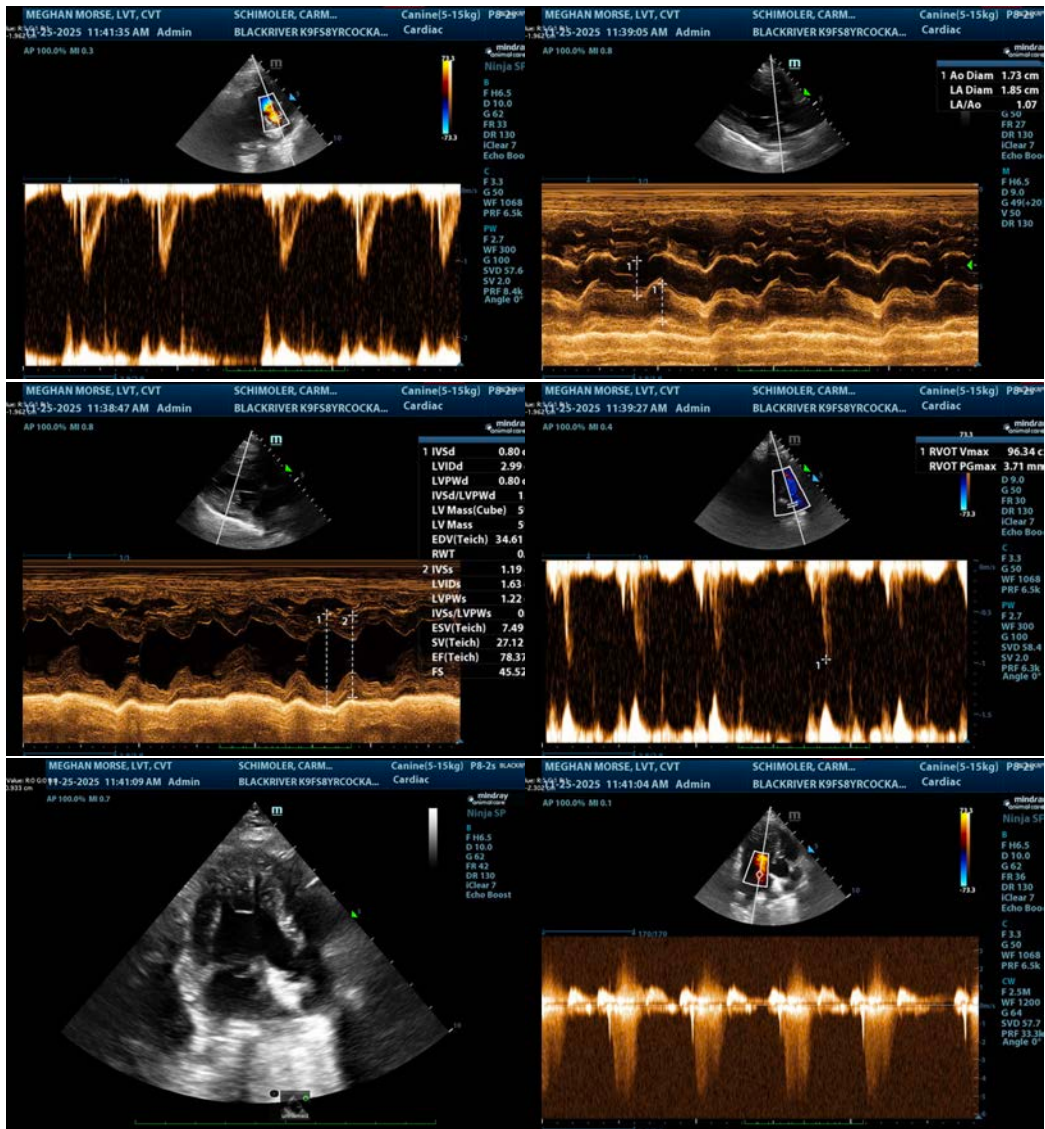
Dr. Hill

INVOICE

72088

DATE

11/25/25





PATIENT

Carmelle Schimoler

SPECIES

Canine

BREED

Cockapoo

SEX

Spayed Female

AGE

8 Years

WEIGHT

21 lbs

INTERPRETED BY

Eric Lindquist, DMV,
DABVP (CFM), Cert.
IVUSS

IMAGING PERFORMED BY

Meghan Morse, LVT,
CVT

HOSPITAL NAME

Black River Veterinary
Hospital

REFERRING VET

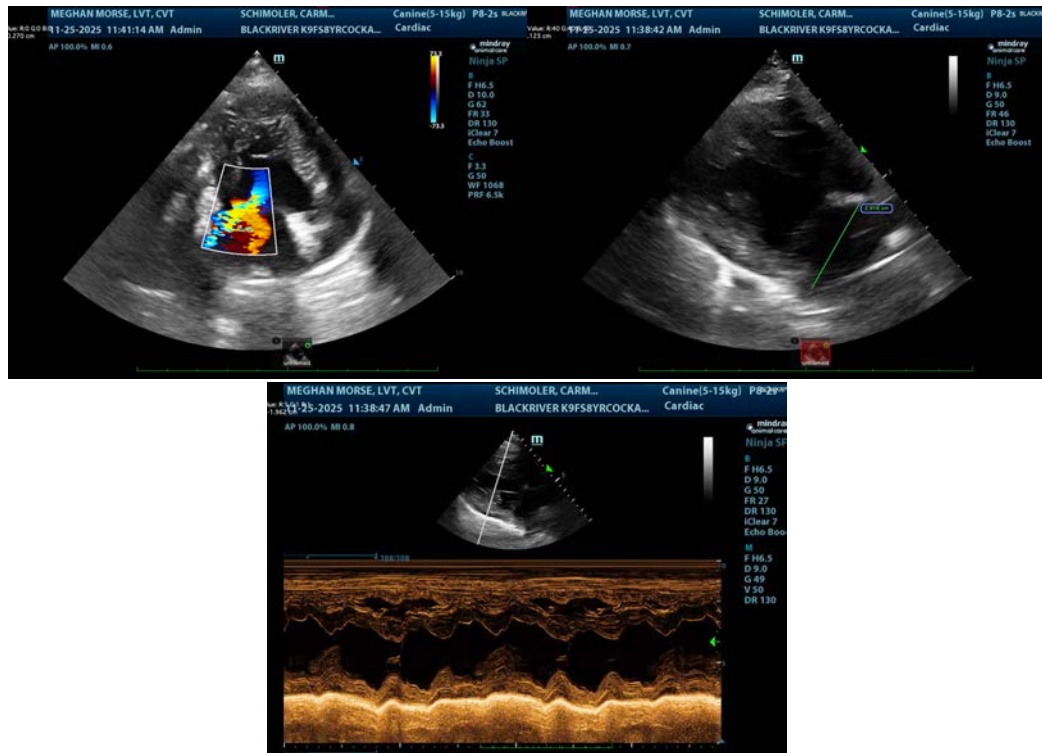
Dr. Hill

INVOICE

72088

DATE

11/25/25



The information and recommendations provided are based on the images presented by the referring veterinarian/sonographer. No evaluation can be communicated regarding pathology that was not visible in the image/video clips provided.

Thank you for this referral. If the clinical or image interpretation does not parallel your findings or if I can be of any further assistance please contact me.

Eric Lindquist, DMV, DABVP(CFM), Cert. IVUSS,
CEO, Owner, Founder -- SonoPath.com
info@SonoPath.com