



PATIENT

Baron McDevitt

SPECIES

Canine

BREED

Bichon Frise x

SEX

Neutered Male

AGE

11 Years

WEIGHT

23.4 lbs

PRESENTING CLINICAL SIGNS

Murmur 2, coughing but acting well. Meds: Furosemide

ULTRASONOGRAPHIC EXAMINATION OF THE HEART

CANINE CARDIAC PARAMETERS	MR VMAX (m/s)	TR VMAX (m/s)	LA/AO (M-Mode)	LA/AO (Heart Base; Swe)	FS (%)	EF (%)	EPSS (cm)
NORMAL PARAMETER	4.5-5.5	<2.7	1.3	Up to 1.6	28-40	40-100	<0.6
PATIENT	5.5	--	2.5	>2.2	49	81	0.1
CANINE CARDIAC PARAMETERS	HR (BPM)	AV VMAX (m/s)	PV MAX (m/s)	BODY WEIGHT (lbs)	LAD LA MAX 4 Chamber	LVIDd Avg; 2D and m-mode short axis (cm)	LVIDs Avg; 2D and m-mode short axis (cm)
NORMAL PARAMETER	50-100	0.7-1.7	0.7-1.6				
PATIENT	160	1.3	0.77	23.4	3.6	3.64	--

INTERPRETED BY

Eric Lindquist, DMV, DABVP (CFM), Cert. IVUSS

IMAGING PERFORMED BY

Rebecca Hamilton

HOSPITAL NAME

Veterinary Wellness Center

REFERRING VET

Dr. Sepulveda

INVOICE

72092

DATE

11/25/25

Cardiac Presentation

The echocardiogram for this patient presented excessive **left atrial size** expressed both in the LA/AO and LA max measurements Chamber volumes and echogenicity were normal. The cranial and caudal **mitral** valve leaflets presented vegetative thickening consistent with endocardiosis. Doppler indicated measurable insufficiency. The **left ventricle** presented thicknesses with linear contour and was not dilated nor restricted. The **myocardium** presented normal echogenicity without subjective evidence of significant fibrotic or ischemic disease. **Contractility** of the ventricular walls was adequate and in normal range for this patient evidenced by the fractional shortening measurement and subjective evaluation of the different regions of the myocardium. The **left ventricular outflow** tract demonstrated normal laminar flow and subjective structural integrity. The **right atrium** and auricle revealed normal size, structure and content. No evidence of masses was noted or chamber overload. **Tricuspid** valvular assessment demonstrated adequate linear morphology. The **right ventricle** was of normal size (1/3 diameter of LV), chordae structure, myocardial echogenicity and thickness. **Pulmonic** tract assessment revealed normal valve structure, laminar flow, and diameter (approx. 1:1 pa/ao ratio). No visible **pericardial** or free pleura fluid was noted. No echographically detectable evidence of infiltrative disease was visible. The cranial **mediastinum and pericardial regions** were free of masses in the visible window.

ULTRASONOGRAPHIC FINDINGS

- Mitral insufficiency and left atrial enlargement.
- B2+ to potentially C1 valvular disease.



PATIENT

Baron McDevitt

SPECIES

Canine

BREED

Bichon Frise x

SEX

Neutered Male

AGE

11 Years

WEIGHT

23.4 lbs

INTERPRETED BY

Eric Lindquist, DMV,
DABVP (CFM), Cert.
IVUSS

IMAGING PERFORMED BY

Rebecca Hamilton

HOSPITAL NAME

Veterinary Wellness
Center

REFERRING VET

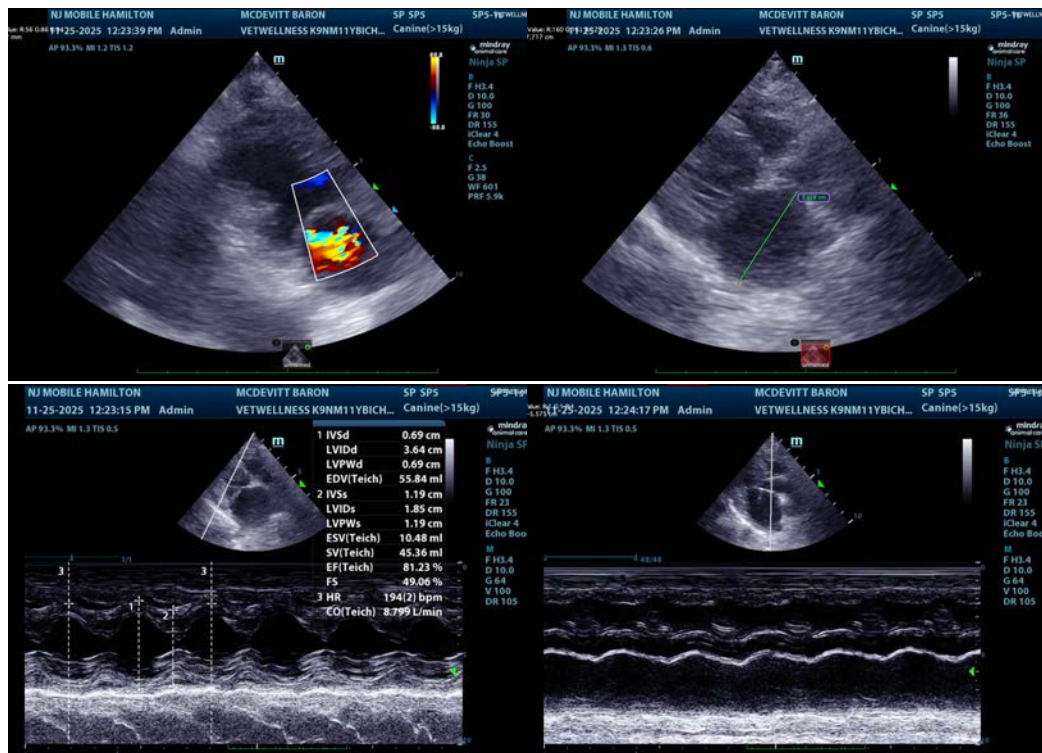
Dr. Sepulveda

INTERPRETATION OF THE FINDINGS & FURTHER RECOMMENDATIONS

The cough is likely cardiogenic in this patient. However, I cannot rule out a concurrent pulmonary pathology. However, regarding the cardiac medications, recommend adding Pimobendan at 0.3 mg/kg BID, ACE inhibitor 0.5 mg/kg SID progressing to BID, and continuing with Lasix as necessary. Both cardiac and respiratory component likely. Bronchodilator and antibiotic protocol would be ideal in this patient as well.

The heart is in a somewhat precarious state with volume overload and a heart that is working to compensate for the valvular insufficiency. Target respiratory rate is < 20 resp/minute after therapy. After initiating therapy, I recommend recheck on the clinical exam, BUN, Creatinine, USG, Chest radiographs & Blood pressure in 5-7 days. Recheck echo in 1 month. Earlier if clinical decompensation is occurring. I do not recommend anesthesia at this time until stabilization has occurred on the recommended medications. Repeat preanesthetic echo is ideal if anesthesia is eventually necessary.

Radiographs: Cardiomegaly and mild hilar edema, chronic bronchial changes.



INVOICE

72092

DATE

11/25/25



PATIENT

Baron McDevitt

SPECIES

Canine

BREED

Bichon Frise x

SEX

Neutered Male

AGE

11 Years

WEIGHT

23.4 lbs

INTERPRETED BY

Eric Lindquist, DMV,
DABVP (CFM), Cert.
IVUSS

IMAGING PERFORMED BY

Rebecca Hamilton

HOSPITAL NAME

Veterinary Wellness
Center

REFERRING VET

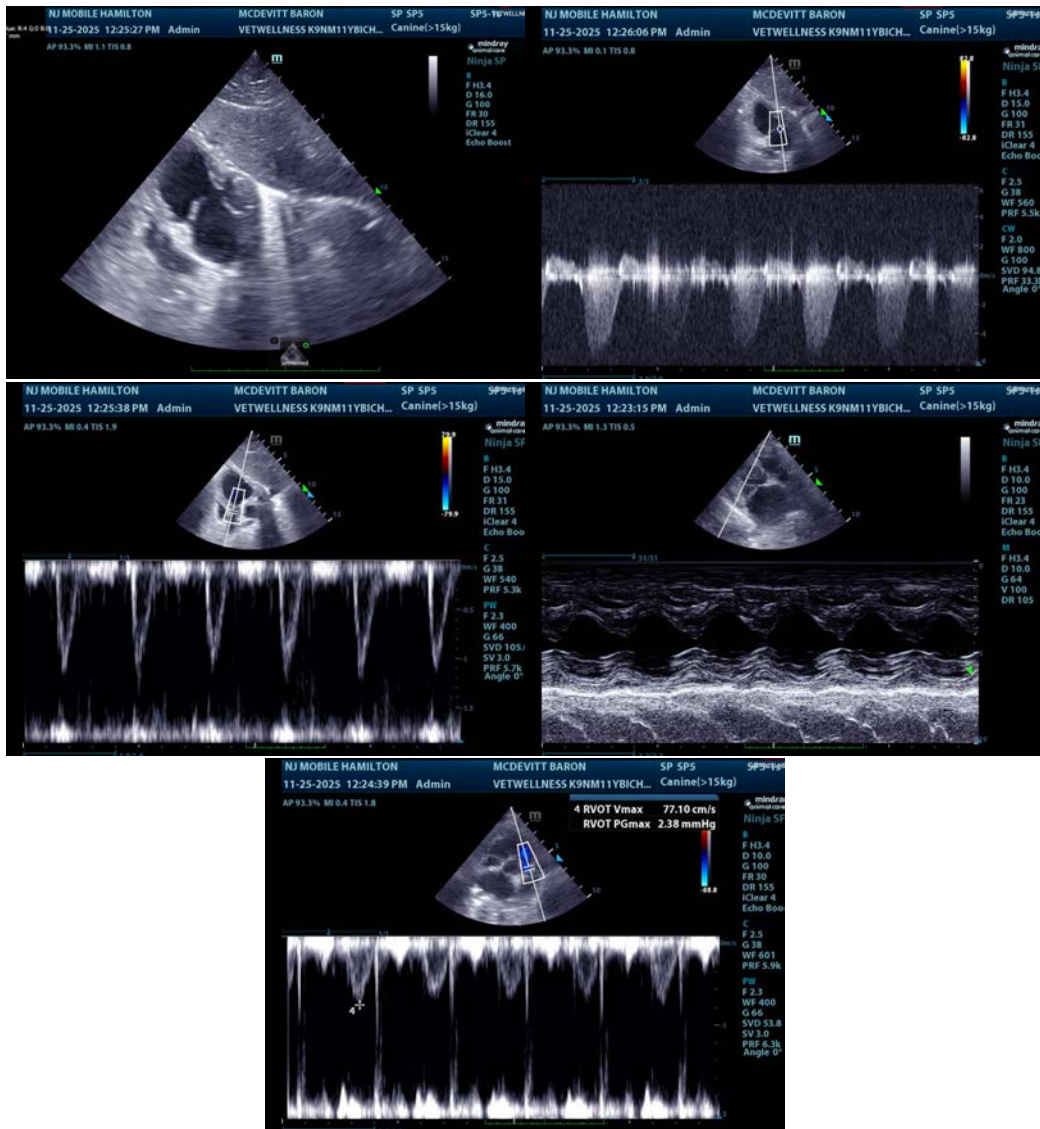
Dr. Sepulveda

INVOICE

72092

DATE

11/25/25



The information and recommendations provided are based on the images presented by the referring veterinarian/sonographer. No evaluation can be communicated regarding pathology that was not visible in the image/video clips provided.

Thank you for this referral. If the clinical or image interpretation does not parallel your findings or if I can be of any further assistance please contact me.

Eric Lindquist, DMV, DABVP(CFM), Cert. IVUSS,
CEO, Owner, Founder -- SonoPath.com
info@SonoPath.com