



**PATIENT**

Diesel Rodriguez

**PRESENTING CLINICAL SIGNS**

Follow-up Echo from 10/25/22

**SPECIES**

Feline

**BREED**

DSH

**SEX**

Neutered Male

**AGE**

13 Years

**WEIGHT**

8 Pounds

**ULTRASONOGRAPHIC EXAMINATION OF THE HEART**

FELINE CARDIAC PARAMETERS	BODY WEIGHT (kg)	HR (BPM)	IVSd (cm)	LVIDd (cm)	LVWd (cm)	FS (%)	EF (%)
NORMAL PARAMETER	-----	150-240	0.3-0.6	1.0-2.1	0.25-0.6	35-67	80-100
PATIENT		NM	--	--	--	--	--
FELINE CARDIAC PARAMETERS	LA/AO (Boon)	LA/AO HEART BASE (Sisson)	LA 2D 4-chamber long axis AS to FW (Sisson) (cm)	LVOT VEL. (m/s)	RVOT VEL. (m/s)	IVRT (m/)	
NORMAL PARAMETER	<1.5	0.88-1.79	0.7-1.7	<1.6	<1.3	40-60	
PATIENT	1.1	1.3	1.3	--	--	NM	

Adapted from June Boon, Veterinary Echocardiography, 1998  
Sisson D et al. JVIM 1991; 5: 232, Jacobs et al. Am J Vet Res 1985; 46:1705

**INTERPRETED BY**

Eric Lindquist, DMV

DABVP, Cert. IVUSS

**IMAGING PERFORMED BY**

Dr. Kristie Steele

**HOSPITAL NAME**

Loving Care VH

**REFERRING VET**

Dr. Kristie Steele

**INVOICE**

42988

**DATE**

11/25/22

**Cardiac Presentation**

The cardiac presentation at this time revealed normal contractility and left atrial size. There is no current evidence of left-sided heart failure. The pleural effusion present is non-cardiogenic at this time. I believe there were two separate scenarios occurring at the prior echocardiogram with evidence of left-sided failure at that time. However, concurrent process of non-cardiogenic pleural effusion is in play. Strong concern for neoplasia in this patient. Pleuritis and FIP less likely.

**ULTRASONOGRAPHIC FINDINGS**

- Stable cardiac presentation and volume
- Non-cardiogenic pleural effusion

**INTERPRETATION OF THE FINDINGS & FURTHER RECOMMENDATIONS**

Pleurocentesis and cytospin recommended with immediate slide preparation to assess for neoplastic cells. Abdominal sonogram warranted to assess for primary disease. The cardiac presentation has improved from the prior sonogram to normal volumes and contractility at this time.



**PATIENT**

Diesel Rodriguez

**SPECIES**

Feline

**BREED**

DSH

**SEX**

Neutered Male

**AGE**

13 Years

**WEIGHT**

8 Pounds

**INTERPRETED BY**

Eric Lindquist, DMV  
DABVP, Cert. IVUSS

**IMAGING PERFORMED BY**

Dr. Kristie Steele

**HOSPITAL NAME**

Loving Care VH

**REFERRING VET**

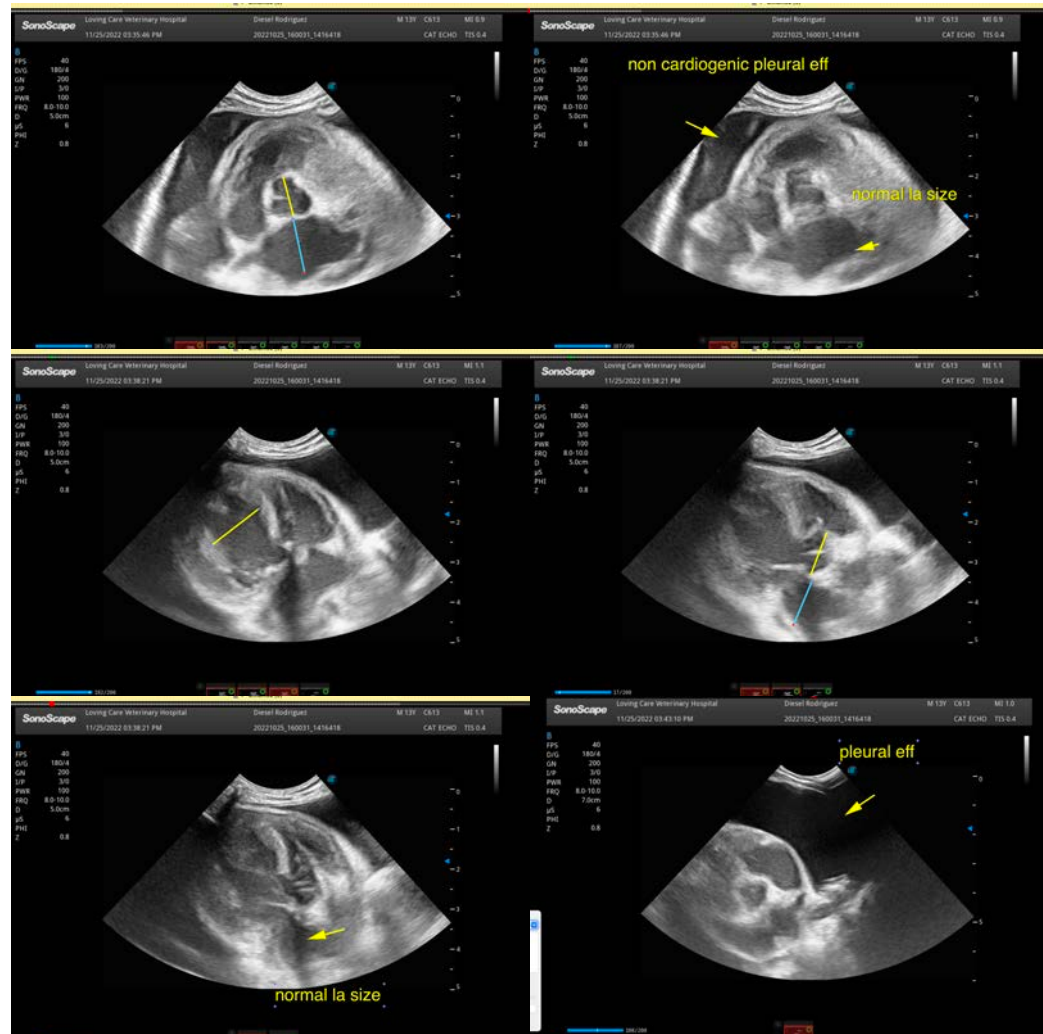
Dr. Kristie Steele

**INVOICE**

42988

**DATE**

11/25/22



The information and recommendations provided are based on the images presented by the referring veterinarian/sonographer. No evaluation can be communicated regarding pathology that was not visible in the image/video clips provided.

Thank you for this referral. If the clinical or image interpretation does not parallel your findings or if I can be of any further assistance please contact me.

**Eric Lindquist, DMV, DABVP, Cert. IVUSS, CEO of SonoPath.com**

[info@SonoPath.com](mailto:info@SonoPath.com)