



PATIENT PRESENTING CLINICAL SIGNS

Thor Nelson

History: Presented on referral yesterday after severe azotemia found at rDVM when presented for weakness and ataxia. Pet was vaccinated 4 days prior. Pet has been Hospitalized and on IV fluids for 24 hours. Indoor only cat - no Lily or Ethylene glycol exposure.

SPECIES

Feline

Abnormal PE/Chem/CBC/UA Results: Prominent hips and spine (poor muscling) otherwise normal exam. No evidence of oliguria. RDVM labs: CBC nsf. HCT 43% Chem = SDMA 97, CREA 7.0, BUN >130, Phos >16.1, K 8.6, Na 145, Cl 104, GGT 3, Chlo 232, T4 0.6, ALb/Glob ratio 0.9 USG 1.026 Lepto snap negative 11/24 at presentation- UA = USG 1.022, pH 6.0, protein 100 mg/dl, Glucosuria, quiet sediment Hospitalized on IV fluids for diuresis 11/25 1am EPOC - HCT 43%, CA 0.96, K+ 4.7 (prev 8.6) CRE 6.16, GLU 176, NA 139, BUN- FAILED BUN SLIDE >130 11/25 1 pm EPOC = bicarb 15.8 mmol/L, iCa 0.87 mmol/l, CREA 5.97 mg/dl, BUN > 130 Na 138 mmol.l, BE - 10.5

BREED

Domestic Shorthair

SEX

Neutered male

ULTRASONOGRAPHIC EXAMINATION OF THE ABDOMEN

Urinary System

AGE

5 months

The **urinary bladder**, trigone, and pelvic urethra presented normal thicknesses and normal tone. The ureters were not visible which is normal. No uroliths or sediment were visualized and anechoic urine was present. No evidence of inflammatory or neoplastic changes was noted. Ureteral papillae were normal.

WEIGHT

4.4 lbs

The **kidneys** were enlarged with increased cortical echogenicity. Corticomedullary definition was maintained. The kidneys revealed slight pyelectasia.

INTERPRETED BY

Eric Lindquist, DMV
DABVP, Cert. IVUSS

ULTRASONOGRAPHIC FINDINGS

Non-specific acute on chronic renal failure.

IMAGING PERFORMED BY

Kalenius

INTERPRETATION OF THE FINDINGS & FURTHER RECOMMENDATIONS

Toxin exposure, infectious agents and dry form FIP are all possible. Renal biopsy would be necessary for further definition.

HOSPITAL NAME

Rockaway AH

REFERRING VET

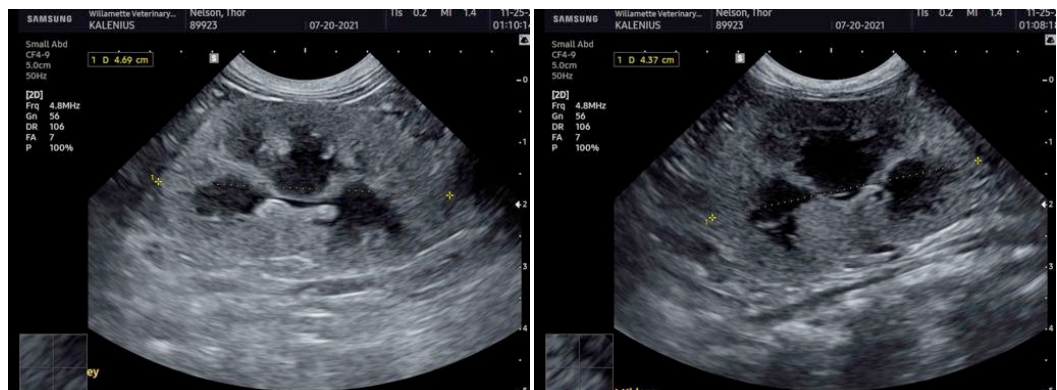
Dr. Kalenius

INVOICE

94112

DATE

11/25/21





PATIENT

Thor Nelson

SPECIES

Feline

BREED

Domestic Shorthair

SEX

Neutered male

AGE

5 months

WEIGHT

4.4 lbs

INTERPRETED BY

Eric Lindquist, DMV
DABVP, Cert. IVUSS

**IMAGING
PERFORMED BY**

Kalenius

HOSPITAL NAME

Rockaway AH

REFERRING VET

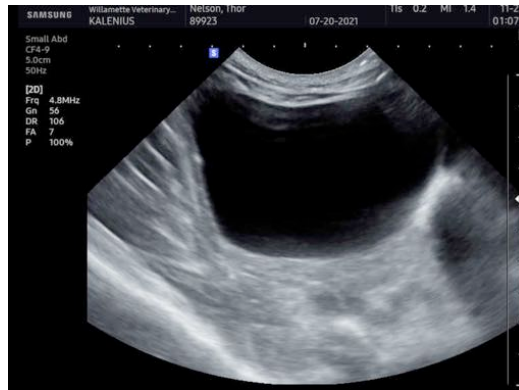
Dr. Kalenius

INVOICE

94112

DATE

11/25/21



The information and recommendations provided are based on the images presented by the referring veterinarian. No evaluation can be communicated regarding pathology that was not visible in the image/video clips provided.

Thank you for this referral. If the clinical or image interpretation does not parallel your findings or if I can be of any further assistance please contact me.

Eric Lindquist, DMV, DABVP, Cert. IVUSS, CEO of SonoPath.com
info@SonoPath.com