



PATIENT

Patty Cake Newbould

SPECIES

Feline

BREED

Domestic Shorthair

SEX

Spayed female

AGE

16 years

WEIGHT

6.7 lbs

INTERPRETED BY

Eric Lindquist, DMV
DABVP, Cert. IVUSS

IMAGING PERFORMED BY

Kevin Moon, DVM

HOSPITAL NAME

Shiloh VH

REFERRING VET

Dr. Moon

INVOICE

68961

DATE

11/24/25

PRESENTING CLINICAL SIGNS

History: BCS 4/9 Chronic weight loss, globulins elevating on labwork P also has chronic sinusitis. U/s performed to r/o abdominal pathology.

11/4/25 Hct 28% Globulin 7.2 g/dL (2.3-5.3) 7/19/25 Globulin 5.9g/dL

ULTRASONOGRAPHIC EXAMINATION OF THE ABDOMEN

Urinary System

The **urinary bladder**, trigone, and pelvic urethra presented normal thicknesses and normal tone. The pelvic urethra was imaged 1.0 cm beyond the cystourethral junction and appeared normal. The ureters were not visible which is normal. No uroliths or sediment were visualized and anechoic urine was present. No evidence of inflammatory or neoplastic changes was noted. Ureteral papillae were normal.

The **kidneys** revealed normal size and structure, corticomedullary definition and ratio for this age. The cortices presented largely uniform texture with normal echogenic relationship to liver and spleen. Medullary structure differed distinctly from the cortex and no evidence of pelvic dilation was present. The capsules were acceptably uniform without significant irregularities. The left kidney measured 3.4 cm. The right kidney measured 3.3 cm.

Adrenal Glands

The regions of the **adrenal glands** were imaged with no gross pathology.

Spleen

The **spleen** presented a smooth homogeneous parenchyma hyperechoic to liver and renal cortical parenchyma. The capsule was smooth without noticeable expansion or deviation from within the spleen or adjacent pathology. The splenic vasculature demonstrated normal volume without signs of congestion or thrombosis. No sonographic evidence of acute or chronic inflammatory, neoplastic, or infarctual changes was noted.

Liver

The **liver** images from right and left intercostal as well as subcostal views revealed subjectively normal liver size, contour, and structure. Some age-related parenchymal remodeling was noted but likely not clinically significant at this time. Vascular and biliary tracts were of normal volume and no evidence of congestion was noted. The gallbladder presented some dependent debris with essentially normal contour. The cystic and common bile ducts were normal. No overt evidence of active inflammatory, infiltrative or regenerative pathology was noted but should be paired with current or past LE elevations regarding any clinical significance to this presentation. The hepatic lymph nodes were unremarkable.



PATIENT

Patty Cake Newbould

SPECIES

Feline

BREED

Domestic Shorthair

SEX

Spayed female

AGE

16 years

WEIGHT

6.7 lbs

INTERPRETED BY

Eric Lindquist, DMV
DABVP, Cert. IVUSS

IMAGING PERFORMED BY

Kevin Moon, DVM

HOSPITAL NAME

Shiloh VH

REFERRING VET

Dr. Moon

INVOICE

68961

DATE

11/24/25

Gastrointestinal

The **gastrointestinal** presentation revealed mild uniform prominence of the gastric mucosa as well as areas of "ropey" small intestinal wall. The muscularis layer was hypertrophied inverting the normal ratio (1:3). The intestinal submucosa was slightly irregular, thickened and hyperechoic suggestive of low grade, chronic inflammation. No evidence of obstruction was present. Reactive mesenteric lymph nodes and measured 0.9 cm. Chronic inflammatory bowel disease is probable with a low possibility of an early neoplastic event such as lymphoma or, less likely, dry form FIP can at times be found on biopsy of these presentations. Full thickness tissue biopsies via open laparotomy, ideally guided by intraoperative ultrasound in order to obtain the most representative mural sample, would be necessary to rule more significant disease than IBD.

Pancreas

The base and limbs of the **pancreas** were observed to be largely isoechoic to surrounding omental fat. Pancreatic duct and capsular contour were acceptably normal and parenchyma respected normal curvilinear patterns. No overt evidence of active inflammatory or neoplastic disease was noted.

ULTRASONOGRAPHIC FINDINGS

Diffuse intestinal thickening. Consistent with latent, inflammatory bowel, cannot rule out a pre-neoplastic state.

Reactive mesenteric lymph nodes.

Otherwise, age related abdominal changes.

INTERPRETATION OF THE FINDINGS & FURTHER RECOMMENDATIONS

Full thickness intestinal biopsies would be necessary for further definition. Fecal test, protein electrophoresis and internal med consult is recommended.

Maldigestion panel, three view chest radiographs and full CNS examination is recommended to examine for occult disease that could be responsible for the weight loss. Evaluation for competitive eating environments should also be considered.



PATIENT

Patty Cake Newbould

SPECIES

Feline

BREED

Domestic Shorthair

SEX

Spayed female

AGE

16 years

WEIGHT

6.7 lbs

INTERPRETED BY

Eric Lindquist, DMV
DABVP, Cert. IVUSS

IMAGING PERFORMED BY

Kevin Moon, DVM

HOSPITAL NAME

Shiloh VH

REFERRING VET

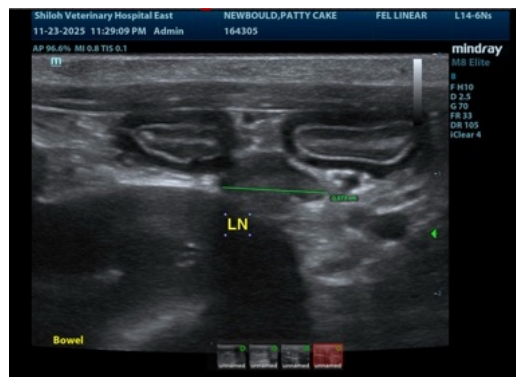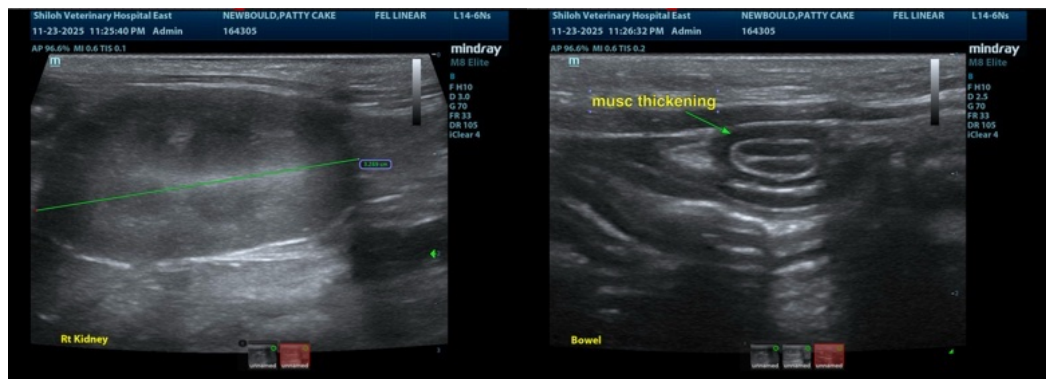
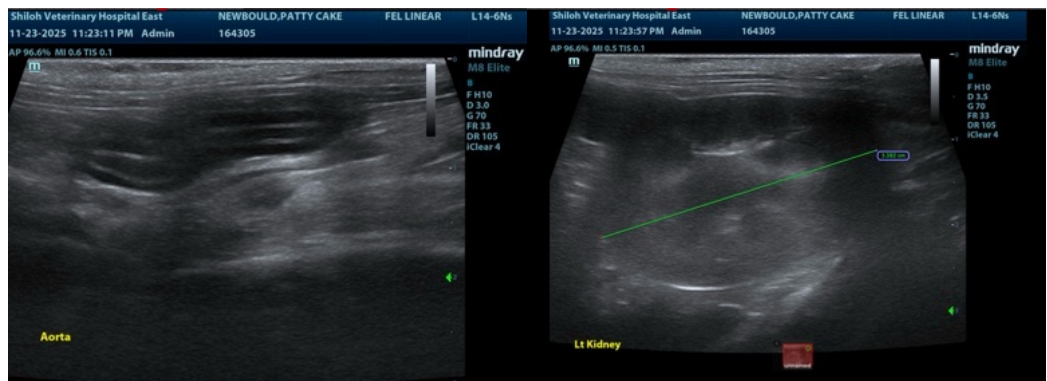
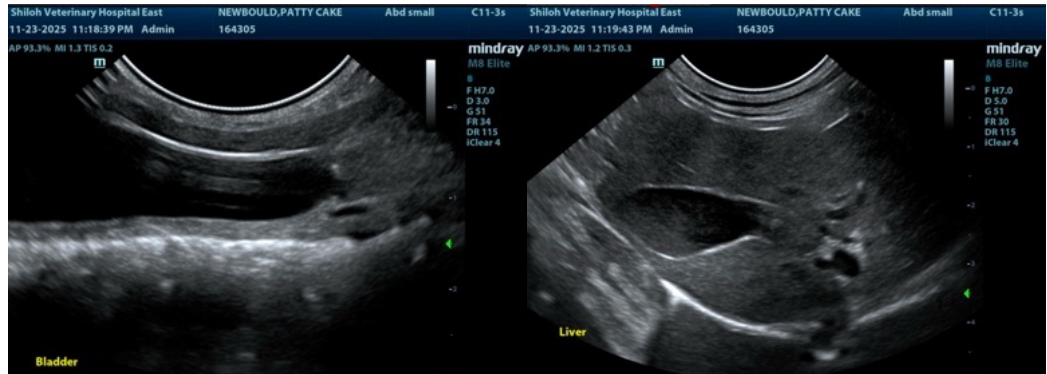
Dr. Moon

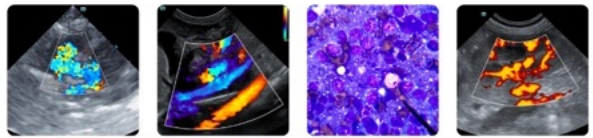
INVOICE

68961

DATE

11/24/25





PATIENT

Patty Cake Newbould

SPECIES

Feline

BREED

Domestic Shorthair

SEX

Spayed female

AGE

16 years

WEIGHT

6.7 lbs

INTERPRETED BY

Eric Lindquist, DMV
DABVP, Cert. IVUSS

IMAGING PERFORMED BY

Kevin Moon, DVM

HOSPITAL NAME

Shiloh VH

REFERRING VET

Dr. Moon

INVOICE

68961

DATE

11/24/25

The information and recommendations provided are based on the images presented by the referring veterinarian/sonographer. No evaluation can be communicated regarding pathology that was not visible in the image/video clips provided.

Thank you for this referral. If the clinical or image interpretation does not parallel your findings or if I can be of any further assistance please contact me.

Eric Lindquist, DMV, DABVP (CFM), Cert. IVUSS, CEO of SonoPath.com

info@SonoPath.com