



## PATIENT

Bubba Hodgkins

## SPECIES

Canine

## BREED

Chihuahua Mix

## SEX

Male

## AGE

8 years

## WEIGHT

17.4 lbs

## PRESENTING CLINICAL SIGNS

History: Acute inappetence, followed by diarrhea. Diarrhea started w/ no blood in stool, then O noted frank blood for a bit, and now no blood in stool. Possible 1 episode of V phlegm-like material. No lethargy.  
Prolonged skin tent. Otherwise NSF on PE, unremarkable CBC/ Chem17 + llytes.

## ULTRASONOGRAPHIC EXAMINATION OF THE ABDOMEN

### *Urinary System*

The **urinary bladder**, trigone, and pelvic urethra presented normal thicknesses and normal tone. The ureters were not visible which is normal. No uroliths or sediment were visualized and anechoic urine was present. No evidence of inflammatory or neoplastic changes was noted. Ureteral papillae were normal.

The **kidneys** revealed normal size and structure, corticomedullary definition and ratio for this age. The cortices presented largely uniform texture with normal echogenic relationship to liver and spleen. Medullary structure differed distinctly from the cortex and no evidence of pelvic dilation was present. The capsules were acceptably uniform without significant irregularities. The right kidney measured 3.82 cm.

## INTERPRETED BY

Eric Lindquist, DMV  
DABVP, Cert. IVUSS

### *Adrenal Glands*

The **adrenal glands** were not visualized.

## IMAGING PERFORMED BY

Dr. Levy

### *Spleen*

The **spleen** presented a smooth homogeneous parenchyma hyperechoic to liver and renal cortical parenchyma. The capsule was smooth without noticeable expansion or deviation from within the spleen or adjacent pathology. The splenic vasculature demonstrated normal volume without signs of congestion or thrombosis. No sonographic evidence of acute or chronic inflammatory, neoplastic, or infarctual changes was noted.

## HOSPITAL NAME

Court Street VH

## REFERRING VET

Dr. Levy

### *Liver*

The **liver** images submitted revealed subjectively normal liver size, contour, and structure. Parenchymal echogenicity was naturally coarse and hypoechoic to the spleen. Vascular and biliary tracts were of normal volume with no evidence of congestion. The gallbladder presented acceptably thin walls with primarily anechoic content. The cystic and common bile ducts were normal. No pathological hepatic lymphadenopathy was evident. No overt structural evidence of inflammatory, infiltrative or regenerative pathology was evident.

## INVOICE

68963

## DATE

11/24/25



## PATIENT

Bubba Hodgkins

## SPECIES

Canine

## BREED

Chihuahua Mix

## SEX

Male

## AGE

8 years

## WEIGHT

17.4 lbs

## INTERPRETED BY

Eric Lindquist, DMV  
DABVP, Cert. IVUSS

## IMAGING PERFORMED BY

Dr. Levy

## HOSPITAL NAME

Court Street VH

## REFERRING VET

Dr. Levy

## INVOICE

68963

## DATE

11/24/25

## Gastrointestinal

Examination of the **gastrointestinal tract** revealed a stomach and intestine free of stasis, of normal wall thickness, acceptable curvilinear mural detail, and peristaltic activity. Small and large intestine demonstrated normal luminal chyme and stool consistency respectively. No obstructive or overt infiltrative disease was noted. No associated abnormal lymphatic activity was noted.

## Pancreas

The **pancreas** revealed a minor amount of remodeling noted.

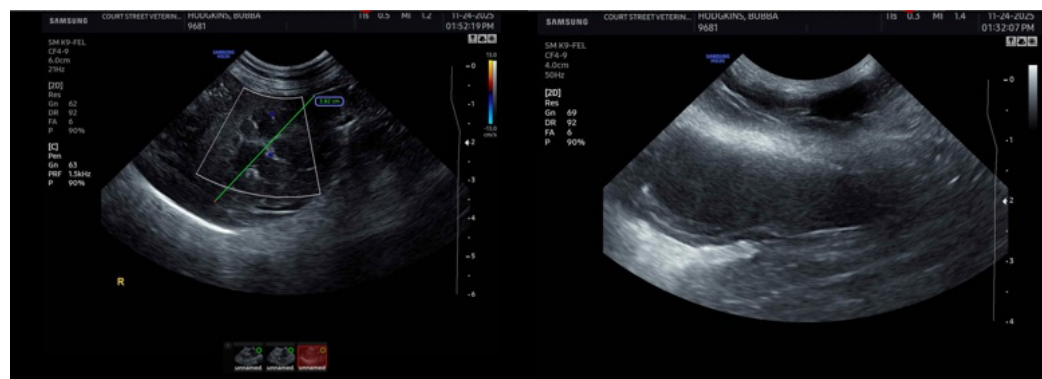
## ULTRASONOGRAPHIC FINDINGS

Structurally unremarkable abdomen.

## INTERPRETATION OF THE FINDINGS & FURTHER RECOMMENDATIONS

There was no evidence of gross pathology. Screening for occult Addison's is indicated if not already performed.

Differentials for diarrhea include occult parasitism. Dietary indiscretion, dietary intolerance, antibiotic responsive colitis, intestinal dysbiosis and occult Addison's should all be considered as causes of diarrhea in this patient. A hydrolyzed diet trial may be in this patient's best interest +/- probiotics. 24-hour NPO and reintroduction of bland diet indicated. I recommend a baseline cortisol or ACTH stimulation test, a fresh fecal smear and fecal floatation analysis if not already performed





## PATIENT

Bubba Hodgkins

## SPECIES

Canine

## BREED

Chihuahua Mix

## SEX

Male

## AGE

8 years

## WEIGHT

17.4 lbs

## INTERPRETED BY

Eric Lindquist, DMV  
DABVP, Cert. IVUSS

## IMAGING PERFORMED BY

Dr. Levy

## HOSPITAL NAME

Court Street VH

## REFERRING VET

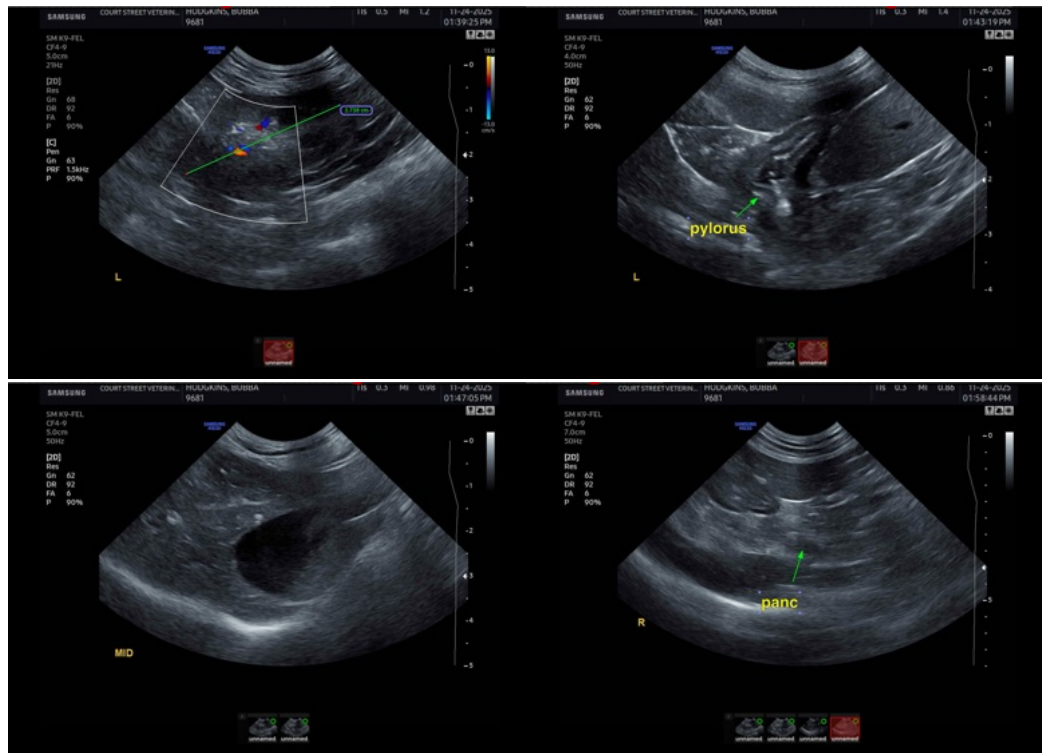
Dr. Levy

## INVOICE

68963

## DATE

11/24/25



The information and recommendations provided are based on the images presented by the referring veterinarian/sonographer. No evaluation can be communicated regarding pathology that was not visible in the image/video clips provided.

Thank you for this referral. If the clinical or image interpretation does not parallel your findings or if I can be of any further assistance please contact me.

Eric Lindquist, DMV, DABVP (CFM), Cert. IVUSS, CEO of SonoPath.com

[info@SonoPath.com](mailto:info@SonoPath.com)