



PATIENT

Bentley Jericho

SPECIES

Canine

BREED

Cavalier King Charles
Spaniel

SEX

Neutered male

AGE

10 years

WEIGHT

23.1 lbs

INTERPRETED BY

Eric Lindquist, DMV
DABVP, Cert. IVUSS

IMAGING PERFORMED BY

Dr. Peter Neslon

HOSPITAL NAME

Valley Veterinary
Service

REFERRING VET

Dr. Bartus

INVOICE

68939

DATE

11/24/25

PRESENTING CLINICAL SIGNS

History: Presented for annual wellness on 10/27. Historic heart murmur. Taking Enalapril 5mg SID and Pimobendan 2.5mg SID. Grade III heart murmur auscultated. Needs dental prophylaxis. Echo prior to anesthesia.

ULTRASONOGRAPHIC EXAMINATION OF THE HEART

The cardiac presentation in this patient presented persistent mitral and tricuspid insufficiency with persistent volume overload in the left atrium and left ventricle, yet some improvement has occurred. Prolapse of the anterior mitral valve leaflet was noted. Contractility was adequate. There was no evidence of right-sided overload noted. The hepatic veins were not dilated. There was no pericardial or pleural effusion noted.

CANINE CARDIAC PARAMETERS	MR VMAX (m/s)	TR VMAX (m/s)	LA/AO	LA/AO (Heart Base)	FS (%)	EF (%)	EPSS (cm)
NORMAL PARAMETER	4.5-5.5	<2.7	1.3	<1.6	28-40	40-100	<0.6
PATIENT	6.0		1.6	1.54	48	80	NM
CANINE CARDIAC PARAMETERS	HR (BPM)	AV VMAX (m/s)	PV MAX (m/s)	BODY WEIGHT (kg)	LA 2D short axis Base view (cm)	LVIDd Avg; 2D and m-mode short axis (cm)	LVIDs Avg; 2D and m-mode short axis (cm)
NORMAL PARAMETER	50-100	0.7-1.7	0.7-1.6	BELOW	BELOW	BELOW	BELOW
PATIENT				23.1 lbs	4.3	3.84	

ULTRASONOGRAPHIC FINDINGS

Partially compensated valvular disease with persistent volume overload of the left atrium and left ventricle.

B2-B2+ valvular disease.

INTERPRETATION OF THE FINDINGS & FURTHER RECOMMENDATIONS

I recommend adding to the current protocol Spironolactone at 1-2 mg/kg s.i.d. and increasing Enalapril to b.i.d. dosing with monitoring of BUN and creatinine and blood pressure measurements. A recheck echocardiogram is recommended in 3-6 months.



PATIENT

Bentley Jericho

SPECIES

Canine

BREED

Cavalier King Charles
Spaniel

SEX

Neutered male

AGE

10 years

WEIGHT

23.1 lbs

INTERPRETED BY

Eric Lindquist, DMV
DABVP, Cert. IVUSS

IMAGING PERFORMED BY

Dr. Peter Neslon

HOSPITAL NAME

Valley Veterinary
Service

REFERRING VET

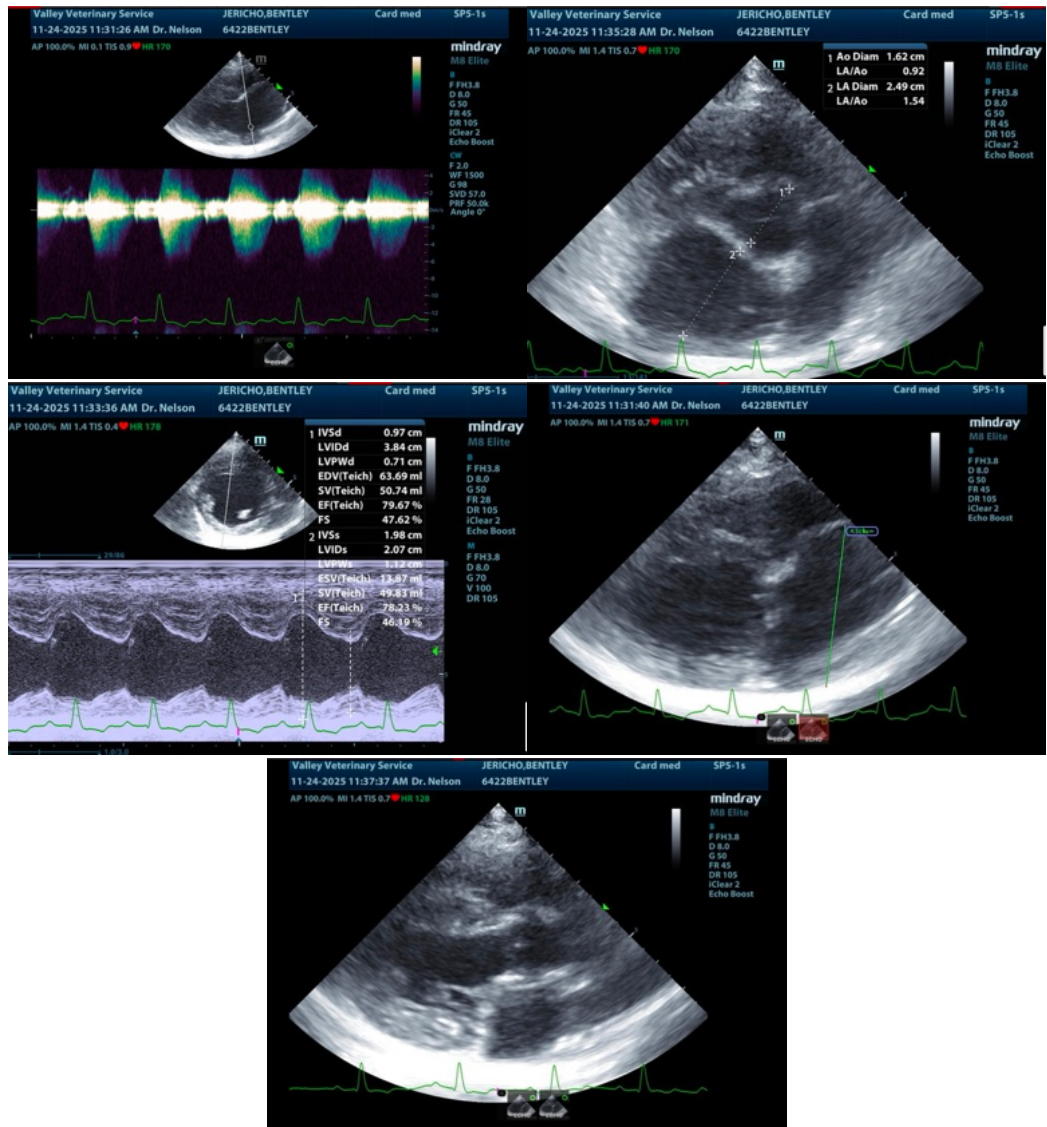
Dr. Bartus

INVOICE

68939

DATE

11/24/25



The information and recommendations provided are based on the images presented by the referring veterinarian/sonographer. No evaluation can be communicated regarding pathology that was not visible in the image/video clips provided.

Thank you for this referral. If the clinical or image interpretation does not parallel your findings or if I can be of any further assistance please contact me.

Eric Lindquist, DMV, DABVP (CFM), Cert. IVUSS, CEO of SonoPath.com

info@SonoPath.com