



PATIENT PRESENTING CLINICAL SIGNS

Jasper Charlie

History: Grade 3 holosystolic murmur with pmi on left side , non symptomatic needs dental

SPECIES

Canine

ULTRASONOGRAPHIC EXAMINATION OF THE HEART

BREED

Jack Russell Terrier

The echocardiogram in this patient demonstrated normal **left atrial** size based on 3 separate methods of LA evaluation. Slight prolapse of the anterior **mitral** valve leaflet was noted. The **left ventricle** presented normal thicknesses with linear contour and was not dilated nor restricted. The **myocardium** presented normal echogenicity without subjective evidence of significant fibrotic or ischemic disease. **Contractility** of the ventricular walls was adequate and in normal range for this patient evidenced by the fractional shortening measurement and subjective evaluation of the different regions of the myocardium. The **left ventricular outflow** tract demonstrated normal laminar flow and subjective structural integrity. The **right atrium** and auricle revealed normal size, structure and content. No evidence of masses was noted. **Tricuspid** valvular assessment demonstrated adequate linear morphology and kinesis. The **right ventricle** was of normal size (1/3 diameter of LV), chordae structure, myocardial echogenicity and thickness. **Pulmonary outflow** tract assessment revealed normal valve structure, laminar flow, and diameter (approx.1:1 pa/ao ratio). No visible **pericardial** or free pleura fluid was noted. The cranial **mediastinum and pericardial and extra-cardiac regions** were free of masses in the visible window.

SEX

Neutered male

AGE

9 years

WEIGHT

6.6 lbs

INTERPRETED BY

Eric Lindquist, DMV
DABVP, Cert. IVUSS

| CANINE CARDIAC PARAMETERS | MR VMAX (m/s) | TR VMAX (m/s) | LA/AO (Boon method) | LA/AO (Heart Base; Swe) | FS (%) | EF (%) | EPSS (cm) |
|---------------------------------|---------------------|---------------------|------------------------|-------------------------------|--|--|--|
| NORMAL PARAMETER | 4.5-5.5 | <2.7 | 1.3 | <1.6 | 28-40 | 40-100 | <0.6 |
| PATIENT | | | 1.3 | | 45 | | 0.1 |
| CANINE CARDIAC PARAMETERS | HR (BPM) | AV VMAX (m/s) | PV MAX (m/s) | BODY WEIGHT | LA 2D short axis Base view (cm) | LVIDd Avg; 2D and m- mode short axis (cm) | LVIDs Avg; 2D and m-mode short axis (cm) |
| NORMAL PARAMETER | 50-100 | 0.7-1.7 | 0.7-1.6 | BELOW | BELOW | BELOW | BELOW |
| PATIENT | | | | 6.6 lbs | 2.5 | 3.6 | |

IMAGING PERFORMED BY

Dr. Fresta

HOSPITAL NAME

The Veterinary Surgery

REFERRING VET

Dr. Fresta

ULTRASONOGRAPHIC FINDINGS

Mitral insufficiency. Stage B1 valvular disease. No evidence of volume overload.

INVOICE

42698

INTERPRETATION OF THE FINDINGS & FURTHER RECOMMENDATIONS

DATE

11/24/22

The heart is stable without clinical disease. No overt contraindication for anesthesia of brief to moderate duration. I suggest Torbutrol premed, Propofol induction, Isoflo maintenance or similar protocol if anesthesia is desired. Blood pressure recommended if not already performed and target



PATIENT

Jasper Charlie

white coat negative systolic pressure of < 160 mmHg. If higher than this ACE-inhibitor is suggested to reach this level. Recheck echocardiogram is recommended in 6 months, earlier if murmur grade increases or clinical signs initiate.

SPECIES

Canine

BREED

Jack Russell Terrier

SEX

Neutered male

AGE

9 years

WEIGHT

6.6 lbs

INTERPRETED BY

Eric Lindquist, DMV
DABVP, Cert. IVUSS

IMAGING PERFORMED BY

Dr. Fresta

HOSPITAL NAME

The Veterinary Surgery

REFERRING VET

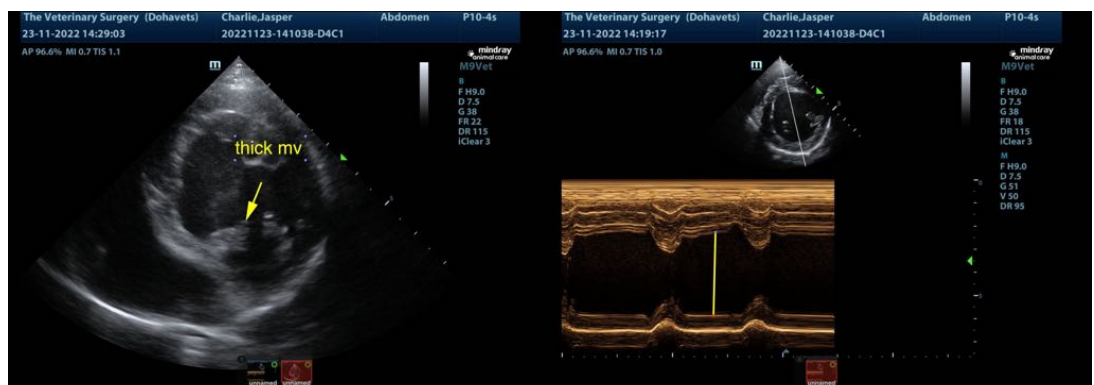
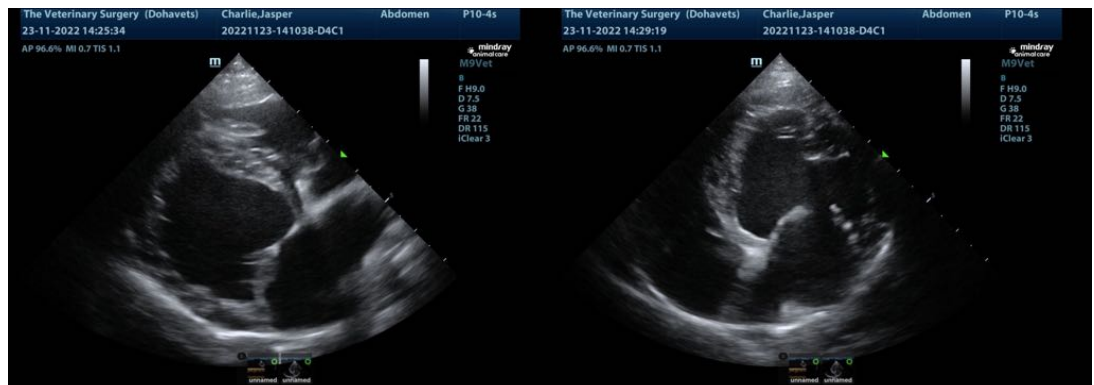
Dr. Fresta

INVOICE

42698

DATE

11/24/22





PATIENT

Jasper Charlie

SPECIES

Canine

BREED

Jack Russell Terrier

SEX

Neutered male

AGE

9 years

WEIGHT

6.6 lbs

INTERPRETED BY

Eric Lindquist, DMV
DABVP, Cert. IVUSS

**IMAGING
PERFORMED BY**

Dr. Fresta

HOSPITAL NAME

The Veterinary Surgery

REFERRING VET

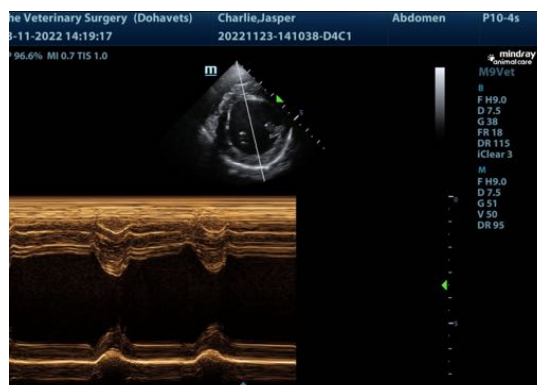
Dr. Fresta

INVOICE

42698

DATE

11/24/22



The information and recommendations provided are based on the images presented by the referring veterinarian/sonographer. No evaluation can be communicated regarding pathology that was not visible in the image/video clips provided.

Thank you for this referral. If the clinical or image interpretation does not parallel your findings or if I can be of any further assistance please contact me.

Eric Lindquist, DMV, DABVP, Cert. IVUSS, CEO of SonoPath.com
info@SonoPath.com