



PATIENT PRESENTING CLINICAL SIGNS

Zoe Bower Grade 3/5 murmur. Echo prior to surgery
Abnormal PE/Chem/CBC/UA Results: BP 174/81(115), 162/113(131), 174/82(134) Blood norm

SPECIES ULTRASONOGRAPHIC EXAMINATION OF THE HEART

Canine

BREED

Boxer

SEX

Spayed Female

AGE

6 Years

WEIGHT

79 Pounds

| CANINE CARDIAC PARAMETERS | MR VMAX (m/s) | TR VMAX (m/s) | LA/AO (Boon method) | LA/AO (Heart Base; Swe) | FS (%) | EF (%) | EPSS (cm) |
|---------------------------|---------------|---------------|---------------------|-------------------------|---------------------------------|--|--|
| NORMAL PARAMETER | 4.5-5.5 | <2.7 | 1.3 | <1.6 | 28-40 | 40-100 | <0.6 |
| PATIENT | | | 1.3 | 1.5 | 53 | 81 | NM |
| CANINE CARDIAC PARAMETERS | HR (BPM) | AV VMAX (m/s) | PV MAX (m/s) | BODY WEIGHT (kg) | LA 2D short axis Base view (cm) | LVIDd Avg; 2D and m-mode short axis (cm) | LVIDs Avg; 2D and m-mode short axis (cm) |
| NORMAL PARAMETER | 50-100 | 0.7-1.7 | 0.7-1.6 | BELOW | BELOW | BELOW | BELOW |
| PATIENT | 141 | 2.4 | 1.5 | | 3.7 | 3.43 | |

Cardiac Presentation

The echocardiogram in this patient demonstrated normal **left atrial** size based on 3 separate methods of LA evaluation. The cranial and caudal **mitral** valve leaflets presented normal linear structure, extension in systole, and union in diastole with normal kinesis. The **left ventricle** presented thicknesses with linear contour and was not dilated nor restricted. The **myocardium** presented normal echogenicity without subjective evidence of significant fibrotic or ischemic disease. **Contractility** of the ventricular walls was adequate and in normal range for this patient evidenced by the fractional shortening measurement and subjective evaluation of the different regions of the myocardium. **Aortic** velocity slightly elevated. The **right atrium** and auricle revealed normal size, structure and content. No evidence of masses was noted. **Tricuspid** valvular assessment demonstrated adequate linear morphology and kinesis. The **right ventricle** was of normal size (1/3 diameter of LV), chordae structure, myocardial echogenicity and thickness. **Pulmonary outflow** tract assessment revealed normal valve structure, laminar flow, and diameter (approx. 1:1 pa/ao ratio). No visible **pericardial** or free pleura fluid was noted. The cranial **mediastinum** and **pericardial** and **extra-cardiac** regions were free of masses in the visible window.

INTERPRETED BY

Eric Lindquist, DMV

DABVP, Cert. IVUSS

IMAGING PERFORMED BY

JK

HOSPITAL NAME

Hamburg Vet Clinic

REFERRING VET

Dr. Martens

ULTRASONOGRAPHIC FINDINGS

- Idiopathic increased LVOT velocity

INTERPRETATION OF THE FINDINGS & FURTHER RECOMMENDATIONS

INVOICE

42973

DATE

11/23/22

No overt contraindication to anesthetic procedure. However, given the elevated systolic pressures, recommend reassessing the blood pressures 30 minutes after Torbutrol administration in a white coat negative environment to ensure this is not excitement versus true hypertension.



PATIENT

Zoe Bower

SPECIES

Canine

BREED

Boxer

SEX

Spayed Female

AGE

6 Years

WEIGHT

79 Pounds

INTERPRETED BY

Eric Lindquist, DMV

DABVP, Cert. IVUSS

IMAGING PERFORMED BY

JK

HOSPITAL NAME

Hamburg Vet Clinic

REFERRING VET

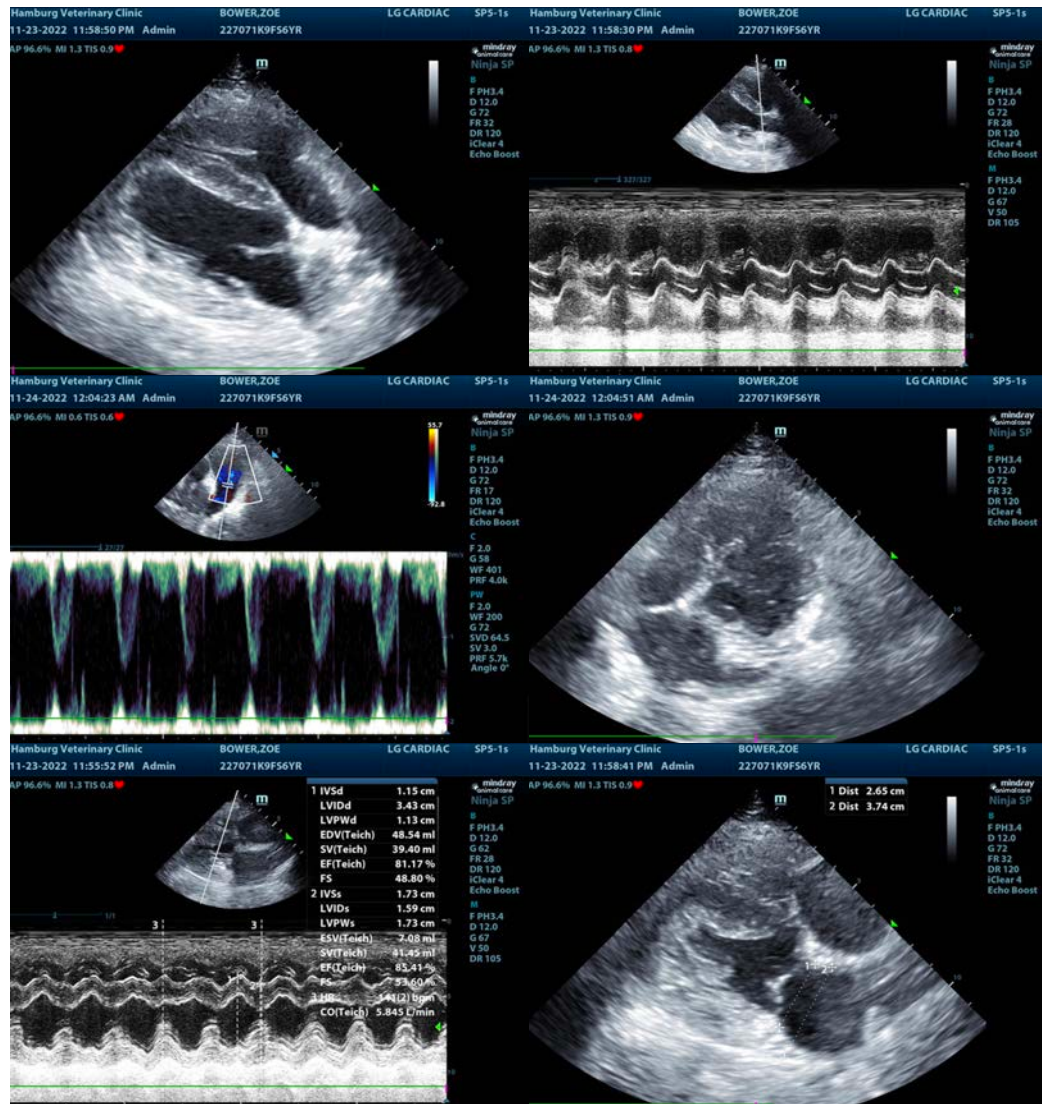
Dr. Martens

INVOICE

42973

DATE

11/23/22



The information and recommendations provided are based on the images presented by the referring veterinarian/sonographer. No evaluation can be communicated regarding pathology that was not visible in the image/video clips provided.

Thank you for this referral. If the clinical or image interpretation does not parallel your findings or if I can be of any further assistance please contact me.

Eric Lindquist, DMV, DABVP, Cert. IVUSS, CEO of SonoPath.com

info@SonoPath.com