



PATIENT

Tenacee Pugsley

SPECIES

Canine

BREED

Australian Cattle Dog

SEX

Neutered Male

AGE

14 Years

WEIGHT

51 Pounds

INTERPRETED BY

Eric Lindquist, DMV

DABVP, Cert. IVUSS

IMAGING PERFORMED BY

Dr. John Ammeraal

HOSPITAL NAME

Sova Animal Hospital

REFERRING VET

Dr. John Ammeraal

INVOICE

42967

DATE

11/23/22

PRESENTING CLINICAL SIGNS

Presented last week for weakness, seemed disoriented, vomited a couple times day before that, treated with SQ fluids, cerenia and Pepcid, Seemed to do much better afterwards.

Abnormal PE/Chem/CBC/UA Results: General exam, few lipomas and Grade 3 dental disease, Chem 27 ALT 156 U/L ALKP 150 U/L, Amylase 10,935u/L Precision PSL 7458 U/L, Neutrophils 11,934 /uL

ULTRASONOGRAPHIC EXAMINATION OF THE ABDOMEN

Urinary System

The **urinary bladder**, trigone, and pelvic urethra presented normal thicknesses and normal tone. The ureters were not visible which is normal. No uroliths or sediment were visualized and anechoic urine was present. No evidence of inflammatory or neoplastic changes were noted. Ureteral papillae were normal. The pelvic urethra was imaged 2.0 cm beyond the cystourethral junction.

The **kidneys** revealed largely normal size and structure, corticomedullary definition and ratio (cortex 1/3 of medulla) were essentially maintained with some age-related loss of curvilinear patterns regarding the capsule and C/M junction. The cortices presented largely uniform texture with some increased echogenicity expected for his age patient. Medullary structure differed distinctly from that of the cortex and no evidence of pelvic dilation was present. The left kidney measured 6.4 cm. The right kidney measured 6.83 cm.

Adrenal Glands

Both **adrenal glands** were visualized and recognized as having normal shape, size, position and echogenicity for this breed. The phrenic vasculature, glandular echogenicity and detail were unremarkable. Capsule, cortex, and medullary definition were normal for this age patient. The left adrenal gland measured 0.72 cm at the caudal pole and 0.76 cm at the cranial pole. The right adrenal gland measured 2.34 cm x 0.87 cm at the cranial pole and 0.74 cm at the caudal pole.

Spleen

The **spleen** presented a smooth homogeneous parenchyma hyperechoic to liver and renal cortical parenchyma. The capsule was smooth without noticeable expansion or deviation from within the spleen or adjacent pathology. The splenic vasculature demonstrated normal volume without signs of congestion or thrombosis. No sonographic evidence of acute or chronic inflammatory, neoplastic, or infarctual changes were noted.

Liver

The **liver** images from right and left intercostal as well as subcostal views revealed subjectively normal liver size, contour, and structure. Some age-related parenchymal remodeling was noted but likely not clinically significant at this time. Vascular and biliary tracts were of normal volume and no evidence of congestion was noted. The gallbladder presented some dependent debris with essentially normal contour. The cystic and common bile ducts were normal. No overt evidence of active inflammatory, infiltrative or regenerative pathology was noted but should be paired with current or past LE elevations regarding any clinical significance to this presentation. The hepatic lymph nodes were unremarkable.

Gastrointestinal

The **gastrointestinal tract** was structurally unremarkable. However, excessive GI gas was present. Some level of GI inflammation suspected.



PATIENT

Pancreas

Tenacee Pugsley

The **pancreas** presented mild hypoechoic undulating contour in the right limb. Subxiphoid palpation is recommended to assess for pain or discomfort associated with the pancreas.

SPECIES

Canine

ULTRASONOGRAPHIC FINDINGS

- Non-specific excessive GI gas
- Irregular right limb of the pancreas
- Age related renal changes
- Age related hepatic changes

BREED

Australian Cattle Dog

INTERPRETATION OF THE FINDINGS & FURTHER RECOMMENDATIONS

SEX

Neutered Male

Full CNS examination warranted. If any CNS defects are noted, then skull CT would be indicated. Diet change to hydrolyzed geriatric diet may be in this patient's best interest. Fecal test and antiparasitic protocol indicated. Structurally the abdomen appears benign other than excessive GI gas and possible low-grade right limb pancreatitis.

AGE

14 Years

SonoPath CT Services are offered at the SonoPath Imaging and Veterinary Education Center, 141 Main St (rt 206), Andover, New Jersey, a 20-minute drive west on route 80/206 North from the route 80/287 interchange/Parsippany, New Jersey. More information can be found at <https://sonopath.com/services/sonopath-ct-services>

WEIGHT

51 Pounds

INTERPRETED BY

Eric Lindquist, DMV
DABVP, Cert. IVUSS

IMAGING PERFORMED BY

Dr. John Ammeraal

HOSPITAL NAME

Sova Animal Hospital

REFERRING VET

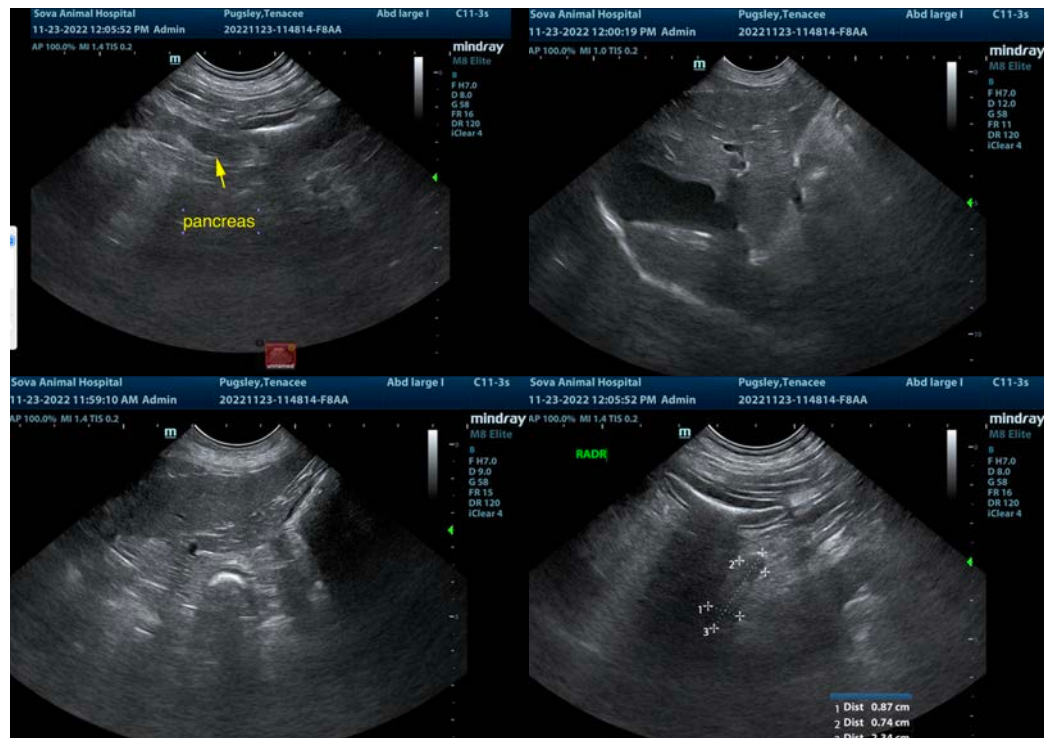
Dr. John Ammeraal

INVOICE

42967

DATE

11/23/22





PATIENT

Tenacee Pugsley

SPECIES

Canine

BREED

Australian Cattle Dog

SEX

Neutered Male

AGE

14 Years

WEIGHT

51 Pounds

INTERPRETED BY

Eric Lindquist, DMV
DABVP, Cert. IVUSS

IMAGING PERFORMED BY

Dr. John Ammeraal

HOSPITAL NAME

Sova Animal Hospital

REFERRING VET

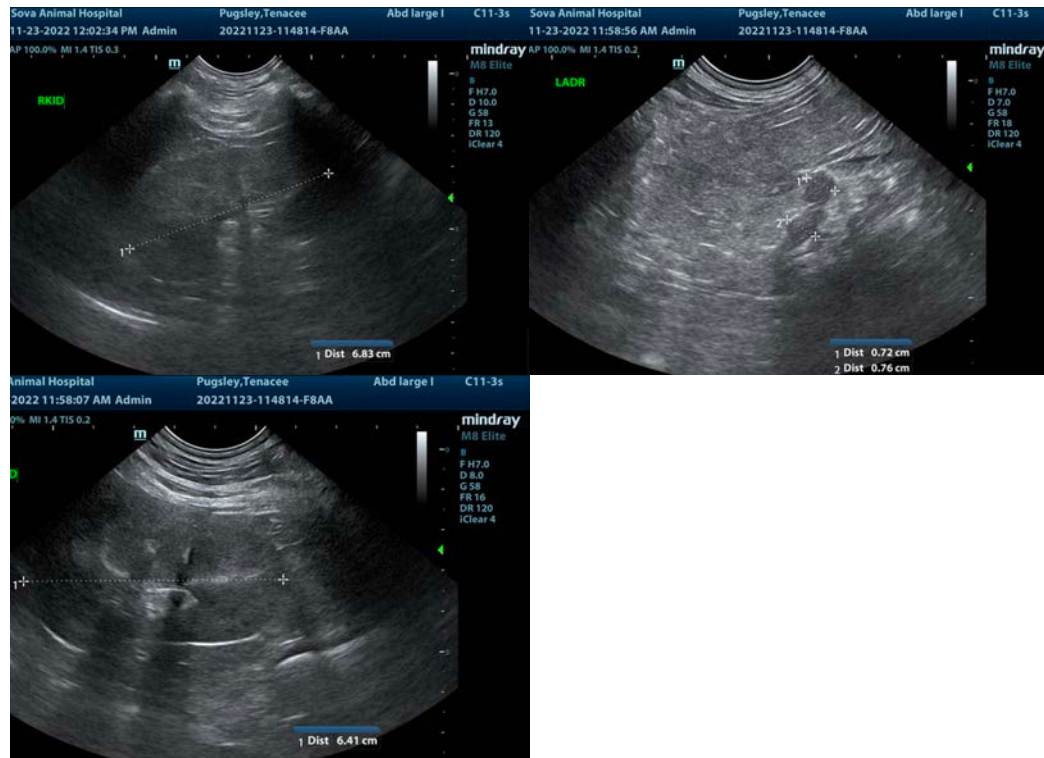
Dr. John Ammeraal

INVOICE

42967

DATE

11/23/22



The information and recommendations provided are based on the images presented by the referring veterinarian/sonographer. No evaluation can be communicated regarding pathology that was not visible in the image/video clips provided.

Thank you for this referral. If the clinical or image interpretation does not parallel your findings or if I can be of any further assistance please contact me.

Eric Lindquist, DMV, DABVP, Cert. IVUSS, CEO of SonoPath.com

info@SonoPath.com