



PATIENT

Skippy Jon Holton
Anglin

SPECIES

Feline

BREED

Siamese

SEX

Neutered male

AGE

9 years

WEIGHT

10.5 lbs

INTERPRETED BY

Eric Lindquist, DMV
DABVP, Cert. IVUSS

IMAGING PERFORMED BY

Dr. Reese

HOSPITAL NAME

Willow Run VC

REFERRING VET

Dr. Reese

INVOICE

42697

DATE

11/23/22

PRESENTING CLINICAL SIGNS

History: P presented for wellness exam last week. Had been doing well at home according to owner, but 1 lb weight loss from last year noted. No obvious changes in behavior or appetite that owner had noted at home. Screening bloodwork taken at visit. Elevated amylase noted on bloodwork - had recommended rechecking values in 4-6 weeks, but owner reported that several vomit piles were noted in house and P may have had seizure or syncopal event following a vomiting episode. Otherwise has been normal at home, recommended abdominal U/S, chest radiographs
Abnormal PE/Chem/CBC/UA Results: Weight loss - 1 lb Unremarkable chest radiographs Amylase 2,959 (623 - 2,239 U/L)

ULTRASONOGRAPHIC EXAMINATION OF THE ABDOMEN

Urinary System

The **urinary bladder**, trigone, and pelvic urethra presented normal thicknesses and normal tone. The ureters were not visible which is normal. A minor amount of suspended debris was noted. No evidence of inflammatory or neoplastic changes was noted. Ureteral papillae were normal.

The **kidneys** revealed normal size and structure, corticomedullary definition and ratio for this age. The cortices presented largely uniform texture with normal echogenic relationship to liver and spleen. Medullary structure differed distinctly from the cortex and no evidence of pelvic dilation was present. The capsules were acceptably uniform without significant irregularities. The right kidney measured 4.0 cm. The left kidney measured 3.7 cm.

Adrenal Glands

Both **adrenal glands** were visualized and recognized as having normal shape, size, position and echogenicity for this breed. The phrenic vasculature, glandular echogenicity and detail were unremarkable. Capsule, cortex, and medullary definition were normal for this age patient. The left adrenal gland measured 0.36 cm. The right adrenal gland measured 0.4 cm.

Spleen

The **spleen** presented a smooth homogeneous parenchyma hyperechoic to liver and renal cortical parenchyma. The capsule was smooth without noticeable expansion or deviation from within the spleen or adjacent pathology. The splenic vasculature demonstrated normal volume without signs of congestion or thrombosis. No sonographic evidence of acute or chronic inflammatory, neoplastic, or infarctual changes was noted.

Liver

The **liver** images submitted revealed subjectively normal liver size, contour, and structure. Parenchymal echogenicity was naturally coarse and hypoechoic to the spleen. Vascular and biliary tracts were of normal volume with no evidence of congestion. The gallbladder presented acceptably thin walls with primarily anechoic content. The cystic and common bile ducts were normal. No pathological hepatic



PATIENT

Skippy Jon Holton
Anglin

lymphadenopathy was evident. No overt structural evidence of inflammatory, infiltrative or regenerative pathology was evident.

SPECIES

Feline

Gastrointestinal

The **gastrointestinal tract** revealed minor variable thickening and echogenic submucosal changes most consistent with low grade end result of chronic GI disease such as IBD and may be related to malassimilation of nutrients if any weight loss is present. No obvious neoplastic patterns were noted and luminal content as unremarkable.

BREED

Siamese

SEX

Neutered male

Pancreas

The base and limbs of the **pancreas** were observed to be largely isoechoic to surrounding omental fat. Pancreatic duct and capsular contour were acceptably normal and parenchyma respected normal curvilinear patterns. No overt evidence of active inflammatory or neoplastic disease was noted.

AGE

9 years

ULTRASONOGRAPHIC FINDINGS

Structurally unremarkable abdomen.

WEIGHT

10.5 lbs

Minor chronic intestinal changes.

INTERPRETED BY

Eric Lindquist, DMV
DABVP, Cert. IVUSS

INTERPRETATION OF THE FINDINGS & FURTHER RECOMMENDATIONS

There was no evidence of significant disease. Maldigestion panel, three view chest radiographs and full CNS examination is recommended to examine for occult disease that could be responsible for the weight loss. Evaluation for competitive eating environments should also be considered.

IMAGING PERFORMED BY

Dr. Reese

HOSPITAL NAME

Willow Run VC

REFERRING VET

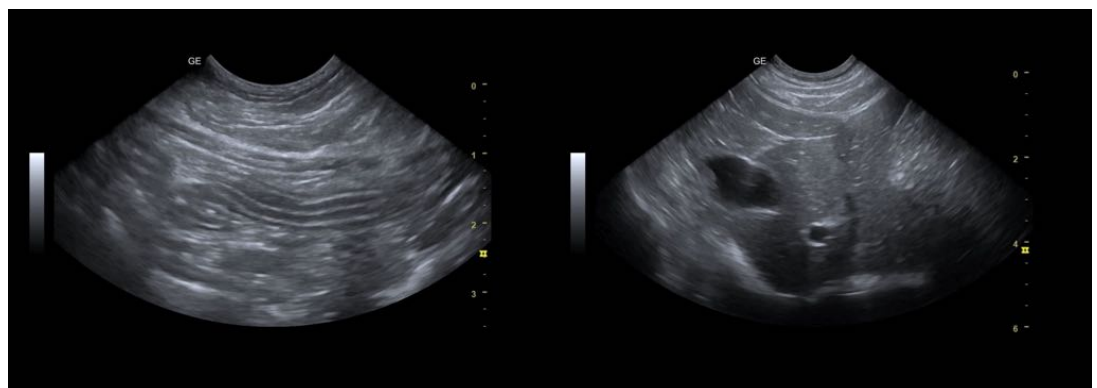
Dr. Reese

INVOICE

42697

DATE

11/23/22





PATIENT

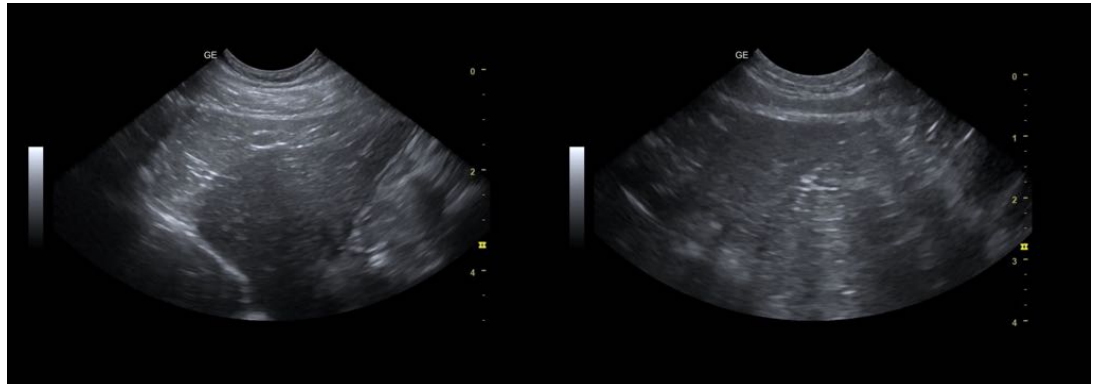
Skippy Jon Holton
Anglin

SPECIES

Feline

BREED

Siamese



SEX

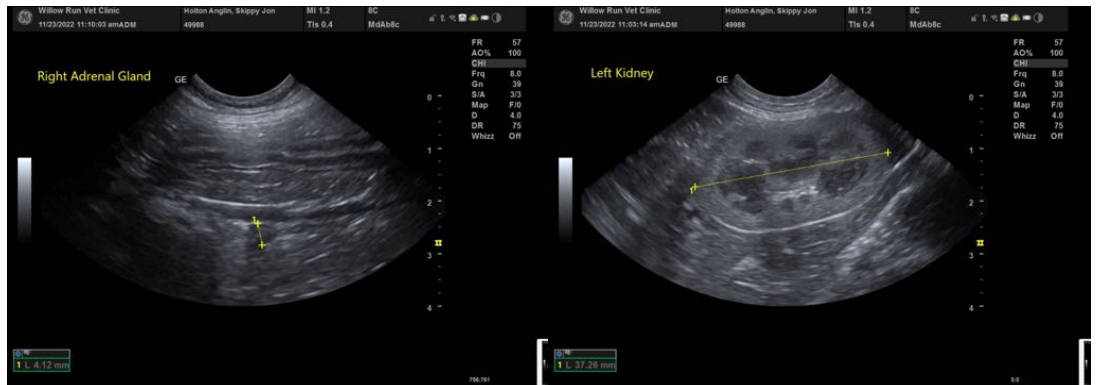
Neutered male

AGE

9 years

WEIGHT

10.5 lbs



INTERPRETED BY

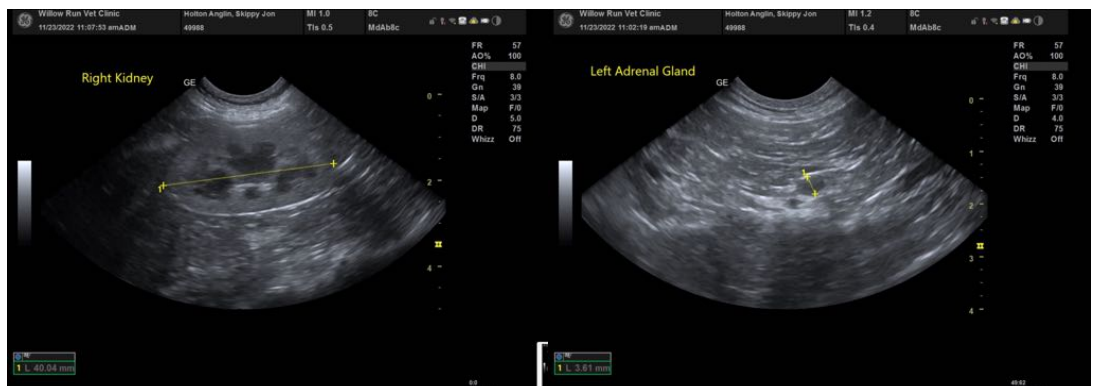
Eric Lindquist, DMV
DABVP, Cert. IVUSS

IMAGING PERFORMED BY

Dr. Reese

HOSPITAL NAME

Willow Run VC



REFERRING VET

Dr. Reese

INVOICE

42697

DATE

11/23/22

The information and recommendations provided are based on the images presented by the referring veterinarian/sonographer. No evaluation can be communicated regarding pathology that was not visible in the image/video clips provided.

Thank you for this referral. If the clinical or image interpretation does not parallel your findings or if I can be of any further assistance please contact me.

Eric Lindquist, DMV, DABVP, Cert. IVUSS, CEO of SonoPath.com
info@SonoPath.com