



PATIENT

Hugo Cort

PRESENTING CLINICAL SIGNS

History: recheck from yesterday, checking if sock is still there and needs surgery

SPECIES

Canine

ULTRASONOGRAPHIC EXAMINATION OF THE ABDOMEN

The stomach in this patient revealed progressively shadowing pyloric structure that is persistently present. The structure occupied the stomach. The small intestine and colon were unremarkable.

BREED

Staffordshire Terrier

ULTRASONOGRAPHIC FINDINGS

Gastric foreign body.

SEX

Neutered male

INTERPRETATION OF THE FINDINGS & FURTHER RECOMMENDATIONS

AGE

3 years

The foreign body was visible in multiple views.

WEIGHT

78 lbs

INTERPRETED BY

Eric Lindquist, DMV
DABVP, Cert. IVUSS

IMAGING PERFORMED BY

Jenn

HOSPITAL NAME

Rockaway AH

REFERRING VET

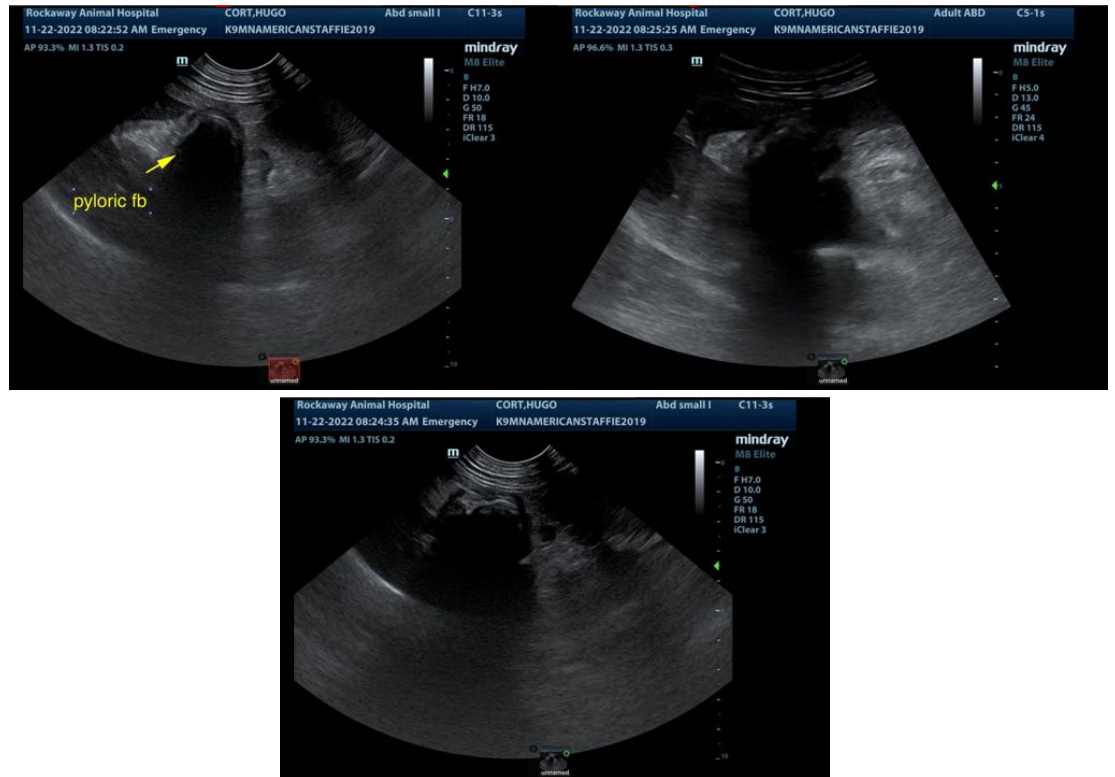
Dr. Maniar

INVOICE

42622

DATE

11/21/22



The information and recommendations provided are based on the images presented by the referring veterinarian/sonographer. No evaluation can be communicated regarding pathology that was not visible in the image/video clips provided.

Thank you for this referral. If the clinical or image interpretation does not parallel your findings or if I can be of any further assistance please contact me.

Eric Lindquist, DMV, DABVP, Cert. IVUSS, CEO of SonoPath.com
info@SonoPath.com