



## PATIENT

Kiko Snyder

## SPECIES

Canine

## BREED

Goldendoodle

## SEX

Neutered Male

## AGE

12 Years

## WEIGHT

69.6 lbs

## INTERPRETED BY

Eric Lindquist, DMV,  
DABVP (CFM), Cert.  
IVUSS

## IMAGING PERFORMED BY

Jenni Tudini, MRCVS,  
SDEP Certified (Abd)

## HOSPITAL NAME

East Aurora Veterinary  
Hospital

## REFERRING VET

Dr. Holly Guenther

## INVOICE

72051

## DATE

11/21/25

## PRESENTING CLINICAL SIGNS

Patient recently seen for routine annual exam and new cardiac murmur noted in combination with mild increase in ProBNP led to recommendation to pursue echocardiogram. Owners wishing to be very proactive in management

Abnormal PE/Chem/CBC/UA Results: Cardiovascular Notes: - Grade 2-3/6 left sided murmur - No arrhythmia auscultated - Strong synchronous pulses - CBC - NSF - Chem - ALP 431, chol 463 - proBNP - 1050 - UA - SG 1.028, trace protein, UPC 0.1 - 4DX - negative - Fecal - negative

## ULTRASONOGRAPHIC EXAMINATION OF THE HEART

CANINE CARDIAC PARAMETERS	MR VMAX (m/s)	TR VMAX (m/s)	LA/AO (M-Mode)	LA/AO (Heart Base; Swe)	FS (%)	EF (%)	EPSS (cm)
NORMAL PARAMETER	4.5-5.5	<2.7	1.3	Up to 1.6	28-40	40-100	<0.6
PATIENT	--	--	1.0	1.34	24	47	0.75
CANINE CARDIAC PARAMETERS	HR (BPM)	AV VMAX (m/s)	PV MAX (m/s)	BODY WEIGHT (lbs)	LAD LA MAX 4 Chamber	LVIDd Avg; 2D and m-mode short axis (cm)	LVIDs Avg; 2D and m-mode short axis (cm)
NORMAL PARAMETER	50-100	0.7-1.7	0.7-1.6				
PATIENT	--	1.5	0.8	69.6	3.9	4.9	--

## Cardiac Presentation

The echocardiogram in this patient demonstrated normal **left atrial** size based on 3 separate methods of LA evaluation. Mild eccentric **mitral** insufficiency noted. The **left ventricle** presented thicknesses with linear contour and was not dilated nor restricted. The **myocardium** presented normal echogenicity without subjective evidence of significant fibrotic or ischemic disease. **Contractility** of the ventricular walls was adequate and in normal range for this patient evidenced by the fractional shortening measurement and subjective evaluation of the different regions of the myocardium. The **left ventricular outflow** tract demonstrated normal laminar flow and subjective structural integrity. The **right atrium** and auricle revealed normal size, structure and content. No evidence of masses was noted. **Tricuspid** valvular assessment demonstrated adequate linear morphology and kinesis. The **right ventricle** was of normal size (1/3 diameter of LV), chordae structure, myocardial echogenicity and thickness. **Pulmonary outflow** tract assessment revealed normal valve structure, laminar flow, and diameter (approx. 1:1 pa/ao ratio). No visible **pericardial** or free pleura fluid was noted. The cranial **mediastinum** and **pericardial** and **extra-cardiac** regions were free of masses in the visible window. Hepatic veins were not dilated.

## ULTRASONOGRAPHIC FINDINGS

- Stage B1 valvular disease.
- Mild eccentric mitral insufficiency.



## PATIENT

Kiko Snyder

## SPECIES

Canine

## BREED

Goldendoodle

## SEX

Neutered Male

## AGE

12 Years

## WEIGHT

69.6 lbs

## INTERPRETED BY

Eric Lindquist, DMV,  
DABVP (CFM), Cert.  
IVUSS

## IMAGING PERFORMED BY

Jenni Tudini, MRCVS,  
SDEP Certified (Abd)

## HOSPITAL NAME

East Aurora Veterinary  
Hospital

## REFERRING VET

Dr. Holly Guenther

## INVOICE

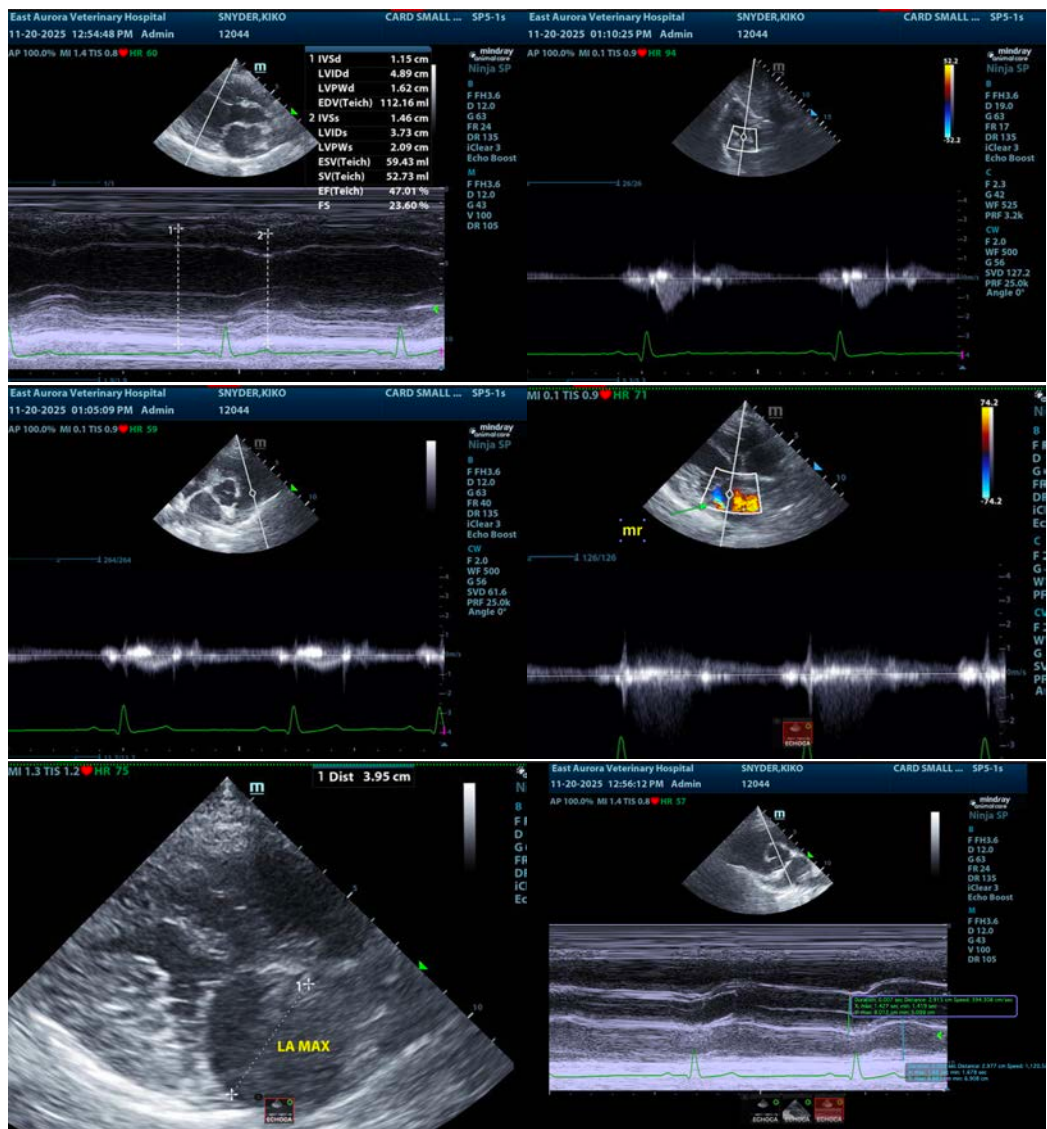
72051

## DATE

11/21/25

## INTERPRETATION OF THE FINDINGS & FURTHER RECOMMENDATIONS

The heart is stable without clinical disease. No overt contraindication for anesthesia of brief to moderate duration. I suggest Torbutrol premed, Propofol induction, Isoflor maintenance or similar protocol if anesthesia is desired. Blood pressure, EKG and chest radiographs are recommended if not already performed. Target white coat negative systolic pressure of < 160 mmHg. If higher than this ACE-inhibitor is suggested to reach this level. Recheck echocardiogram is recommended in 6 months, earlier if murmur grade increases or clinical signs initiate.





**PATIENT**

Kiko Snyder

**SPECIES**

Canine

**BREED**

Goldendoodle

**SEX**

Neutered Male

**AGE**

12 Years

**WEIGHT**

69.6 lbs

**INTERPRETED BY**

Eric Lindquist, DMV,  
DABVP (CFM), Cert. IVUSS

**IMAGING PERFORMED BY**

Jenni Tudini, MRCVS,  
SDEP Certified (Abd)

**HOSPITAL NAME**

East Aurora Veterinary  
Hospital

**REFERRING VET**

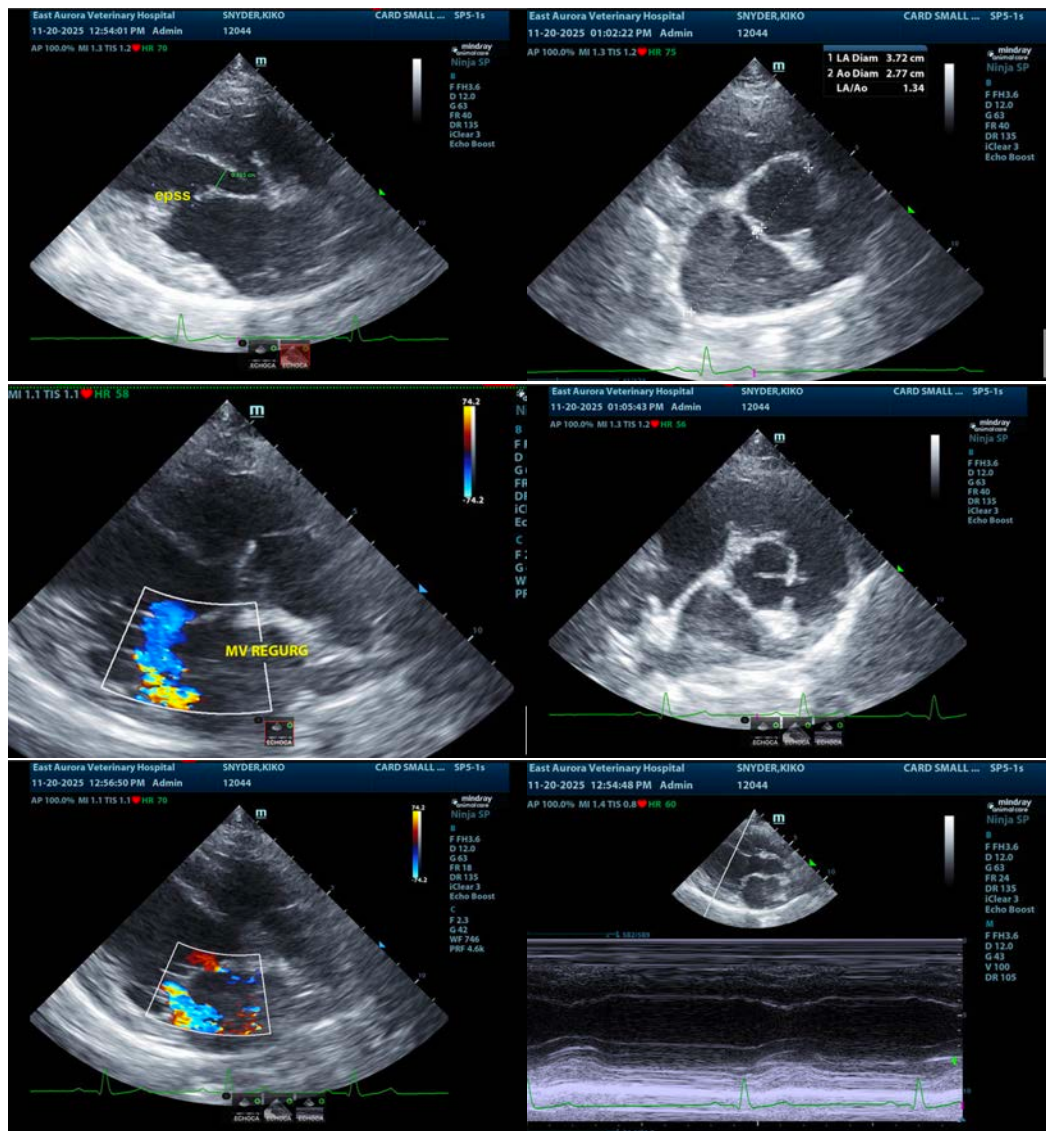
Dr. Holly Guenther

**INVOICE**

72051

**DATE**

11/21/25



The information and recommendations provided are based on the images presented by the referring veterinarian/sonographer. No evaluation can be communicated regarding pathology that was not visible in the image/video clips provided.

Thank you for this referral. If the clinical or image interpretation does not parallel your findings or if I can be of any further assistance please contact me.

**Eric Lindquist, DMV, DABVP(CFM), Cert. IVUSS,**  
CEO, Owner, Founder -- SonoPath.com  
[info@SonoPath.com](mailto:info@SonoPath.com)