



PATIENT

Jinx Andrews

SPECIES

Feline

BREED

Maine Coon

SEX

Spayed Female

AGE

1 Year 8 Months

WEIGHT

7.2 kg

INTERPRETED BY

Eric Lindquist, DMV,
DABVP (CFM), Cert.
IVUSS

IMAGING PERFORMED BY

Dr. Gira

HOSPITAL NAME

Argo Vet

REFERRING VET

Dr. Louise Lam

INVOICE

72063

DATE

11/21/25

PRESENTING CLINICAL SIGNS

Pertinent History Reduced energy levels and appetite (acute) Acute vomiting bile and diarrhea Pyrexia of unknown origin.

Abnormal PE/Chem/CBC/UA Results: Attached

ULTRASONOGRAPHIC EXAMINATION OF THE ABDOMEN

Urinary System

The **urinary bladder**, trigone, and pelvic urethra presented normal thicknesses and normal tone. The ureters were not visible which is normal. No uroliths or sediment were visualized and anechoic urine was present. No evidence of inflammatory or neoplastic changes were noted. Ureteral papillae were normal.

The **kidneys** revealed normal size and structure, corticomedullary definition and ratio for this age. The cortices presented largely uniform texture with normal echogenic relationship to liver and spleen. Medullary structure differed distinctly from the cortex and no evidence of pelvic dilation was present. The capsules were acceptably uniform without significant irregularities. The left kidney measured 4.05 cm. The right kidney measured 3.94 cm.

Adrenal Glands

The **right adrenal gland** was visualized and recognized as having normal shape, size, position and echogenicity for this breed. The phrenic vasculature, glandular echogenicity and detail were unremarkable. Capsule, cortex, and medullary definition were normal for this age patient. The right adrenal gland measured 0.34 cm.

The region of the **left adrenal gland** was unremarkable.

Spleen


The **spleen** was mildly enlarged (up to 1.8 cm) with uniform, but subtly micronodular parenchyma, and undulating capsular contour. This is consistent with reactive spleen owing to immune stimulus or early infiltrative disease such as mast cell disease or lymphoma. 25-gauge FNA would be ideal if weight loss is an issue to differentiate early round cell neoplasia versus splenitis or reactive spleen all of which can present in this manner.

Liver

The **liver** images submitted revealed subjectively normal liver size, contour, and structure. Parenchymal echogenicity was naturally coarse and hypoechoic to the spleen. Vascular and biliary tracts were of normal volume with no evidence of congestion. The gallbladder presented acceptably thin walls with primarily anechoic content. The cystic and common bile ducts were normal. No pathological hepatic lymphadenopathy was evident. No overt structural evidence of inflammatory, infiltrative or regenerative pathology was evident.

Gastrointestinal

Examination of the **gastrointestinal tract** revealed a stomach and intestine free of stasis, of normal wall thickness, acceptable curvilinear mural detail, and peristaltic activity. Small and large intestine



PATIENT

Jinx Andrews

SPECIES

Feline

BREED

Maine Coon

SEX

Spayed Female

AGE

1 Year 8 Months

WEIGHT

7.2 kg

INTERPRETED BY

Eric Lindquist, DMV,
DABVP (CFM), Cert.
IVUS

IMAGING PERFORMED BY

Dr. Gira

HOSPITAL NAME

Argo Vet

REFERRING VET

Dr. Louise Lam

INVOICE

72063

DATE

11/21/25

demonstrated normal luminal chyme and stool consistency respectively. No obstructive or overt infiltrative disease was noted.

Pancreas

The base and limbs of the **pancreas** were observed to be largely isoechoic to surrounding omental fat. Pancreatic duct and capsular contour were acceptably normal and parenchyma respected normal curvilinear patterns. No overt evidence of active inflammatory or neoplastic disease was noted.

Free Abdomen

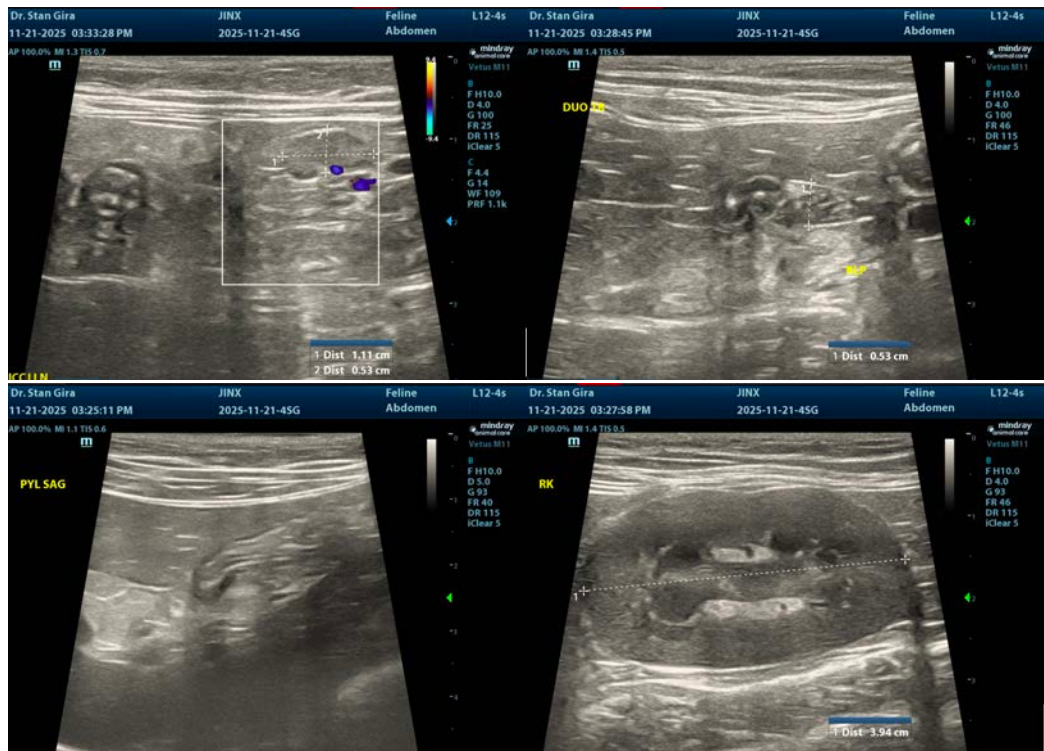
Mesenteric, epigastric and jejunal lymph nodes presented normal length to width ratio with slight, swollen contour. A mesenteric lymph node measured 1.1 cm x 0.53 cm. An epigastric lymph node measured 1.0 cm x 0.63 cm. A jejunal lymph node measured 1.4 cm x 0.44 cm. There was no loss of parenchymal detail. This is most consistent with reactive lymphadenitis or lymphatic hyperplasia.

ULTRASONOGRAPHIC FINDINGS

- Enlarged, micronodular spleen.
- Slight regional reactive lymphadenopathy.

INTERPRETATION OF THE FINDINGS & FURTHER RECOMMENDATIONS

Assessment of splenic FNA for round cell neoplasia versus splenitis or reactive splen.





PATIENT

Jinx Andrews

SPECIES

Feline

BREED

Maine Coon

SEX

Spayed Female

AGE

1 Year 8 Months

WEIGHT

7.2 kg

INTERPRETED BY

Eric Lindquist, DMV,
DABVP (CFM), Cert.
IVUSS

IMAGING PERFORMED BY

Dr. Gira

HOSPITAL NAME

Argo Vet

REFERRING VET

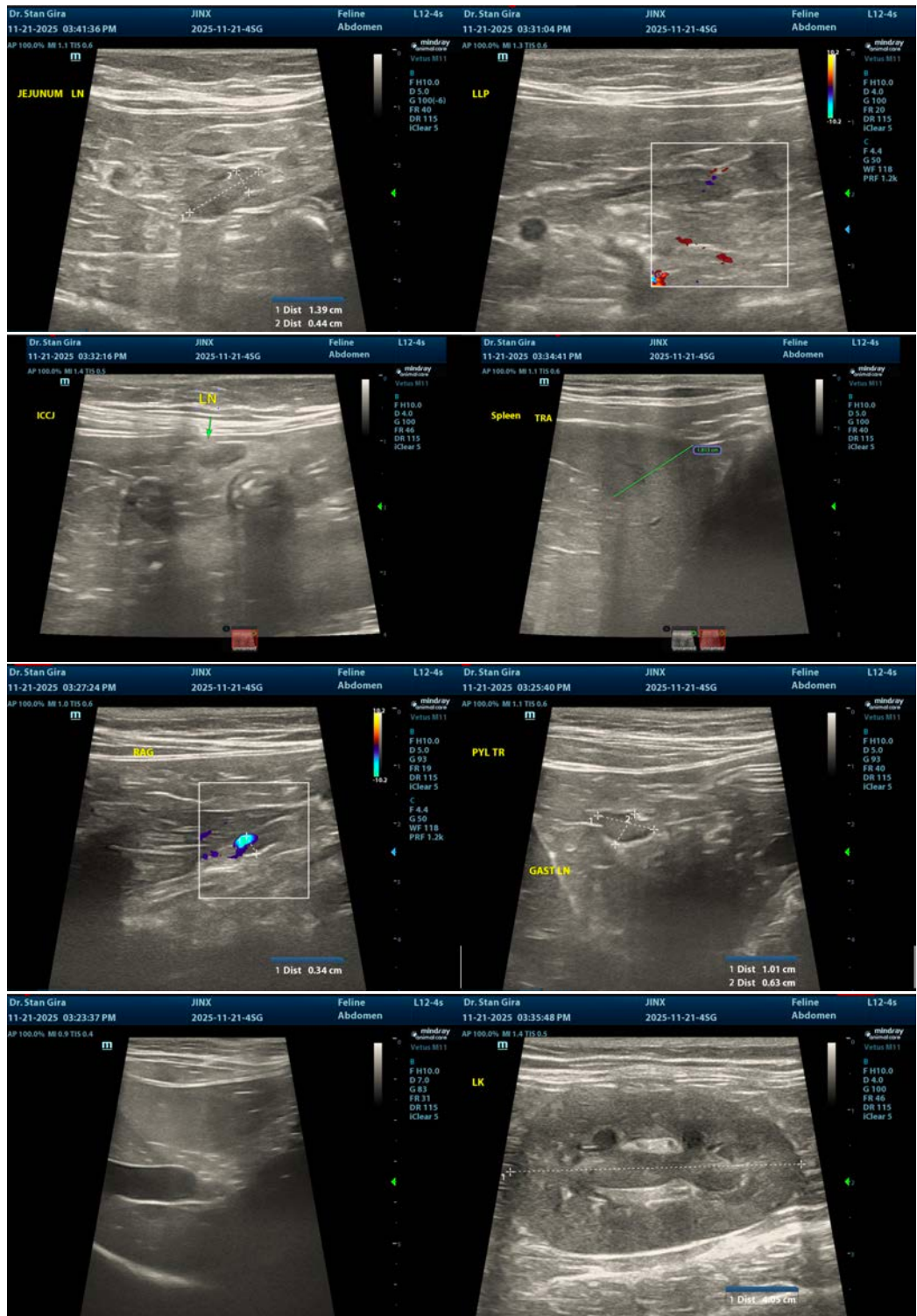
Dr. Louise Lam

INVOICE

72063

DATE

11/21/25





PATIENT

Jinx Andrews

SPECIES

Feline

BREED

Maine Coon

SEX

Spayed Female

AGE

1 Year 8 Months

WEIGHT

7.2 kg

INTERPRETED BY

Eric Lindquist, DMV,
DABVP (CFM), Cert.
IVUSS

IMAGING PERFORMED BY

Dr. Gira

HOSPITAL NAME

Argo Vet

REFERRING VET

Dr. Louise Lam

INVOICE

72063

DATE

11/21/25

The information and recommendations provided are based on the images presented by the referring veterinarian/sonographer. No evaluation can be communicated regarding pathology that was not visible in the image/video clips provided.

Thank you for this referral. If the clinical or image interpretation does not parallel your findings or if I can be of any further assistance please contact me.

Eric Lindquist, DMV, DABVP(CFM), Cert. IVUSS,
CEO, Owner, Founder -- SonoPath.com
info@SonoPath.com