


DATE PRESENTING CLINICAL SIGNS

11/21/25

PATIENT

Dillon Parkhurst

SPECIES

Canine

BREED
Cavalier King Charles
Spaniel
SEX

Neutered Male

AGE

11/20/12

WEIGHT

14.27 lbs

INTERPRETED BY
Eric Lindquist, DMV,
DABVP, Cert. IVUSS
HOSPITAL NAME
Animal Emergency
Hospital
REFERRING VET

Dr. Willer

INVOICE

72038

Patient History: Diabetes mellitus with worsening glycemic control over past 4 weeks despite weekly rechecks - Blood glucose >500 mg/dL at recent check - Persistent ketonuria for several weeks - Current medications: Vetmedin 2.5mg, 1.5 tablets PO q24h (total 3.75mg daily) - Polydipsia and polyuria with urinary incontinence - Eating - Coughing - client concerned about cardiac disease- needs to schedule an appointment with cardiologist - Decreased activity level, increased sleeping - Congenital/acquired limb deformities since adoption from breeding situation (SPCA rescue from California breeding operation attempting to create "micro-mini" dogs) - Grade 3/6 heart murmur present for most of life, monitored regularly - Elevated liver enzyme on labs approximately 1 month ago - Recently lost another dog RDVM notes DX with DM on 10/23/25- ketones in the urine at that time elevated ALP: decreased NA increased neutrophils increased mono borderline anemia baseline cortisol 9.4 (elevated) concern with abnormal area in the trachea started on vetsulin recheck 1 week later- still drinking more increased vetsulin to 5 units BID 11/11/25 urinating in the house still excessive drinking eating well increased vetsulin 6 units BID drop off UA on 11/14 ketone 3+ gluc 3+ neg for blood no bacterial protein trace 11/20 PU/PD BG 715 (7 hours post injection) ketone positive still in the urine lost 2 lb

Current Medications: Ondansetron, Famotidine.

Labwork Results: Labwork attached.

Date of Previous IntraPet Ultrasound: No previous.

Sedation: Not required to complete full diagnostic ultrasound.

Stat Report: Not requested.

Imaging Performed by: Rachel Brillhart, RDMS.

ULTRASONOGRAPHIC EXAMINATION OF THE ABDOMEN
Urinary System

The **urinary bladder**, trigone, and pelvic urethra presented normal thicknesses and normal tone. The ureters were not visible which is normal. No uroliths or sediment were visualized and anechoic urine was present. No evidence of inflammatory or neoplastic changes were noted. Ureteral papillae were normal.

The residual prostate was uniform at 1.0 cm.

The **left kidney** revealed largely normal size and structure, corticomedullary definition and ratio (cortex 1/3 of medulla) were essentially maintained with some age-related loss of curvilinear patterns regarding the capsule and C/M junction. The cortices presented largely uniform texture with some increased echogenicity expected for his age patient. Medullary structure differed distinctly from that of the cortex. Left kidney measured 5.34 cm with pyelectasia of 1.4 cm x 1.24 cm.

The **right kidney** presented normal size and fairly normal contour with polycystic cortical changes, measuring 5.57 cm. Mild degenerative changes noted.

Adrenal Glands

Both **adrenal glands** were visualized and recognized as having normal shape, size, position and echogenicity for this breed. The phrenic vasculature, glandular echogenicity and detail were unremarkable. Capsule, cortex, and medullary definition were normal for this age patient. The left adrenal gland measured 1.8 cm x 0.57 cm at the caudal pole and 0.58 cm at the cranial pole. The right adrenal gland measured 1.52 cm x 1.0 cm at the cranial pole and 0.62 cm at the caudal pole.

Spleen

The **spleen** presented multifocal hypoechoic expansive parenchymal nodular changes/masses, measuring 3.2 cm and 1.7 cm. Other micronodular changes noted with capsular expansion. Spleen measured 0.81 cm.

Liver

The **liver** was swollen with multifocal coalescing hypoechoic nodular changes noted. The gallbladder and common bile duct were unremarkable.

Gastrointestinal

Examination of the **gastrointestinal tract** revealed a stomach and intestine free of stasis, of normal wall thickness, acceptable curvilinear mural detail, and peristaltic activity. Small and large intestine demonstrated normal luminal chyme and stool consistency respectively. No obstructive or overt infiltrative disease was noted. No associated abnormal lymphatic activity was noted.

Pancreas

The base and limbs of the **pancreas** were observed to be largely isoechoic to surrounding omental fat. Some parenchymal remodeling, however, with mild deviation from curvilinear normalcy was observed. Pancreatic duct and capsular irregularities were present consistent with age related changes. If pain upon imaging (+ Murphy sign) was present or if the patient is focally painful in subxyphoid palpation then low-grade smoldering chronic pancreatitis should be suspected.

Free Abdomen

The mesenteric **lymph nodes** presented normal length to width ratio with slight, swollen contour. There was no loss of parenchymal detail. This is most consistent with reactive lymphadenitis or lymphatic hyperplasia. Example measured 1.76 cm x 0.47 cm.

Rapid view of the heart revealed no evident pathology in the right auricle or pericardium.

ULTRASONOGRAPHIC FINDINGS

- Multifocal splenic neoplasia.
- Swollen, nodular liver.
- Reactive mesenteric lymph nodes.
- Age related renal and pancreatic changes.

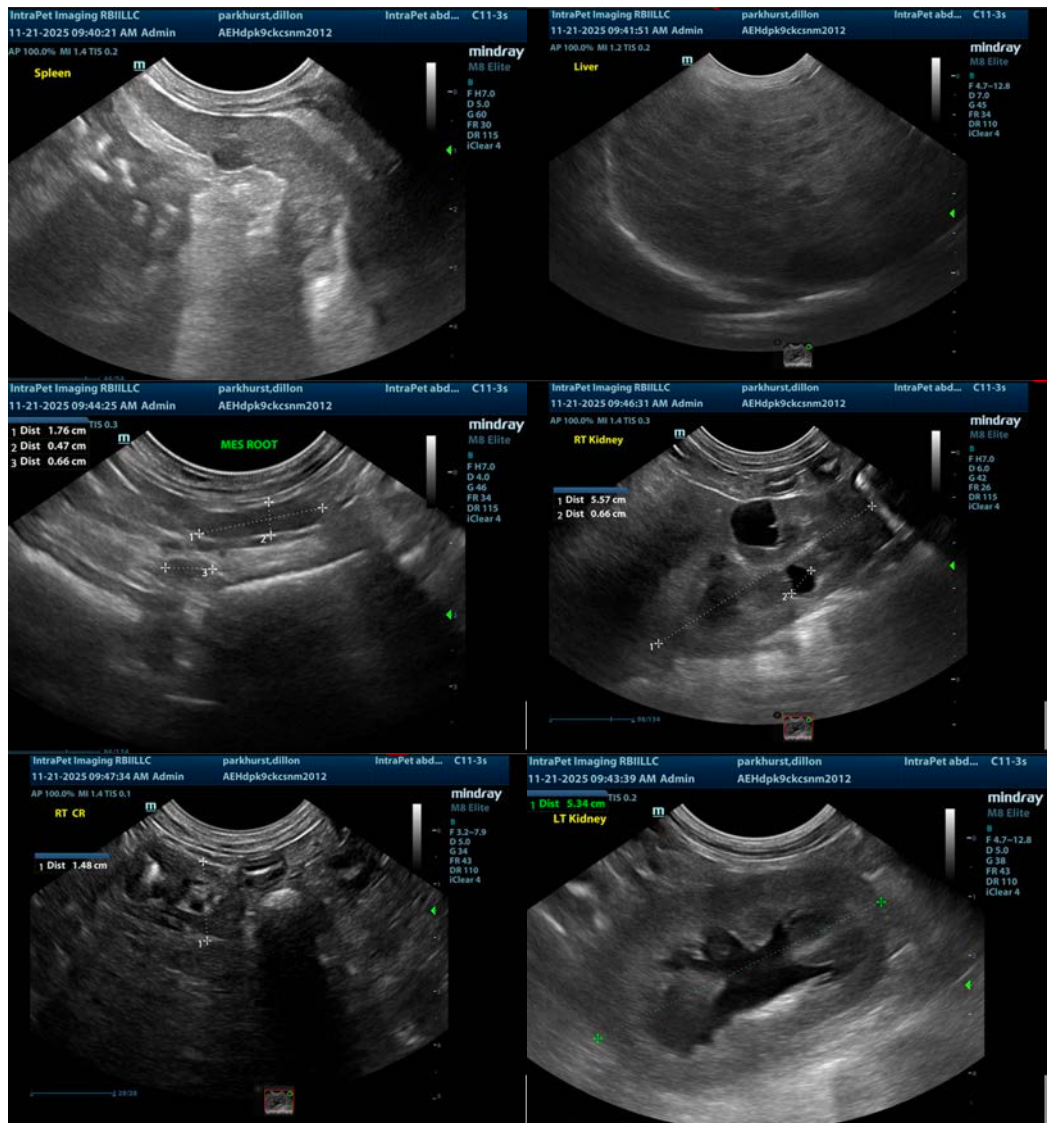
INTERPRETATION OF THE FINDINGS & FURTHER RECOMMENDATIONS

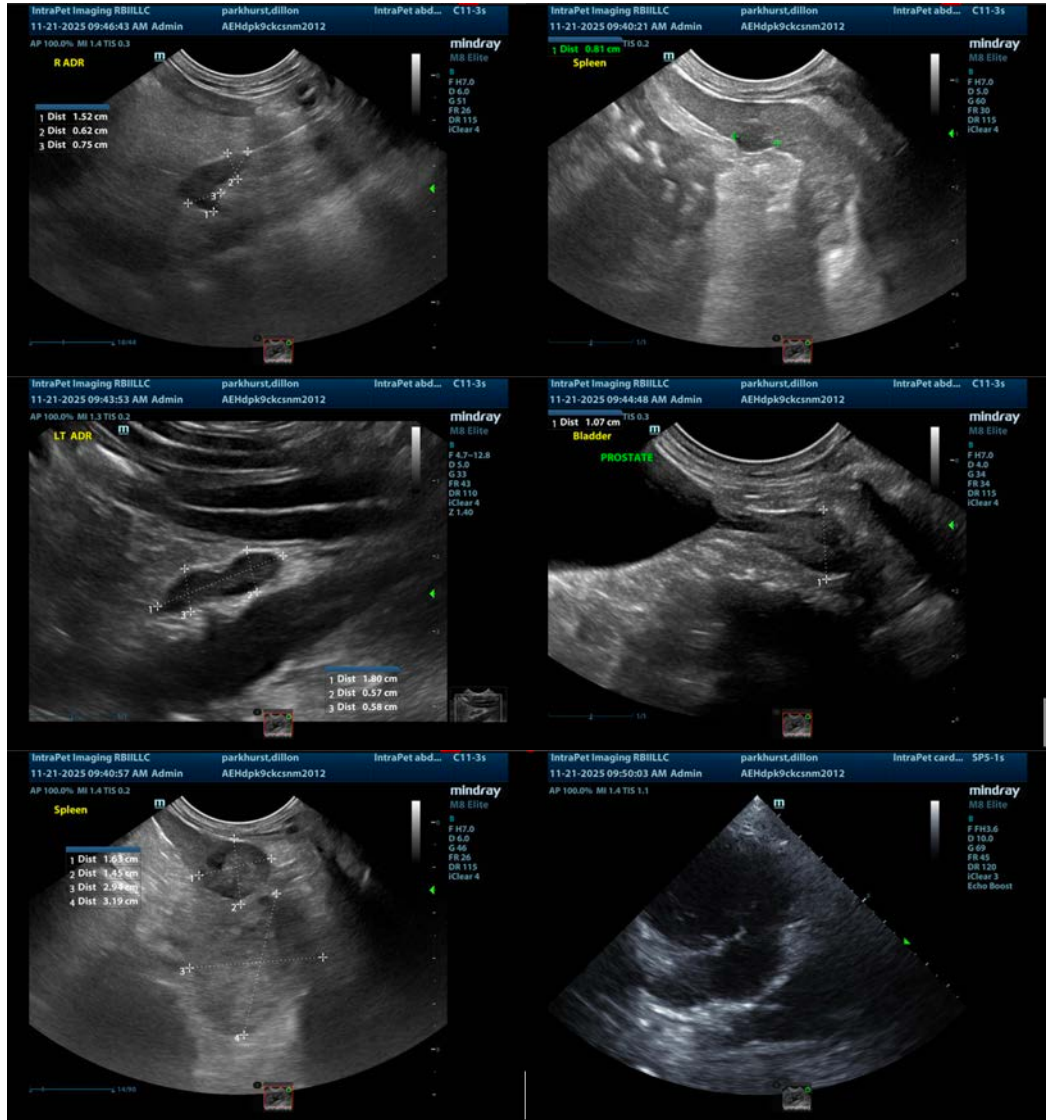
FNA spleen and liver warranted for staging purposes. If by chance the liver is benign, then splenectomy should be considered. However, I'm concerned for round cell neoplasia. Hemangiosarcoma also possible. Prognosis is guarded. Chest radiographs warranted, if not already performed, to assess for metastatic disease.

This is a suggestive checkoff list when faced with an unregulated diabetic patient:

- UTI
- Dietary indiscretion/intolerance
- Pancreatitis
- Hyperthyroidism/hypothyroidism
- Exogenous steroids (including topical eye meds)
- Cushing's

- Acromegaly
- Owner compliance
- Insulin quality issues
- Antibodies to insulin
- Underlying Neoplasia
- Diffuse liver disease





The information and recommendations provided are based on the images presented by the referring veterinarian/sonographer. No evaluation can be communicated regarding pathology that was not visible in the image/video clips provided.

Thank you for this referral. If the clinical or image interpretation does not parallel your findings or if I can be of any further assistance please contact me.

Eric Lindquist, DMV, DABVP(CFM), Cert. IVUSS,
 CEO, Owner, Founder -- SonoPath.com
info@SonoPath.com