



**PATIENT**

Chewbacca Burnette-Guiles

**SPECIES**

Feline

**BREED**

DLH

**SEX**

Neutered Male

**AGE**

11 Years

**WEIGHT**

9.9 lbs

**PRESENTING CLINICAL SIGNS**

Grade III heart murmur. Receiving Methimazole 5mg; Gabapentin for scan

**ULTRASONOGRAPHIC EXAMINATION OF THE HEART**

FELINE CARDIAC PARAMETERS	BODY WEIGHT (lbs)	HR (BPM)	IVSd (cm)	LVIDd (cm)	LVWd (cm)	FS (%)	EF (%)
NORMAL PARAMETER	-----	150-240	0.3-0.6	1.0-2.1	0.25-0.6	35-67	80-100
PATIENT	9.9	NM	0.5	1.4	0.5	50	80
FELINE CARDIAC PARAMETERS	LA/AO (M-mode)	LA/AO HEART BASE (Sisson)	LAD LA MAX 4 Chamber		LVOT VEL. (m/s)	RVOT VEL. (m/s)	IVRT (m/)
NORMAL PARAMETER	<1.5	1.6	0.7-1.7		<1.6	<1.3	40-60
PATIENT	1.2	1.2	1.2		1.0	1.0	NM
Adapted from June Boon, Veterinary Echocardiography, 1998 Sisson D et al. JVIM 1991; 5: 232, Jacobs et al. Am J Vet Res 1985; 46:1705							

**INTERPRETED BY**

Eric Lindquist, DMV, DABVP (CFM), Cert. IVUSS

E-wave velocity = 0.7

**Cardiac Presentation**

The echocardiogram in this patient demonstrated normal **left atrial** size based on 3 separate LA measurements. The cranial and caudal **mitral** valve leaflets presented normal linear structure and kinetics. The **left ventricle** presented normal thicknesses with linear contour and was not dilated nor restricted. The **myocardium** presented normal echogenicity without subjective evidence of significant fibrotic or ischemic disease. **Contractility** of the ventricular walls was adequate and in normal range for this patient evidenced by the fractional shortening measurement and subjective evaluation of the different regions and angles of the myocardium. The **left ventricular outflow** tract demonstrated normal laminar flow and subjective structural integrity. The **right atrium** and auricle revealed normal size, structure and content. No evidence of masses was noted or chamber overload. **Tricuspid** valvular assessment demonstrated adequate linear morphology and kinetics. The **right ventricle** was of normal size (1/3 diameter of LV), chordae structure, myocardial echogenicity and thickness. **Pulmonic** tract assessment revealed normal valve structure, laminar flow, and diameter (approx. 1:1 pa/ao ratio). No visible **pericardial** or free pleura fluid was noted or extra cardiac pathology in the visible planes. The cranial **mediastinum** and **pericardial** regions were free of masses in the visible window.

Color flow assessment did not demonstrate any significant turbulence, likely flow murmur.

**IMAGING PERFORMED BY**

Shari Reffi, CVT

**HOSPITAL NAME**

Warren Animal Hospital

**REFERRING VET**

Dr. Nicole

**INVOICE**

72042

**DATE**

11/21/25

**ULTRASONOGRAPHIC FINDINGS**

- Normal echocardiogram with idiopathic flow murmur.



**PATIENT**

Chewbacca Burnette-Guiles

**SPECIES**

Feline

**BREED**

DLH

**SEX**

Neutered Male

**AGE**

11 Years

**WEIGHT**

9.9 lbs

**INTERPRETED BY**

Eric Lindquist, DMV,  
 DABVP (CFM), Cert.  
 IVUSS

**IMAGING PERFORMED BY**

Shari Reffi, CVT

**HOSPITAL NAME**

Warren Animal Hospital

**REFERRING VET**

Dr. Nicole

**INVOICE**

72042

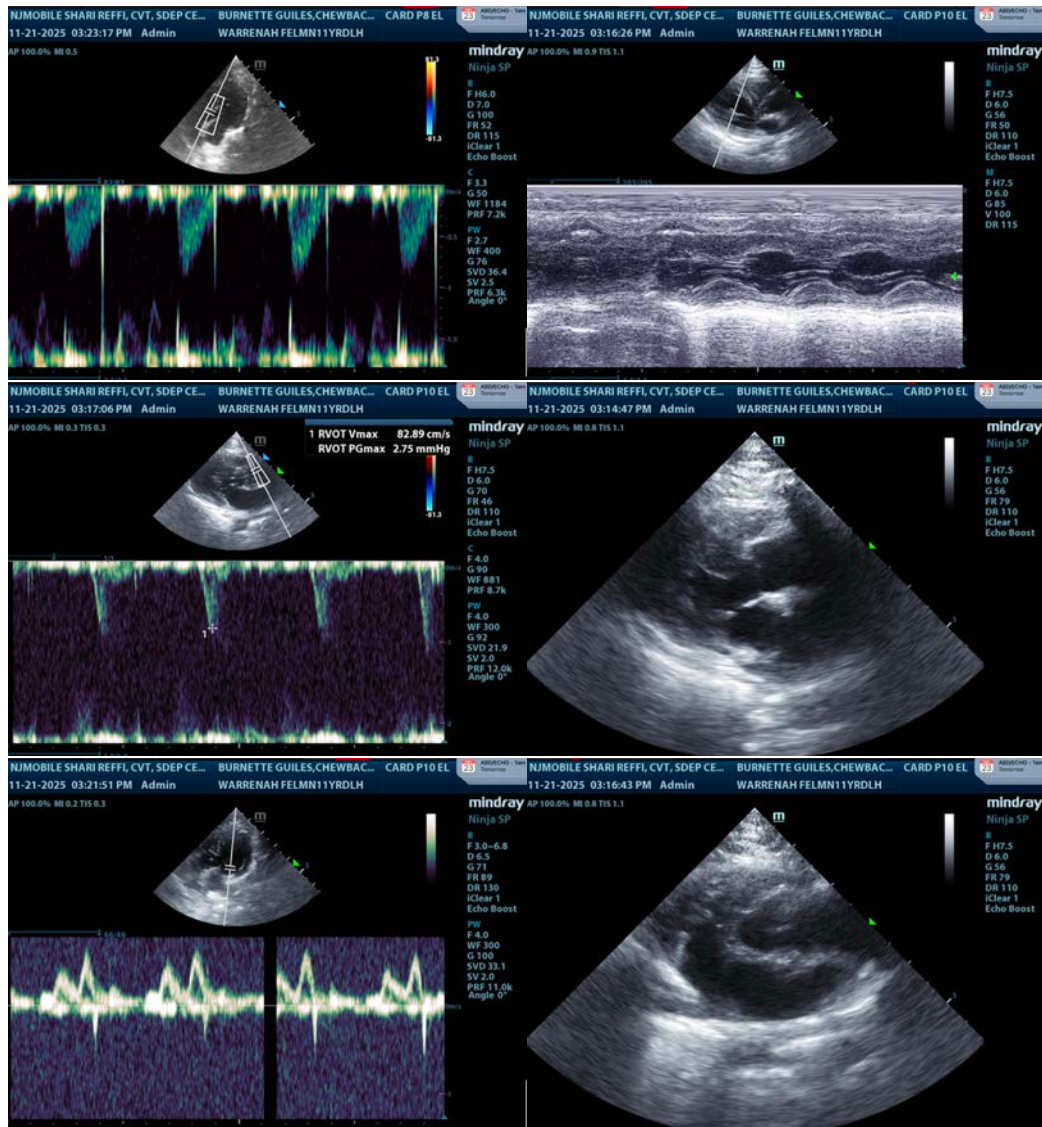
**DATE**

11/21/25

**INTERPRETATION OF THE FINDINGS & FURTHER RECOMMENDATIONS**

No evidence of pathology. No contraindication to anesthetic procedure.

Flow murmurs can be caused by volume shifts, anemia, excitable/tachycardic state, DRVOTO (Dynamic Right Ventricular Outflow Obstruction), or even simple stethoscope pressure upon clinical exam. These flow murmurs are typically benign and may develop often later in life theoretically owing to age related clinically insignificant changes of the heart. If the patient is recently clinical for anorexia, weight loss or metabolic disturbances, an abdominal sonogram and full workup may be appropriate to assess underlying clinical systemic causes of a newly developed flow murmur.





**PATIENT**

Chewbacca Burnette-Guiles

**SPECIES**

Feline

**BREED**

DLH

**SEX**

Neutered Male

**AGE**

11 Years

**WEIGHT**

9.9 lbs

**INTERPRETED BY**

Eric Lindquist, DMV,  
DABVP (CFM), Cert.  
IVUSS

**IMAGING PERFORMED BY**

Shari Reffi, CVT

**HOSPITAL NAME**

Warren Animal  
Hospital

**REFERRING VET**

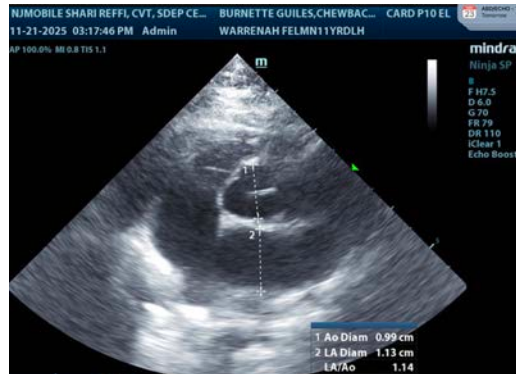Dr. Nicole

**INVOICE**

72042

**DATE**

11/21/25



The information and recommendations provided are based on the images presented by the referring veterinarian/sonographer. No evaluation can be communicated regarding pathology that was not visible in the image/video clips provided.

Thank you for this referral. If the clinical or image interpretation does not parallel your findings or if I can be of any further assistance please contact me.

**Eric Lindquist**, DMV, DABVP(CFM), Cert. IVUSS,  
CEO, Owner, Founder -- SonoPath.com  
[info@SonoPath.com](mailto:info@SonoPath.com)