



PATIENT

Annabelle Brown

SPECIES

Canine

BREED

Beagle x

SEX

Spayed Female

AGE

10 Years

WEIGHT

48.8 lbs

INTERPRETED BY

Eric Lindquist, DMV,
DABVP (CFM), Cert.
IVUS

IMAGING PERFORMED BY

James Hornbuckle,
DVM

HOSPITAL NAME

Golden Isles Animal
Hospital

REFERRING VET

James Hornbuckle,
DVM

INVOICE

72033

DATE

11/21/25

PRESENTING CLINICAL SIGNS

Alkaline Phos. remains elevated and is climbing.
Abnormal PE/Chem/CBC/UA Results: ALP >2,000 Cholesterol 355

ULTRASONOGRAPHIC EXAMINATION OF THE ABDOMEN

Urinary System

The **urinary bladder**, trigone, and pelvic urethra presented normal thicknesses and normal tone. The ureters were not visible which is normal. No uroliths or sediment were visualized and anechoic urine was present. No evidence of inflammatory or neoplastic changes were noted. Ureteral papillae were normal. The pelvic urethra was imaged 2.0 cm beyond the cystourethral junction.

The iliac trifurcation was unremarkable.

The **kidneys** revealed largely normal size and structure, corticomedullary definition and ratio (cortex 1/3 of medulla) were essentially maintained with some age-related loss of curvilinear patterns regarding the capsule and C/M junction. The cortices presented largely uniform texture with some increased echogenicity expected for his age patient. Medullary structure differed distinctly from that of the cortex and no evidence of pelvic dilation was present. The left kidney measured 6.5 cm. The right kidney measured 8.2 cm.

Adrenal Glands

Both **adrenal glands** were visualized and recognized as having normal shape, size, position and echogenicity for this breed. The phrenic vasculature, glandular echogenicity and detail were unremarkable. Capsule, cortex, and medullary definition were normal for this age patient. The left adrenal gland measured 0.80 cm at the caudal pole and 0.70 cm at the cranial pole. The right adrenal gland measured 0.80 cm at the cranial pole and 0.60 cm at the caudal pole.

Spleen

The **spleen** presented a smooth homogeneous parenchyma hyperechoic to liver and renal cortical parenchyma. The capsule was smooth without noticeable expansion or deviation from within the spleen or adjacent pathology. The splenic vasculature demonstrated normal volume without signs of congestion or thrombosis. No sonographic evidence of acute or chronic inflammatory, neoplastic, or infarctual changes were noted.

Liver

The **liver** images from right and left intercostal as well as subcostal views revealed subjectively normal liver size, contour, and structure. Some age-related parenchymal remodeling was noted but likely not clinically significant at this time. Vascular and biliary tracts were of normal volume and no evidence of congestion was noted. The gallbladder presented some dependent debris with essentially normal contour. The cystic and common bile ducts were normal. No overt evidence of active inflammatory, infiltrative or regenerative pathology was noted but should be paired with current or past LE elevations regarding any clinical significance to this presentation. The hepatic lymph nodes were unremarkable.

Gastrointestinal

There was some residual chyme and gas was noted in the **stomach**, yet not pathological. This is consistent with end post prandial presentation. Transit of chyme into the small intestine was normal.



PATIENT

Annabelle Brown

SPECIES

Canine

BREED

Beagle x

SEX

Spayed Female

AGE

10 Years

WEIGHT

48.8 lbs

INTERPRETED BY

Eric Lindquist, DMV,
DABVP (CFM), Cert.
IVUS

IMAGING PERFORMED BY

James Hornbuckle,
DVM

HOSPITAL NAME

Golden Isles Animal
Hospital

REFERRING VET

James Hornbuckle,
DVM

INVOICE

72033

DATE

11/21/25

Curvilinear patterns were maintained throughout the GI tract. No evidence of pathology. Small and large intestine demonstrated normal luminal chyme and stool consistency respectively. No obstructive or overt infiltrative disease was noted. No associated abnormal lymphatic activity was noted.

Pancreas

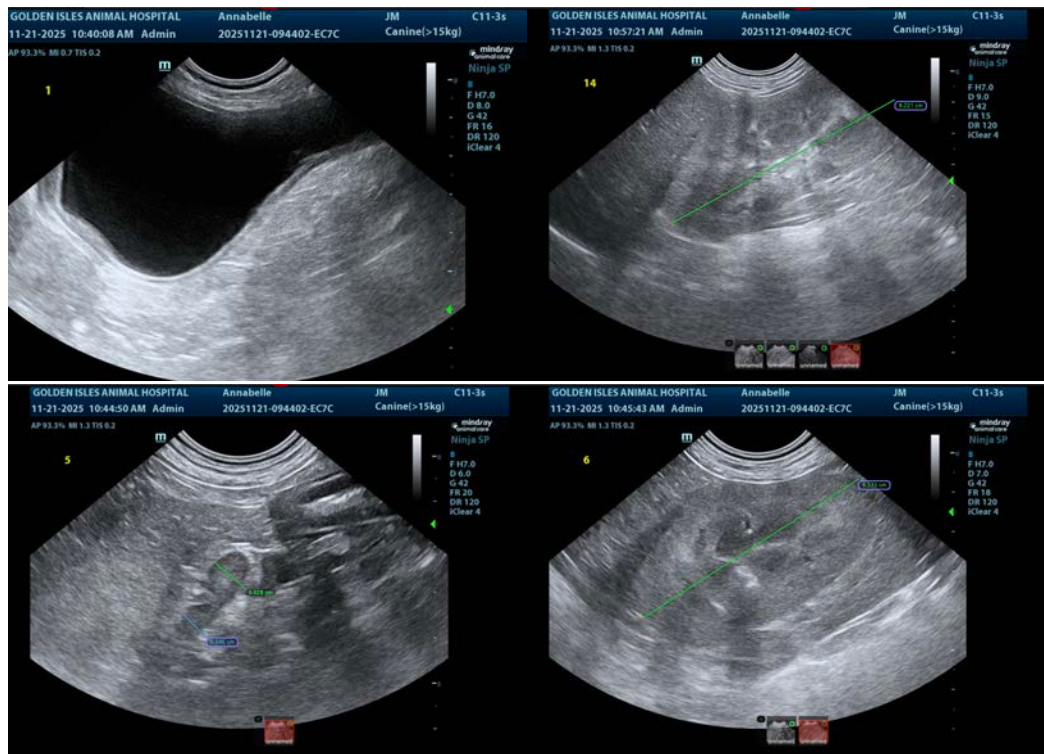
The base and limbs of the **pancreas** were observed to be largely isoechoic to surrounding omental fat. Some parenchymal remodeling, however, with mild deviation from curvilinear normalcy was observed. Pancreatic duct and capsular irregularities were present consistent with age related changes. Slight irregularity noted in the right based with mild enhanced mesentery. If pain upon imaging (+ Murphy sign) was present or if the patient is focally painful in subxyphoid palpation then low-grade smoldering chronic pancreatitis should be suspected.

ULTRASONOGRAPHIC FINDINGS

- Prominent right pancreatic base.
- Benign hepatopathy.
- Age related renal and hepatic changes.
- Partially full stomach.

INTERPRETATION OF THE FINDINGS & FURTHER RECOMMENDATIONS

No evidence of significant disease. However, low-grade pancreatitis is a potential.





PATIENT

Annabelle Brown

SPECIES

Canine

BREED

Beagle x

SEX

Spayed Female

AGE

10 Years

WEIGHT

48.8 lbs

INTERPRETED BY

Eric Lindquist, DMV,
DABVP (CFM), Cert.
IVUSS

IMAGING PERFORMED BY

James Hornbuckle,
DVM

HOSPITAL NAME

Golden Isles Animal
Hospital

REFERRING VET

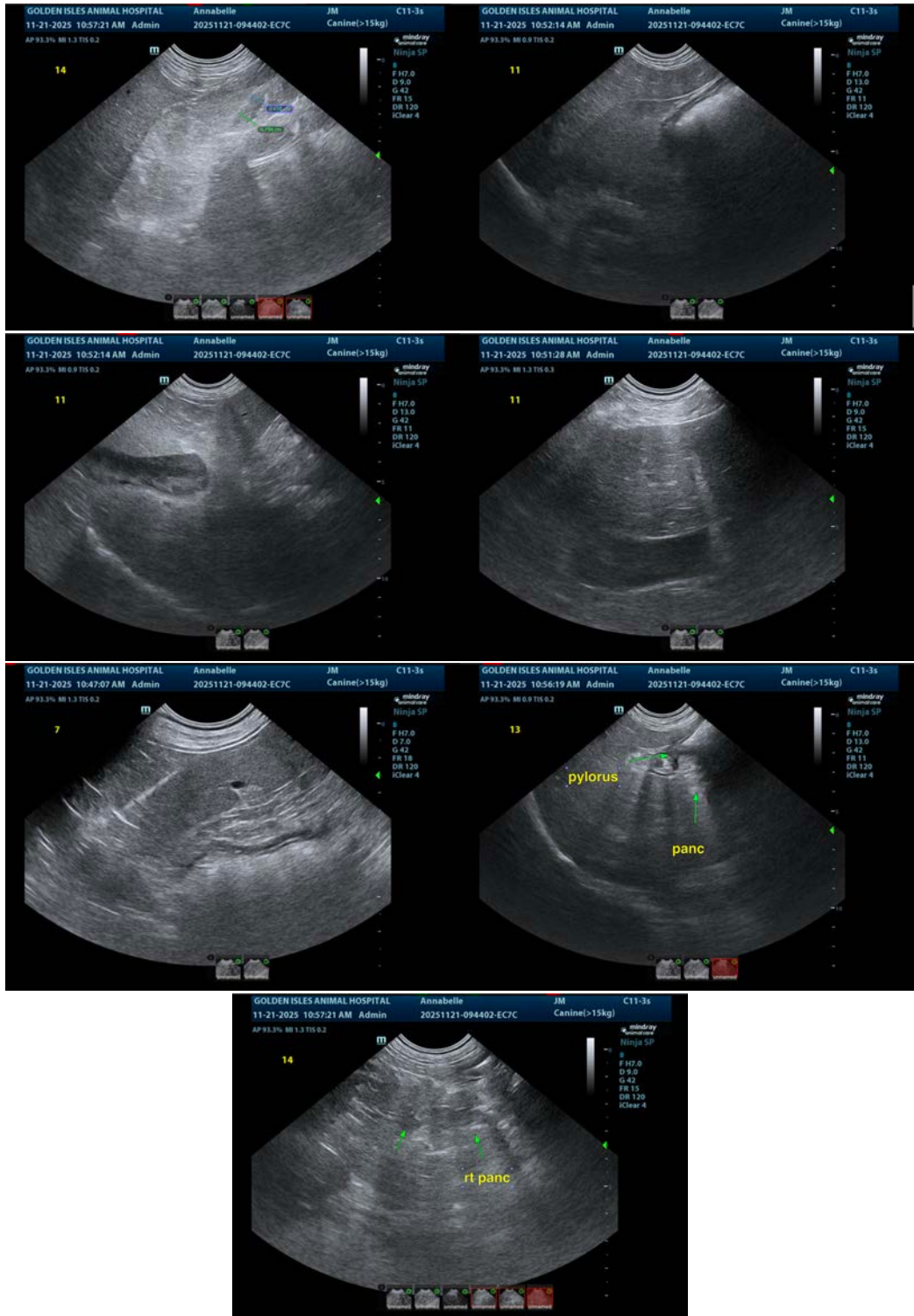
James Hornbuckle,
DVM

INVOICE

72033

DATE

11/21/25





PATIENT

Annabelle Brown

SPECIES

Canine

BREED

Beagle x

SEX

Spayed Female

AGE

10 Years

WEIGHT

48.8 lbs

INTERPRETED BY

Eric Lindquist, DMV,
DABVP (CFM), Cert.
IVUSS

IMAGING PERFORMED BY

James Hornbuckle,
DVM

HOSPITAL NAME

Golden Isles Animal
Hospital

REFERRING VET

James Hornbuckle,
DVM

INVOICE

72033

DATE

11/21/25

The information and recommendations provided are based on the images presented by the referring veterinarian/sonographer. No evaluation can be communicated regarding pathology that was not visible in the image/video clips provided.

Thank you for this referral. If the clinical or image interpretation does not parallel your findings or if I can be of any further assistance please contact me.

Eric Lindquist, DMV, DABVP(CFM), Cert. IVUSS,
CEO, Owner, Founder -- SonoPath.com
info@SonoPath.com