



PATIENT PRESENTING CLINICAL SIGNS

Max Gentile History: Coughing more at home re check - cardiac dz 4/6 HM concern for arrhythmia Current meds Vetmedin 1.25mg BID

SPECIES Abnormal PE/Chem/CBC/UA Results: WNL

Canine **ULTRASONOGRAPHIC EXAMINATION OF THE HEART**

BREED

Chihuahua

SEX

Neutered Male

AGE

10

WEIGHT

11

CANINE CARDIAC PARAMETERS	MR VMAX (m/s)	TR VMAX (m/s)	LA/AO (Boon method)	LA/AO (Heart Base; Swe)	FS (%)	EF (%)	EPSS (cm)
NORMAL PARAMETER	4.5-5.5	<2.7	1.3	<1.3	28-40	40-100	<0.6
PATIENT	--	--	1.5	2.0	--	--	0.1
CANINE CARDIAC PARAMETERS	HR (BPM)	AV VMAX (m/s)	PV MAX (m/s)	BODY WEIGHT (kg)	LA 2D short axis Base view (cm)	LVIDd Avg; 2D and m-mode short axis (cm)	LVIDs Avg; 2D and m-mode short axis (cm)
NORMAL PARAMETER	50-100	0.7-1.7	0.7-1.6				
PATIENT	--	1.50	1.14	--	3.3	--	--

INTERPRETED BY

Eric Lindquist, DMV DABVP, Cert. IVUSS

IMAGING PERFORMED BY

Jenn

HOSPITAL NAME

Rockaway AH

REFERRING VET

Dr. Ascot

INVOICE

18157

DATE

11/21/22

Cardiac Presentation

The cardiac presentation presented mild to moderate volume overload of the left atrium and left ventricle with adequate compensatory contractility. Prolapse of the anterior mitral valve leaflet was noted. No pericardial or pleural effusion was noted. The right atrium and right ventricle were unremarkable. Tricuspid insufficiency was noted, compensated. No evidence of passive congestion noted. Occasional arrhythmia was noted.

ULTRASONOGRAPHIC FINDINGS

- Left atrial size is mildly excessive
- Tricuspid insufficiency
- Occasional arrhythmia

INTERPRETATION OF THE FINDINGS & FURTHER RECOMMENDATIONS

The cough in this patient could be cardiogenic depending upon radiographic findings. A low dose Lasix trial at 1-2 mg/kg BID, ace-inhibitor at 0.5 mg/kg SID progressing to BID, reassessment of the clinical signs and radiographs over the next 7-10 days, and EKG is indicated based on the arrhythmogenic activity. Recheck echo in 3-6 months depending upon the clinical progression. However, primary respiratory component may also be playing a role in this patient depending on radiographic findings.



PATIENT

Max Gentile

SPECIES

Canine

BREED

Chihuahua

SEX

Neutered Male

AGE

10

WEIGHT

11

INTERPRETED BY

Eric Lindquist, DMV
DABVP, Cert. IVUSS

IMAGING PERFORMED BY

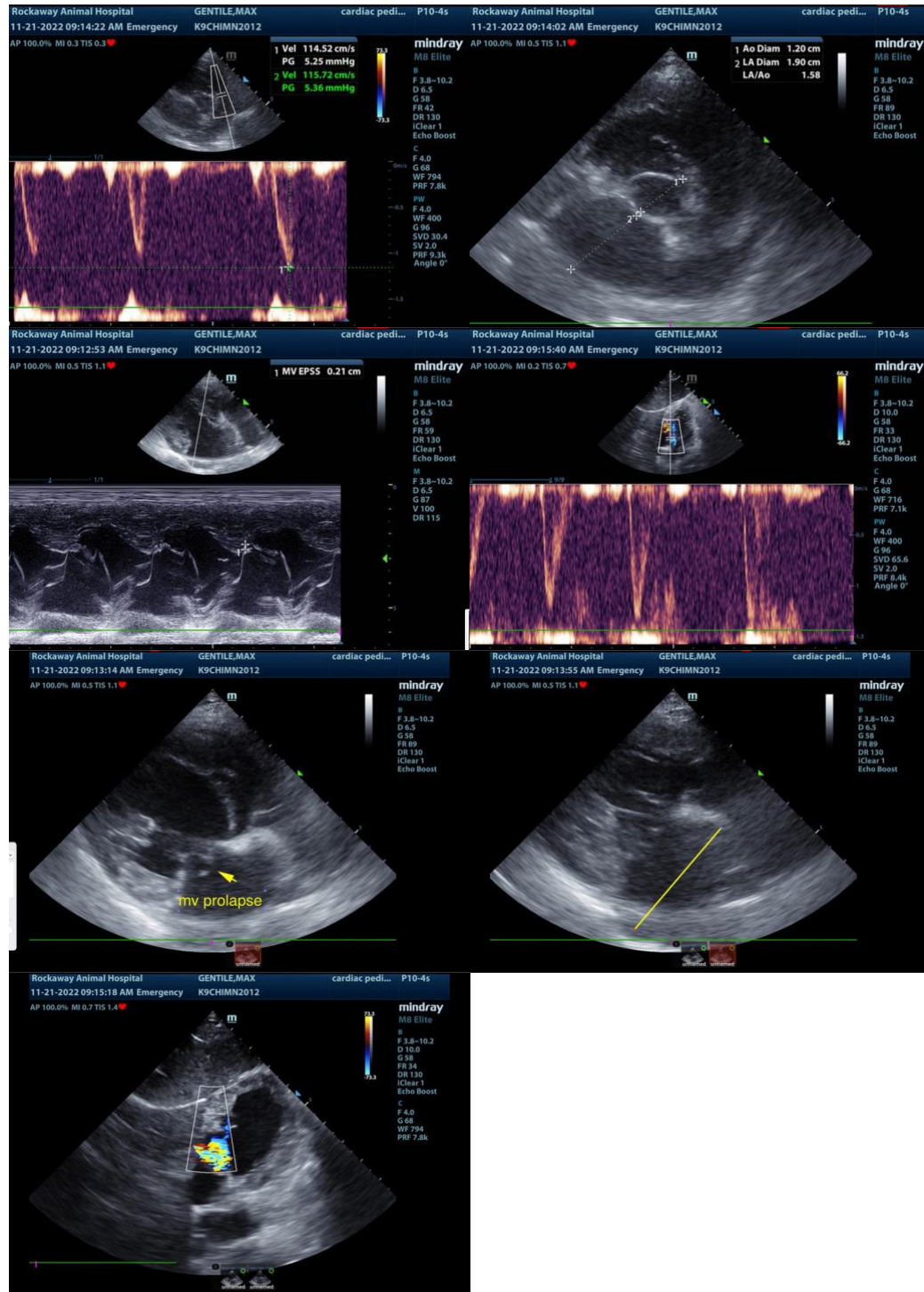
Jenn

HOSPITAL NAME

Rockaway AH

REFERRING VET

Dr. Ascot



INVOICE

18157

DATE

11/21/22

The information and recommendations provided are based on the images presented by the referring veterinarian. No evaluation can be communicated regarding pathology that was not visible in the image/video clips provided.

Thank you for this referral. If the clinical or image interpretation does not parallel your findings or if I can be of any further assistance please contact me.



PATIENT

Max Gentile

Eric Lindquist, DMV, DABVP, Cert. IVUSS, CEO of SonoPath.com
info@SonoPath.com

SPECIES

Canine

BREED

Chihuahua

SEX

Neutered Male

AGE

10

WEIGHT

11

INTERPRETED BY

Eric Lindquist, DMV
DABVP, Cert. IVUSS

**IMAGING
PERFORMED BY**

Jenn

HOSPITAL NAME

Rockaway AH

REFERRING VET

Dr. Ascot

INVOICE

18157

DATE

11/21/22