



PATIENT PRESENTING CLINICAL SIGNS

Louie Natale History: presents for poss seizure activity

SPECIES ULTRASONOGRAPHIC EXAMINATION OF THE HEART & ABDOMEN

Canine

BREED

Shih Tzu

SEX

Neutered Male

AGE

2 Years

WEIGHT

7 Pounds

CANINE CARDIAC PARAMETERS	MR VMAX (m/s)	TR VMAX (m/s)	LA/AO (Boon method)	LA/AO (Heart Base; Swe)	FS (%)	EF (%)	EPSS (cm)
NORMAL PARAMETER	4.5-5.5	<2.7	1.3	<1.3	28-40	40-100	<0.6
PATIENT	--	--	1.0	1.0	45	90	0.1
CANINE CARDIAC PARAMETERS	HR (BPM)	AV VMAX (m/s)	PV MAX (m/s)	BODY WEIGHT (kg)	LA 2D short axis Base view (cm)	LVIDd Avg; 2D and m-mode short axis (cm)	LVIDs Avg; 2D and m-mode short axis (cm)
NORMAL PARAMETER	50-100	0.7-1.7	0.7-1.6				
PATIENT	--	1.00	.60	--	2.0	1.5	--

Cardiac Presentation

The echocardiogram in this patient demonstrated normal **left atrial** size based on 3 separate methods of LA evaluation. The cranial and caudal **mitral** valve leaflets presented normal linear structure, extension in systole, and union in diastole with normal kinesis. The **left ventricle** presented normal thicknesses with linear contour and was not dilated nor restricted. The **myocardium** presented normal echogenicity without subjective evidence of significant fibrotic or ischemic disease. **Contractility** of the ventricular walls was adequate and in normal range for this patient evidenced by the fractional shortening measurement and subjective evaluation of the different regions of the myocardium. The **left ventricular outflow** tract demonstrated normal laminar flow and subjective structural integrity. The **right atrium** and auricle revealed normal size, structure and content. No evidence of masses was noted. **Tricuspid** valvular assessment demonstrated adequate linear morphology and kinesis. The **right ventricle** was of normal size (1/3 diameter of LV), chordae structure, myocardial echogenicity and thickness. **Pulmonary outflow** tract assessment revealed normal valve structure, laminar flow, and diameter (approx.1:1 pa/ao ratio). No visible **pericardial** or free pleura fluid was noted. The cranial **mediastinum and pericardial and extra-cardiac regions** were free of masses in the visible window.

Urinary System

The **urinary bladder**, trigone, and pelvic urethra presented normal thicknesses and normal tone. The ureters were not visible which is normal. No uroliths or sediment were visualized and anechoic urine was present. No evidence of inflammatory or neoplastic changes were noted. Ureteral papillae were normal.

INTERPRETED BY

Eric Lindquist, DMV DABVP, Cert. IVUSS

IMAGING PERFORMED BY

Jenn

HOSPITAL NAME

Rockaway AH

REFERRING VET

Dr. Maniar

INVOICE

18154

DATE

11/21/22



PATIENT

Louie Natale

The **kidneys** were normal in size and contour with idiopathic hyperechoic medullary rim sign. This is common for the breed; however, some level of primary renal dysplasia may be an issue. The left kidney measured 3.1 cm. The right kidney measured 2.65 cm.

SPECIES

Canine

Adrenal Glands

Both **adrenal glands** were visualized and recognized as having normal shape, size, position and echogenicity for this breed. The phrenic vasculature, glandular echogenicity and detail were unremarkable. Capsule, cortex, and medullary definition were normal for this age patient. The right adrenal gland measured 1.2 cm x 0.42 cm at the caudal pole and 0.46 cm at the cranial pole. The right adrenal gland measured 1.12 cm x 0.33 cm at the caudal pole and 0.37 cm at the cranial pole.

BREED

Shih Tzu

Spleen

The **spleen** presented a smooth homogeneous parenchyma hyperechoic to liver and renal cortical parenchyma. The capsule was smooth without noticeable expansion or deviation from within the spleen or adjacent pathology. The splenic vasculature demonstrated normal volume without signs of congestion or thrombosis. No sonographic evidence of acute or chronic inflammatory, neoplastic, or infarctual changes were noted.

SEX

Neutered Male

AGE

2 Years

Liver

The **liver** was mildly subnormal in size. No overt portosystemic shunting was noted, however, bile acid profile is warranted. The gallbladder and common bile duct were unremarkable.

WEIGHT

7 Pounds

Gastrointestinal

There was some residual chyme and gas was noted in the **stomach**, yet not pathological. This is consistent with end post prandial presentation. Transit of chyme into the small intestine was normal. Curvilinear patterns were maintained throughout the GI tract. No evidence of pathology. Small and large intestine demonstrated normal luminal chyme and stool consistency respectively. No obstructive or overt infiltrative disease was noted. No associated abnormal lymphatic activity was noted.

INTERPRETED BY

Eric Lindquist, DMV
DABVP, Cert. IVUSS

IMAGING PERFORMED BY

Jenn

HOSPITAL NAME

Rockaway AH

Pancreas

The base and limbs of the **pancreas** were observed to be largely isoechoic to surrounding omental fat. Pancreatic duct and capsular contour were acceptably normal and parenchyma respected normal curvilinear patterns. No overt evidence of active inflammatory or neoplastic disease was noted.

ULTRASONOGRAPHIC FINDINGS

REFERRING VET

Dr. Maniar

- Normal echocardiogram- no evidence of pathology
- Idiopathic medullary rim kidney, likely a normal variant, possibility of minor form of renal dysplasia
- Partially full stomach
- Mildly subnormal liver size

INVOICE

18154

INTERPRETATION OF THE FINDINGS & FURTHER RECOMMENDATIONS

If bile acids are elevated, then abdominal CT would be ideal to rule out portosystemic shunting. Brain CT is indicated.

DATE

11/21/22

ABOUT SONOPATH CT SERVICES:



PATIENT

Louie Natale

SPECIES

Canine

BREED

Shih Tzu

SEX

Neutered Male

AGE

2 Years

WEIGHT

7 Pounds

INTERPRETED BY

Eric Lindquist, DMV
DABVP, Cert. IVUSS

IMAGING PERFORMED BY

Jenn

HOSPITAL NAME

Rockaway AH

REFERRING VET

Dr. Maniar

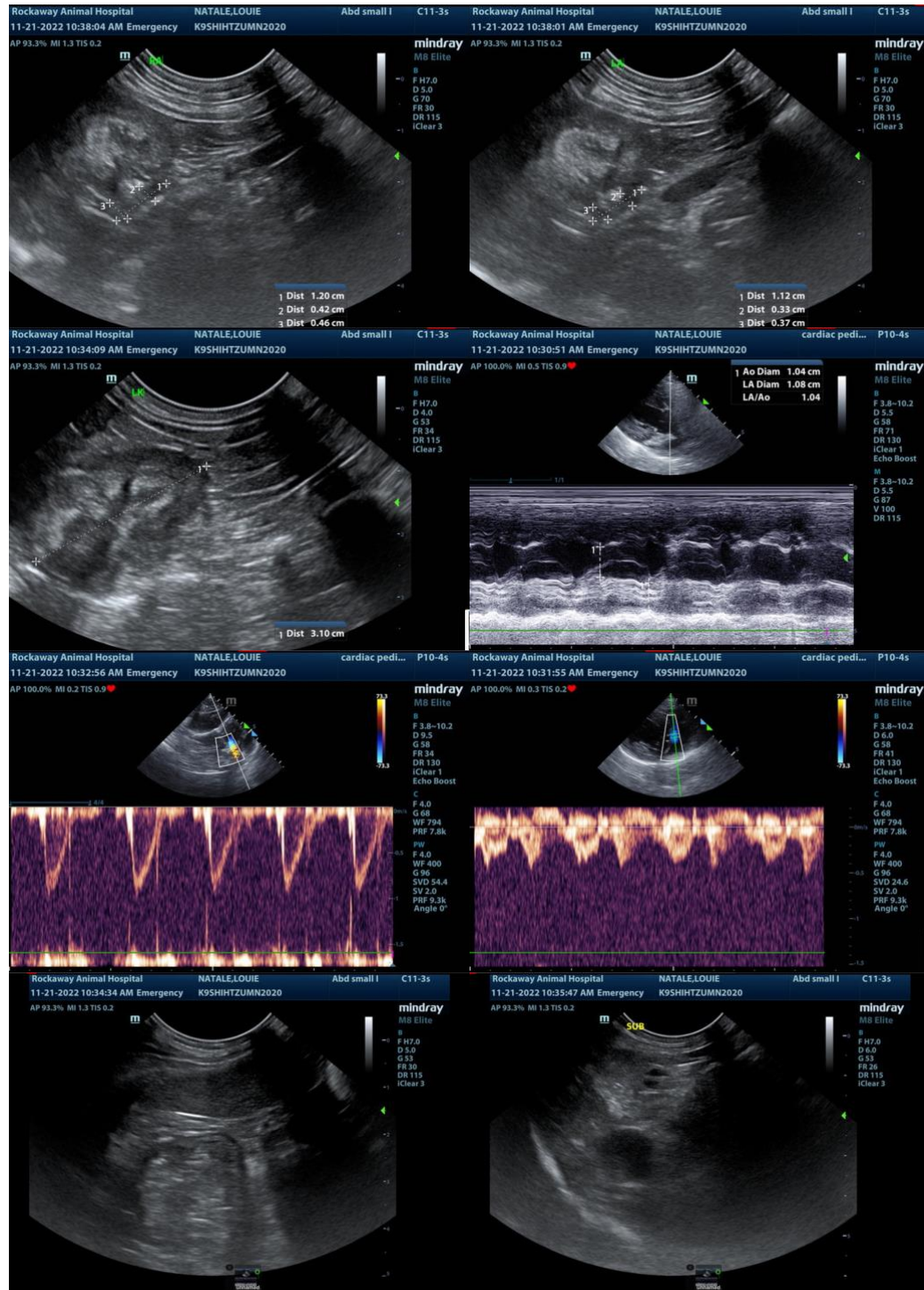
INVOICE

18154

DATE

11/21/22

SonoPath CT Services are offered at the SonoPath Imaging and Veterinary Education Center, 141 Main St (rt 206), Andover, New Jersey, a 20-minute drive west on route 80/206 North from the route 80/287 interchange/Parsippany, New Jersey. More information can be found at <https://sonopath.com/resources/sonopaths-teleconsultation-services-and-sdep-certification/sonopath-ct-services>





PATIENT

Louie Natale

The information and recommendations provided are based on the images presented by the referring veterinarian. No evaluation can be communicated regarding pathology that was not visible in the image/video clips provided.

SPECIES

Canine

Thank you for this referral. If the clinical or image interpretation does not parallel your findings or if I can be of any further assistance please contact me.

BREED

Shih Tzu

Eric Lindquist, DMV, DABVP, Cert. IVUSS, CEO of SonoPath.com
info@SonoPath.com

SEX

Neutered Male

AGE

2 Years

WEIGHT

7 Pounds

INTERPRETED BY

Eric Lindquist, DMV
DABVP, Cert. IVUSS

**IMAGING
PERFORMED BY**

Jenn

HOSPITAL NAME

Rockaway AH

REFERRING VET

Dr. Maniar

INVOICE

18154

DATE

11/21/22