

PATIENT

Charlotte Ferrara

SPECIES

Canine

BREED

Cockapoo

SEX

Spayed female

AGE

7 years

WEIGHT

23 lbs

INTERPRETED BY

Eric Lindquist, DMV
DABVP, Cert. IVUSS

IMAGING PERFORMED BY

Dr. Ammeraal

HOSPITAL NAME

Sova

REFERRING VET

Dr. Ammeraal

INVOICE

42619

DATE

11/21/22

PRESENTING CLINICAL SIGNS

History: Overall doing well at home.

Abnormal PE/Chem/CBC/UA Results: Exam overall normal, UA free Catch USG 1.048 RBC 21-50 HPF, WBC 2-3, Triphos Crystals- 4-10 HPF

ULTRASONOGRAPHIC EXAMINATION OF THE ABDOMEN

Urinary System

The **urinary bladder** presented a minimal amount of urine. Prominent, right ureteral papilla was noted, yet not overtly pathological. The pelvic urethra was imaged 3.0 cm beyond the cystourethral junction and appeared normal.

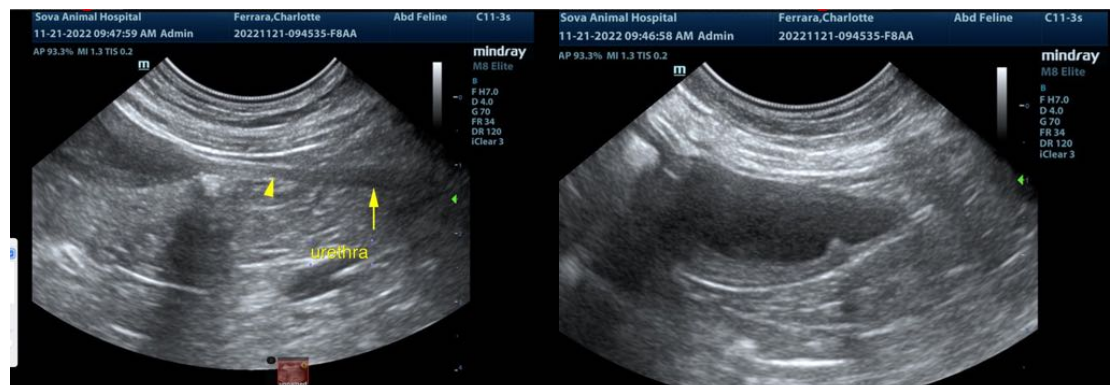
The **kidneys** revealed normal size and structure, corticomedullary definition and ratio for this age. The cortices presented largely uniform texture with normal echogenic relationship to liver and spleen. Medullary structure differed distinctly from the cortex and no evidence of pelvic dilation was present. The capsules were acceptably uniform without significant irregularities. The right kidney measured 4.95 cm. The left kidney measured 4.51 cm.

ULTRASONOGRAPHIC FINDINGS

Prominent, right ureteral papilla; otherwise, structurally unremarkable urinary tract.

INTERPRETATION OF THE FINDINGS & FURTHER RECOMMENDATIONS

Occult UTI, idiopathic hematuria and coagulopathy are all possible; however, structurally the urinary tract was unremarkable.





PATIENT

Charlotte Ferrara

SPECIES

Canine

BREED

Cockapoo

SEX

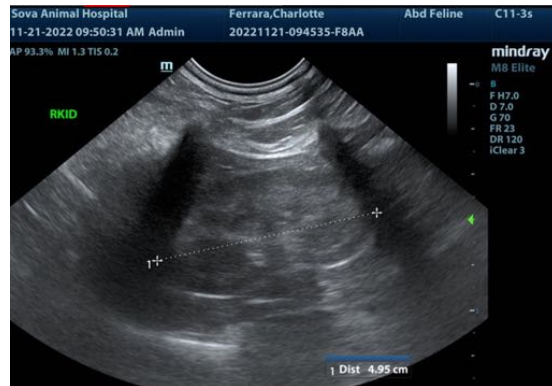Spayed female

AGE

7 years

WEIGHT

23 lbs



The information and recommendations provided are based on the images presented by the referring veterinarian/sonographer. No evaluation can be communicated regarding pathology that was not visible in the image/video clips provided.

Thank you for this referral. If the clinical or image interpretation does not parallel your findings or if I can be of any further assistance please contact me.

Eric Lindquist, DMV, DABVP, Cert. IVUSS, CEO of SonoPath.com
info@SonoPath.com

INTERPRETED BY

Eric Lindquist, DMV
DABVP, Cert. IVUSS

IMAGING PERFORMED BY

Dr. Ammeraal

HOSPITAL NAME

Sova

REFERRING VET

Dr. Ammeraal

INVOICE

42619

DATE

11/21/22