



PATIENT

Benny Carrasquillo

PRESENTING CLINICAL SIGNS

History: acute onset resp distress Hx of Cushings lethargic

SPECIES

Canine

ULTRASONOGRAPHIC EXAMINATION OF THE HEART & ABDOMEN

BREED

Shih Tzu

SEX

Neutered Male

AGE

11

WEIGHT

16.6

CANINE CARDIAC PARAMETERS	MR VMAX (m/s)	TR VMAX (m/s)	LA/AO (Boon method)	LA/AO (Heart Base; Swe)	FS (%)	EF (%)	EPSS (cm)
NORMAL PARAMETER	4.5-5.5	<2.7	1.3	<1.3	28-40	40-100	<0.6
PATIENT	--	--	1.0	1.23	60	98	0.1
CANINE CARDIAC PARAMETERS	HR (BPM)	AV VMAX (m/s)	PV MAX (m/s)	BODY WEIGHT (kg)	LA 2D short axis Base view (cm)	LVIDd Avg; 2D and m-mode short axis (cm)	LVIDs Avg; 2D and m-mode short axis (cm)
NORMAL PARAMETER	50-100	0.7-1.7	0.7-1.6				
PATIENT	--	1.14	.60	--	2.5	1.7	--

INTERPRETED BY

Eric Lindquist, DMV DABVP, Cert. IVUSS

IMAGING PERFORMED BY

Jenn

HOSPITAL NAME

Rockaway AH

REFERRING VET

Dr. Maniar

INVOICE

18155

DATE

11/21/22

Cardiac Presentation

The echocardiogram in this patient demonstrated normal **left atrial** size based on 3 separate methods of LA evaluation. The cranial and caudal **mitral** valve leaflets presented normal linear structure, extension in systole, and union in diastole with normal kinesis. The **left ventricle** presented normal thicknesses with linear contour and was not dilated nor restricted. The **myocardium** presented normal echogenicity without subjective evidence of significant fibrotic or ischemic disease. **Contractility** of the ventricular walls was adequate and in normal range for this patient evidenced by the fractional shortening measurement and subjective evaluation of the different regions of the myocardium. The **left ventricular outflow** tract demonstrated normal laminar flow and subjective structural integrity. The **right atrium** and auricle revealed normal size, structure and content. No evidence of masses was noted. **Tricuspid** valvular assessment demonstrated adequate linear morphology and kinesis. The **right ventricle** was of normal size (1/3 diameter of LV), chordae structure, myocardial echogenicity and thickness. **Pulmonary outflow** tract assessment revealed normal valve structure, laminar flow, and diameter (approx.1:1 pa/ao ratio). No visible **pericardial** or free pleura fluid was noted. The cranial **mediastinum and pericardial and extra-cardiac regions** were free of masses in the visible window.

Urinary System

The **urinary bladder** revealed sand accumulation, a grouping of which measured 2.5 cm. The urethra presented sand accumulation, nonobstructive at the time of the sonogram.

The **kidneys** revealed largely normal size and structure, corticomedullary definition and ratio (cortex 1/3 of medulla) were essentially maintained with some moderate age-related loss of curvilinear



PATIENT	patterns regarding the capsule and C/M junction. The cortices presented largely uniform texture with some increased echogenicity expected for his age patient. Medullary structure differed distinctly from that of the cortex and no evidence of pelvic dilation was present. Mineralization was noted in the kidneys. The right kidney measured 5.16 cm. The left kidney measured 4.88 cm.
Benny Carrasquillo	
SPECIES	Adrenal Glands
Canine	The left adrenal gland was slightly swollen at the caudal pole. The left adrenal gland measured 5.0 mm at the cranial pole and 7.0 mm at the caudal pole.
BREED	Spleen
Shih Tzu	The spleen was largely smooth with subtle heterogeneous parenchymal changes while maintaining normal echogenic relationship to the liver and kidney. These changes are consistent with normal age-related alteration. The capsule was smooth without noticeable impingement from within the spleen or from pathology in the adjacent abdomen. The splenic vasculature demonstrated normal volume without signs of congestion or significant contraction. No evidence of active acute or chronic inflammatory, neoplastic, or infarctual changes were noted. This is a minor change.
SEX	Liver
Neutered Male	The liver images from right and left intercostal as well as subcostal views revealed subjectively normal liver size, contour, and structure. Some mild age-related parenchymal remodeling was noted but likely not clinically significant at this time. Vascular and biliary tracts were of normal volume and no evidence of congestion was noted. The gallbladder presented some dependent debris with essentially normal contour. The cystic and common bile ducts were normal. Occasional hypoechoic nodule noted. The caudal lung field revealed a shower curtain lung indicative of alveolar disease, however, this is noncardiogenic.
AGE	Gastrointestinal
11	Some retention of ingesta was noted in the stomach . The pylorus revealed mucosal hypertrophy and remodeling, this may be causing a delayed outflow issue. The small intestine and colon were unremarkable.
WEIGHT	Pancreas
16.6	The base and limbs of the pancreas were observed to be largely isoechoic to surrounding omental fat. Pancreatic duct and capsular contour were acceptably normal and parenchyma respected normal curvilinear patterns. No overt evidence of active inflammatory or neoplastic disease was noted.
INTERPRETED BY	ULTRASONOGRAPHIC FINDINGS
Eric Lindquist, DMV DABVP, Cert. IVUSS	<ul style="list-style-type: none"> • Normal echocardiogram- no evidence of primary disease • Noncardiogenic pulmonary edema pattern • Bladder and urethral sand • Age-related renal changes with mineralization, the patient is likely passing calculi periodically • Age-related splenic changes • Slightly swollen left adrenal gland • Retention of ingesta in the stomach with pyloric mucosal hypertrophy and remodeling
IMAGING PERFORMED BY	INTERPRETATION OF THE FINDINGS & FURTHER RECOMMENDATIONS
Jenn	
HOSPITAL NAME	
Rockaway AH	
REFERRING VET	
Dr. Maniar	
INVOICE	
18155	
DATE	
11/21/22	



PATIENT

Benny Carrasquillo

Primary respiratory therapy is indicated. Thromboembolic disease, pneumonitis, SARDS all possible. Consideration for potential pulmonary thromboembolic disease, depending upon the radiographic findings. Chest CT would be ideal for further definition. Lung neoplasia is also a remote potential.

SPECIES

Canine

ABOUT SONOPATH CT SERVICES:

SonoPath CT Services are offered at the SonoPath Imaging and Veterinary Education Center, 141 Main St (rt 206), Andover, New Jersey, a 20-minute drive west on route 80/206 North from the route 80/287 interchange/Parsippany, New Jersey. More information can be found at <https://sonopath.com/resources/sonopaths-teleconsultation-services-and-sdep-certification/sonopath-ct-services>

BREED

Shih Tzu

SEX

Neutered Male

AGE

11

WEIGHT

16.6

INTERPRETED BY

Eric Lindquist, DMV
DABVP, Cert. IVUSS

IMAGING PERFORMED BY

Jenn

HOSPITAL NAME

Rockaway AH

REFERRING VET

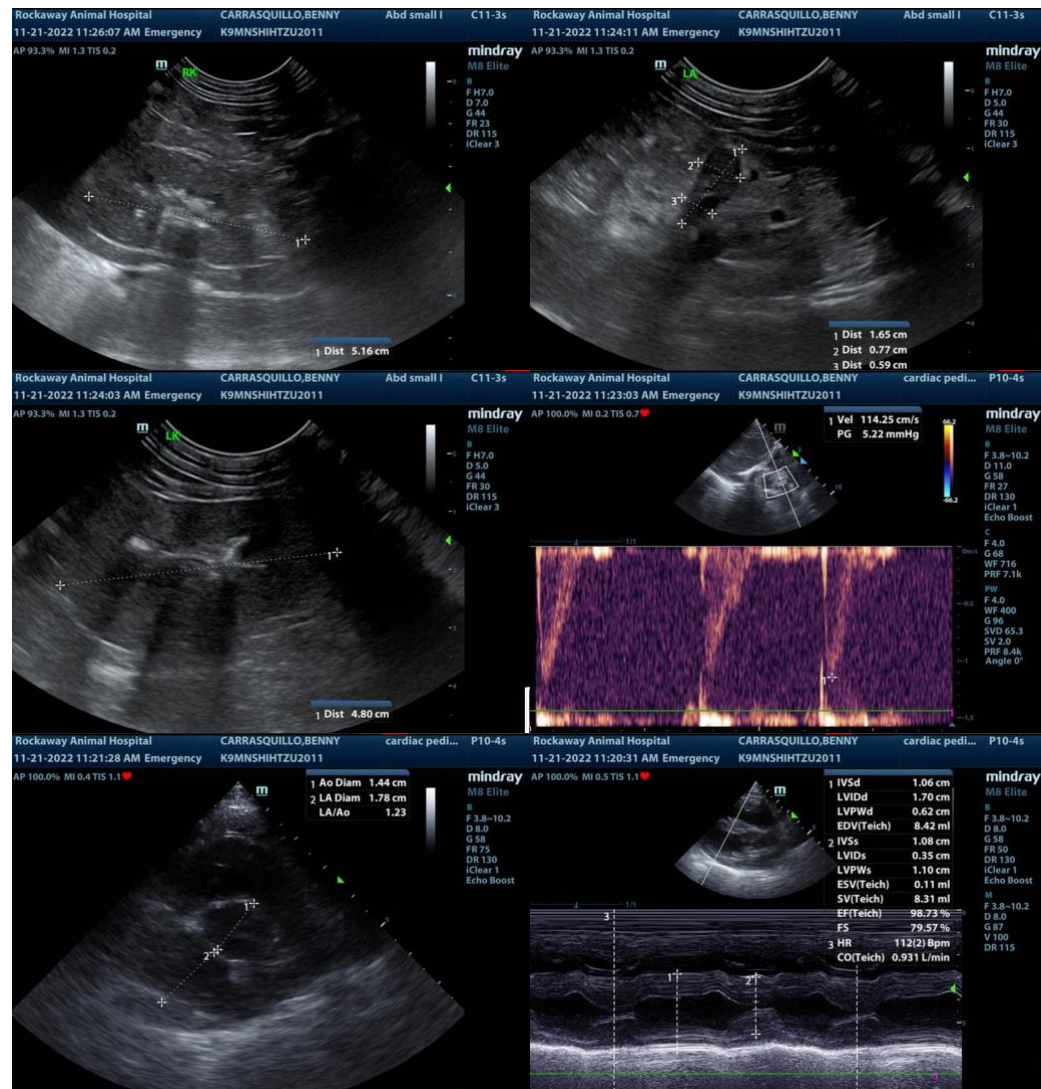
Dr. Maniar

INVOICE

18155

DATE

11/21/22





PATIENT

Benny Carrasquillo

SPECIES

Canine

BREED

Shih Tzu

SEX

Neutered Male

AGE

11

WEIGHT

16.6

INTERPRETED BY

Eric Lindquist, DMV
DABVP, Cert. IVUSS

IMAGING PERFORMED BY

Jenn

HOSPITAL NAME

Rockaway AH

REFERRING VET

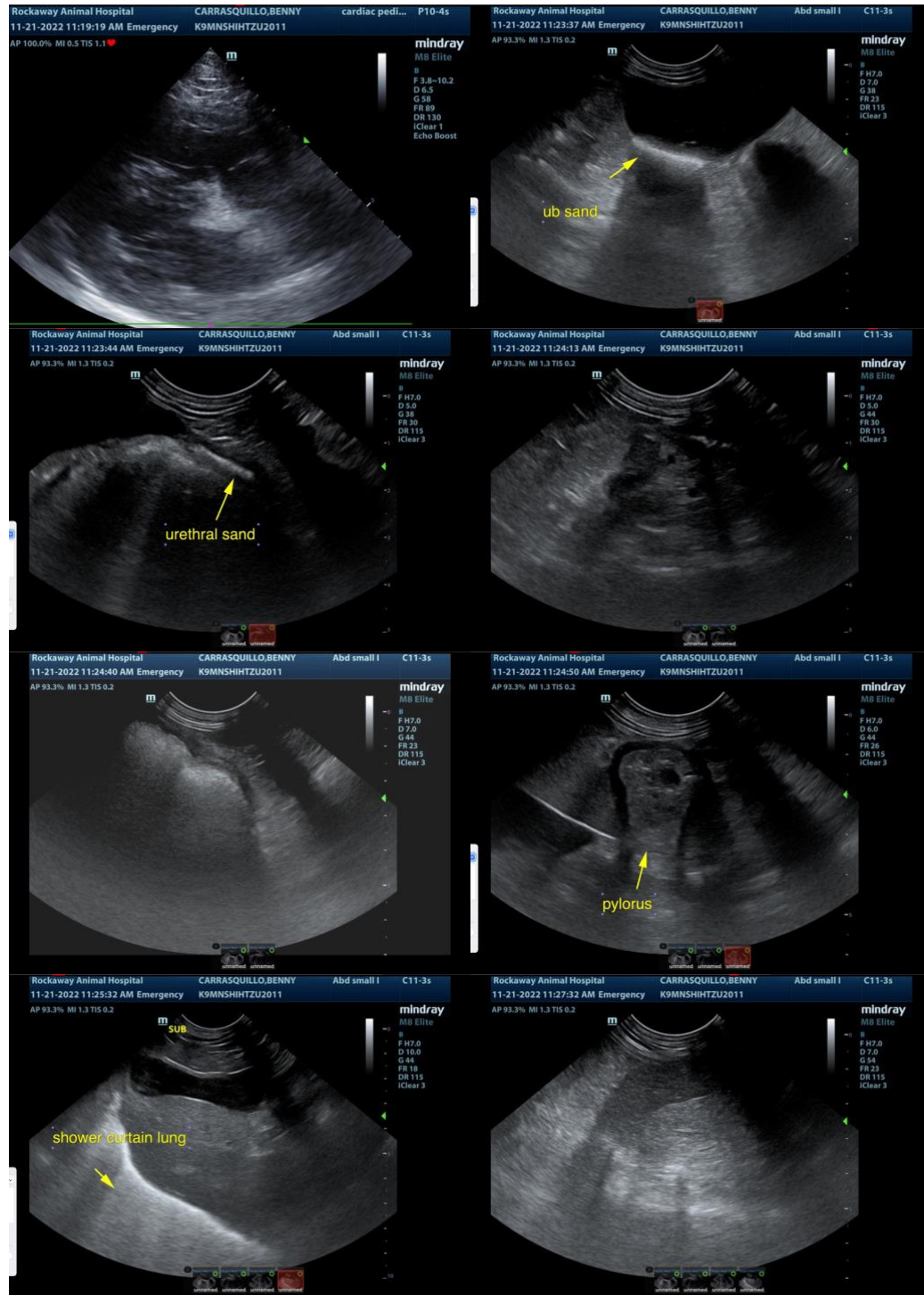
Dr. Maniar

INVOICE

18155

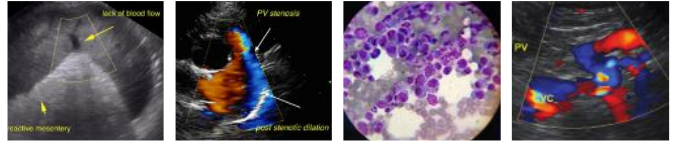
DATE

11/21/22



The information and recommendations provided are based on the images presented by the referring veterinarian. No evaluation can be communicated regarding pathology that was not visible in the image/video clips provided.

Thank you for this referral. If the clinical or image interpretation does not parallel your findings or if I can be of any further assistance please contact me.



PATIENT

Benny Carrasquillo

Eric Lindquist, DMV, DABVP, Cert. IVUSS, CEO of SonoPath.com
info@SonoPath.com

SPECIES

Canine

BREED

Shih Tzu

SEX

Neutered Male

AGE

11

WEIGHT

16.6

INTERPRETED BY

Eric Lindquist, DMV
DABVP, Cert. IVUSS

**IMAGING
PERFORMED BY**

Jenn

HOSPITAL NAME

Rockaway AH

REFERRING VET

Dr. Maniar

INVOICE

18155

DATE

11/21/22