



PATIENT

Lola Cox

SPECIES

Canine

BREED

Jack Russell Terrier
Mix

SEX

Spayed female

AGE

13 years

WEIGHT

18.3 lbs

INTERPRETED BY

Eric Lindquist, DMV
DABVP, Cert. IVUSS

IMAGING PERFORMED BY

Dr. Wolfe

HOSPITAL NAME

HomeVets

REFERRING VET

Dr. Wolfe

INVOICE

68929

DATE

11/20/25

PRESENTING CLINICAL SIGNS

History: P presents for abd US for persistent nucleated RBCs on CBC and elevated ALP. Has a hx of weight gain, but recently has had weight loss since starting hill's r/d.

Abnormal PE/Chem/CBC/UA Results: Mild abdominal distension. Increased nucleated RBCs 4/100wbcs thrombocytosis 425 mild ALP elevation 194, other liver values normal USG 1.032 UPC 0.3

ULTRASONOGRAPHIC EXAMINATION OF THE ABDOMEN

Urinary System

The **urinary bladder**, trigone, and pelvic urethra presented normal thicknesses and normal tone. The ureters were not visible which is normal. No uroliths or sediment were visualized and anechoic urine was present. No evidence of inflammatory or neoplastic changes was noted. Ureteral papillae were normal.

The **kidneys** revealed largely normal size and structure, corticomedullary definition and ratio (cortex 1/3 of medulla) were essentially maintained with some age-related loss of curvilinear patterns regarding the capsule and C/M junction. The cortices presented largely uniform texture with some increased echogenicity expected for this age patient. Medullary structure differed distinctly from that of the cortex and no evidence of pelvic dilation was present. Slight mineralization was noted in the kidneys. Minor microcytic cortical changes were noted. The left kidney measured 4.5 cm. The right kidney measured 4.0 cm.

Adrenal Glands

Both **adrenal glands** were visualized and recognized as having normal shape, size, position and echogenicity for this breed. The phrenic vasculature, glandular echogenicity and detail were unremarkable. Capsule, cortex, and medullary definition were normal for this age patient. The left adrenal gland measured 0.55 cm at the caudal pole and 0.4 cm at the cranial pole. The right adrenal gland measured 0.95 cm at the cranial pole and 0.53 cm at the caudal pole. .

Spleen

The **spleen** presented a smooth homogeneous parenchyma hyperechoic to liver and renal cortical parenchyma. The capsule was smooth without noticeable expansion or deviation from within the spleen or adjacent pathology. The splenic vasculature demonstrated normal volume without signs of congestion or thrombosis. No sonographic evidence of acute or chronic inflammatory, neoplastic, or infarctual changes was noted.

Liver

The **liver** was uniformly swollen with minor, excessive gallbladder debris and over distension with dependent and suspended bile without evidence of overt mucocele formation. However, excessive sludge was present. The liver presented coarse architecture with mildly increased portal markings and



PATIENT

Lola Cox

SPECIES

Canine

BREED

Jack Russell Terrier
Mix

SEX

Spayed female

AGE

13 years

WEIGHT

18.3 lbs

INTERPRETED BY

Eric Lindquist, DMV
DABVP, Cert. IVUS

IMAGING PERFORMED BY

Dr. Wolfe

HOSPITAL NAME

HomeVets

REFERRING VET

Dr. Wolfe

INVOICE

68929

DATE

11/20/25

subtle, mixed echogenic changes. This is consistent with vacuolar hepatopathy and some level of remodeling and history of inflammatory component. There was no overt suspicion of neoplasia.

Gastrointestinal

Examination of the **gastrointestinal tract** revealed a stomach and intestine free of stasis, of normal wall thickness, acceptable curvilinear mural detail, and peristaltic activity. Small and large intestine demonstrated normal luminal chyme and stool consistency respectively. No obstructive or overt infiltrative disease was noted. No associated abnormal lymphatic activity was noted.

Pancreas

The base and limbs of the **pancreas** were observed to be largely isoechoic to surrounding omental fat. Pancreatic duct and capsular contour were acceptably normal and parenchyma respected normal curvilinear patterns. No overt evidence of active inflammatory or neoplastic disease was noted.

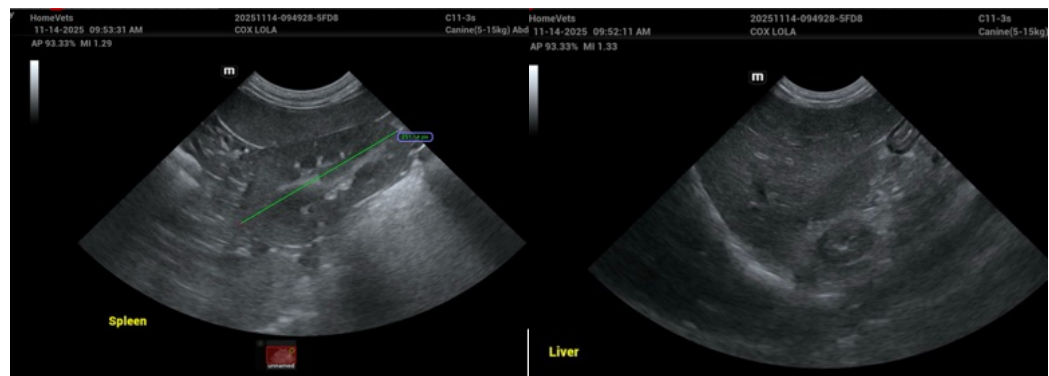
ULTRASONOGRAPHIC FINDINGS

Structurally unremarkable abdomen.

Benign hepatopathy.

INTERPRETATION OF THE FINDINGS & FURTHER RECOMMENDATIONS

There was no evident cause of weight loss.





PATIENT

Lola Cox

SPECIES

Canine

BREED

Jack Russell Terrier
Mix

SEX

Spayed female

AGE

13 years

WEIGHT

18.3 lbs

INTERPRETED BY

Eric Lindquist, DMV
DABVP, Cert. IVUSS

**IMAGING
PERFORMED BY**

Dr. Wolfe

HOSPITAL NAME

HomeVets

REFERRING VET

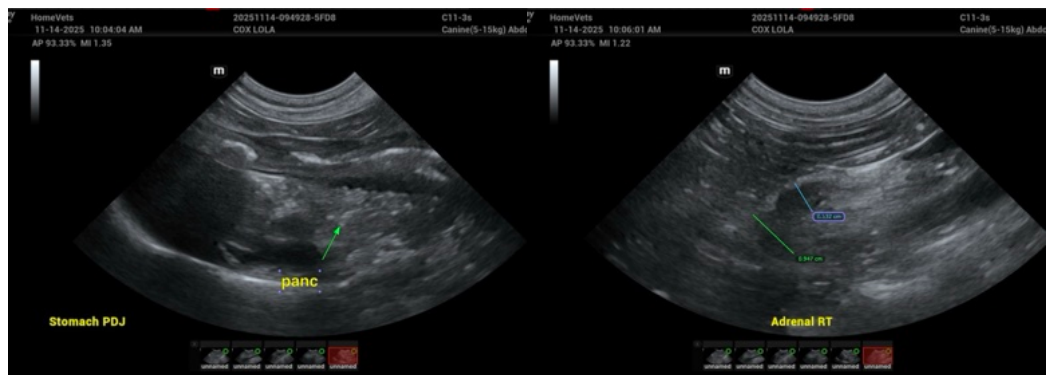
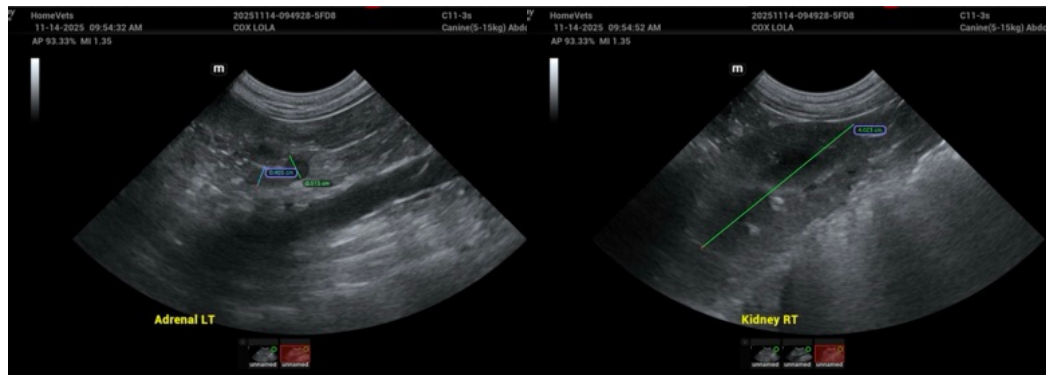
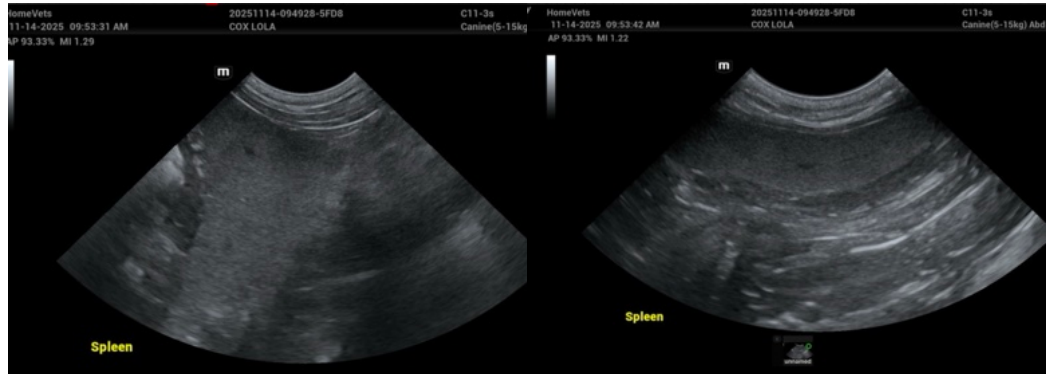
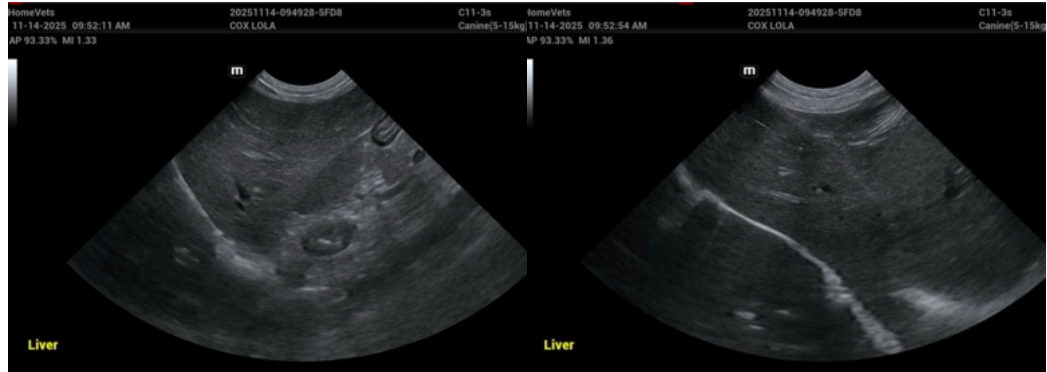Dr. Wolfe

INVOICE

68929

DATE

11/20/25





PATIENT

Lola Cox

SPECIES

Canine

BREED

Jack Russell Terrier
Mix

SEX

Spayed female

AGE

13 years

WEIGHT

18.3 lbs

INTERPRETED BY

Eric Lindquist, DMV
DABVP, Cert. IVUSS

**IMAGING
PERFORMED BY**

Dr. Wolfe

HOSPITAL NAME

HomeVets

REFERRING VET

Dr. Wolfe

INVOICE

68929

DATE

11/20/25

The information and recommendations provided are based on the images presented by the referring veterinarian/sonographer. No evaluation can be communicated regarding pathology that was not visible in the image/video clips provided.

Thank you for this referral. If the clinical or image interpretation does not parallel your findings or if I can be of any further assistance please contact me.

Eric Lindquist, DMV, DABVP (CFM), Cert. IVUSS, CEO of SonoPath.com

info@SonoPath.com