



PATIENT PRESENTING CLINICAL SIGNS

Minnie DiCenzo vomiting not urinating

SPECIES ULTRASONOGRAPHIC EXAMINATION OF THE ABDOMEN

Feline **Urinary System**

The **urinary bladder** was full. The urethra was dilated. I cannot rule out distal obstruction in this patient. The pelvic urethra was imaged 2.0 cm caudal to the cystourethral junction.

BREED

DSH

The **kidneys** revealed normal size and structure, corticomedullary definition and ratio for this age. The cortices presented largely uniform texture with normal echogenic relationship to liver and spleen. Medullary structure differed distinctly from the cortex and no evidence of pelvic dilation was present.

SEX

Spayed Female

The capsules were acceptably uniform without significant irregularities. The right kidney measured 3.5 cm. The left kidney measured 3.7 cm.

Adrenal Glands

AGE

6 Years

The regions of the **adrenal glands** were unremarkable.

Spleen

WEIGHT

10 Pounds

The **spleen** presented a smooth homogeneous parenchyma hyperechoic to liver and renal cortical parenchyma. The capsule was smooth without noticeable expansion or deviation from within the spleen or adjacent pathology. The splenic vasculature demonstrated normal volume without signs of congestion or thrombosis. No sonographic evidence of acute or chronic inflammatory, neoplastic, or infarctual changes were noted.

INTERPRETED BY

Eric Lindquist, DMV

DABVP, Cert. IVUSS

Liver

The **liver** images submitted revealed subjectively normal liver size, contour, and structure. Parenchymal echogenicity was naturally coarse and hypoechoic to the spleen. Vascular and biliary tracts were of normal volume with no evidence of congestion. The gallbladder presented acceptably thin walls with primarily anechoic content. The cystic and common bile ducts were normal. No pathological hepatic lymphadenopathy was evident. No overt structural evidence of inflammatory, infiltrative or regenerative pathology was evident.

IMAGING PERFORMED BY

Jenn

Gastrointestinal

HOSPITAL NAME

Rockaway AH

Examination of the **gastrointestinal tract** revealed a stomach and intestine free of stasis, of normal wall thickness, acceptable curvilinear mural detail, and peristaltic activity. Small and large intestine demonstrated normal luminal chyme and stool consistency respectively. No obstructive or overt infiltrative disease was noted. No associated abnormal lymphatic activity was noted.

REFERRING VET

Dr. Maniar

Pancreas

The base and limbs of the **pancreas** were observed to be largely isoechoic to surrounding omental fat. Pancreatic duct and capsular contour were acceptably normal and parenchyma respected normal curvilinear patterns. No overt evidence of active inflammatory or neoplastic disease was noted.

INVOICE

42481

ULTRASONOGRAPHIC FINDINGS

- Structurally unremarkable abdomen with mildly overdistended bladder and dilated pelvic urethra

DATE

11/2/22



PATIENT

Minnie DiCenzo

INTERPRETATION OF THE FINDINGS & FURTHER RECOMMENDATIONS

Manual expression of the bladder indicated to ensure urethral patency.

SPECIES

Feline

BREED

DSH

SEX

Spayed Female

AGE

6 Years

WEIGHT

10 Pounds

INTERPRETED BY

Eric Lindquist, DMV

DABVP, Cert. IVUSS

IMAGING PERFORMED BY

Jenn

HOSPITAL NAME

Rockaway AH

REFERRING VET

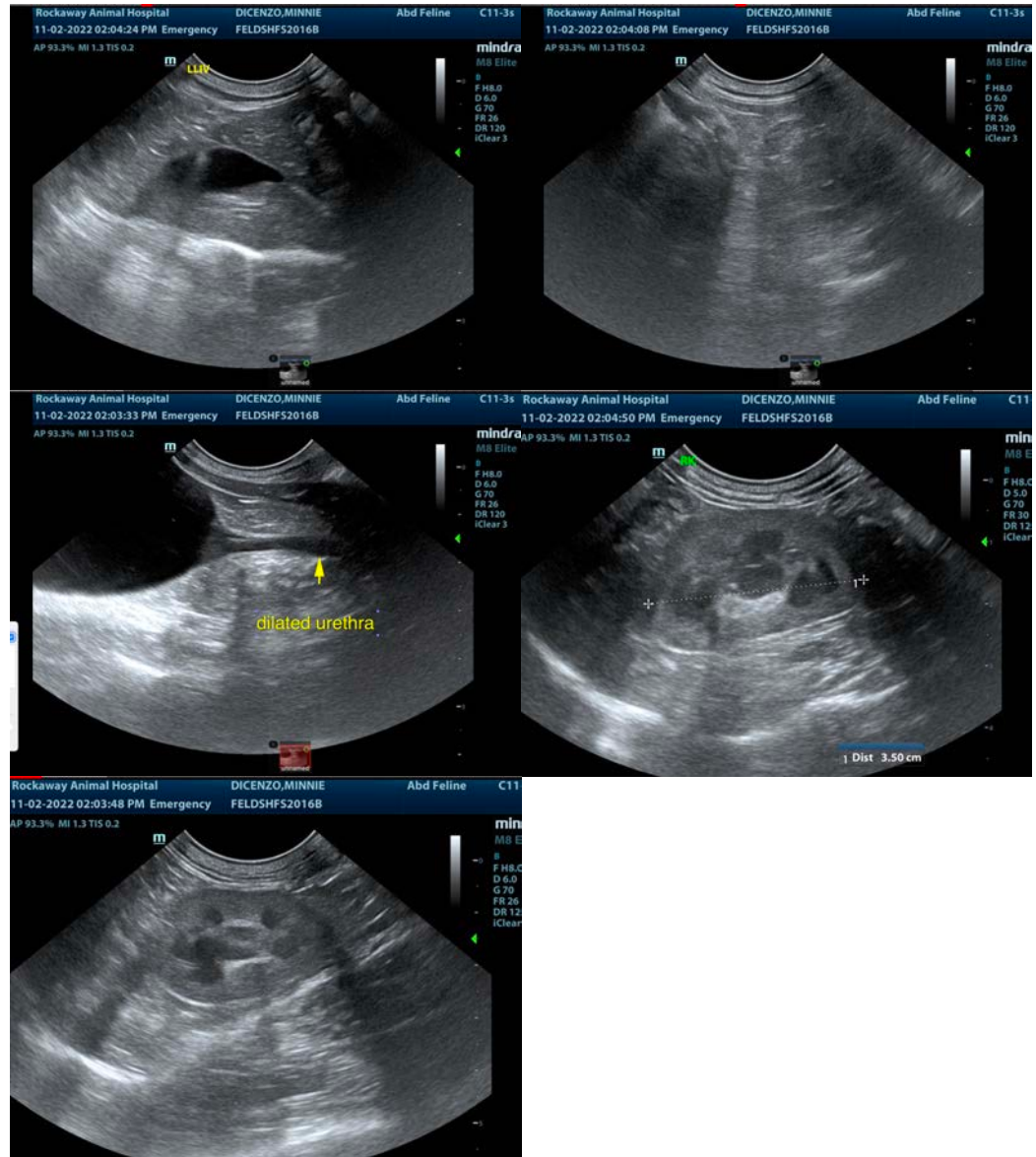
Dr. Maniar

INVOICE

42481

DATE

11/2/22



The information and recommendations provided are based on the images presented by the referring veterinarian/sonographer. No evaluation can be communicated regarding pathology that was not visible in the image/video clips provided.

Thank you for this referral. If the clinical or image interpretation does not parallel your findings or if I can be of any further assistance please contact me.

Eric Lindquist, DMV, DABVP, Cert. IVUSS, CEO of SonoPath.com

info@SonoPath.com