



PATIENT

Hunter Amsden

SPECIES

Canine

BREED

Coton de Tulear

SEX

Neutered male

AGE

11 years

WEIGHT

11.5 lbs

INTERPRETED BY

Eric Lindquist, DMV
DABVP, Cert. IVUSS

IMAGING PERFORMED BY

Dr. Todd

HOSPITAL NAME

Lambs Gap AH

REFERRING VET

Dr. Todd

INVOICE

42301

DATE

11/2/22

PRESENTING CLINICAL SIGNS

History: Hunter is an eleven year old, MN, Coton de Tulear who was seen at our local ER on 9/25/22 for vomiting/diarrhea/anorexia. An abdominal ultrasound was performed and read by Dr. Beth Johnson. A left renal cortical cyst was seen. Recheck abdominal ultrasound was performed today to monitor cyst as owner is deciding if wants to drain and submit for analysis.

ULTRASONOGRAPHIC EXAMINATION OF THE ABDOMEN

Urinary System

The **urinary bladder**, trigone, and pelvic urethra presented normal thicknesses and normal tone. The ureters were not visible which is normal. No uroliths or sediment were visualized and anechoic urine was present. No evidence of inflammatory or neoplastic changes was noted. Ureteral papillae were normal.

The **kidneys** revealed normal size and structure, corticomedullary definition and ratio for this age. The cortices presented largely uniform texture with normal echogenic relationship to liver and spleen. Medullary structure differed distinctly from the cortex and no evidence of pelvic dilation was present. The capsules were acceptably uniform without significant irregularities. The right kidney was normal in size and contour measuring 4.3 cm. The left kidney had a mildly echogenic, 6.4 cm cyst deriving from the cranial pole. There was minor echogenic debris without overt inflammatory pattern. The remainder of the renal structure appeared unremarkable.

Adrenal Glands

Both **adrenal glands** were visualized and recognized as having normal shape, size, position and echogenicity for this breed. The phrenic vasculature, glandular echogenicity and detail were unremarkable. Capsule, cortex, and medullary definition were normal for this age patient. The left adrenal gland measured 1.93 x 0.46 cm at the cranial pole and 0.39 cm at the caudal pole. The right adrenal gland measured 1.33 x 0.8 cm at the cranial pole and 0.4 cm at the caudal pole.

Spleen

The **spleen** presented a smooth homogeneous parenchyma hyperechoic to liver and renal cortical parenchyma. The capsule was smooth without noticeable expansion or deviation from within the spleen or adjacent pathology. The splenic vasculature demonstrated normal volume without signs of congestion or thrombosis. No sonographic evidence of acute or chronic inflammatory, neoplastic, or infarctual changes was noted.

Liver

The **liver** images submitted revealed subjectively normal liver size, contour, and structure. Parenchymal echogenicity was naturally coarse and hypoechoic to the spleen. Vascular and biliary tracts were of normal volume with no evidence of congestion. The gallbladder presented acceptably thin walls with primarily anechoic content. The cystic and common bile ducts were normal. No pathological hepatic



PATIENT

Hunter Amsden

lymphadenopathy was evident. No overt structural evidence of inflammatory, infiltrative or regenerative pathology was evident.

SPECIES

Canine

Gastrointestinal

Examination of the **gastrointestinal tract** revealed a stomach and intestine free of stasis, of normal wall thickness, acceptable curvilinear mural detail, and peristaltic activity. Small and large intestine demonstrated normal luminal chyme and stool consistency respectively. No obstructive or overt infiltrative disease was noted. No associated abnormal lymphatic activity was noted.

BREED

Coton de Tulear

Pancreas

SEX

Neutered male

The base and limbs of the **pancreas** were observed to be largely isoechoic to surrounding omental fat. Pancreatic duct and capsular contour were acceptably normal and parenchyma respected normal curvilinear patterns. No overt evidence of active inflammatory or neoplastic disease was noted.

AGE

11 years

ULTRASONOGRAPHIC FINDINGS

Left renal cyst with echogenic debris, potential low grade infection.

WEIGHT

11.5 lbs

Otherwise, unremarkable abdomen.

INTERPRETED BY

Eric Lindquist, DMV
DABVP, Cert. IVUSS

INTERPRETATION OF THE FINDINGS & FURTHER RECOMMENDATIONS

Palliative drainage, culture and sensitivity could all be considered. The therapeutic benefit is debatable; however, baseline culture would be a good idea to assess and manage any infection that may be present.

IMAGING PERFORMED BY

Dr. Todd

HOSPITAL NAME

Lambs Gap AH

REFERRING VET

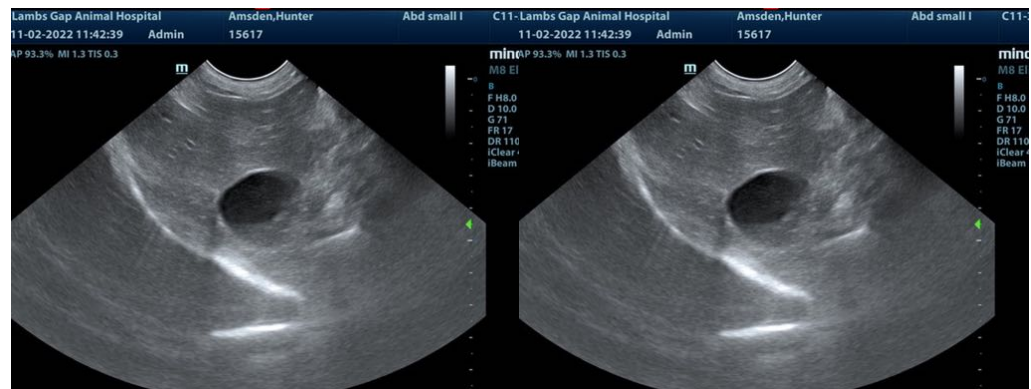
Dr. Todd

INVOICE

42301

DATE

11/2/22





PATIENT

Hunter Amsden

SPECIES

Canine

BREED

Coton de Tulear

SEX

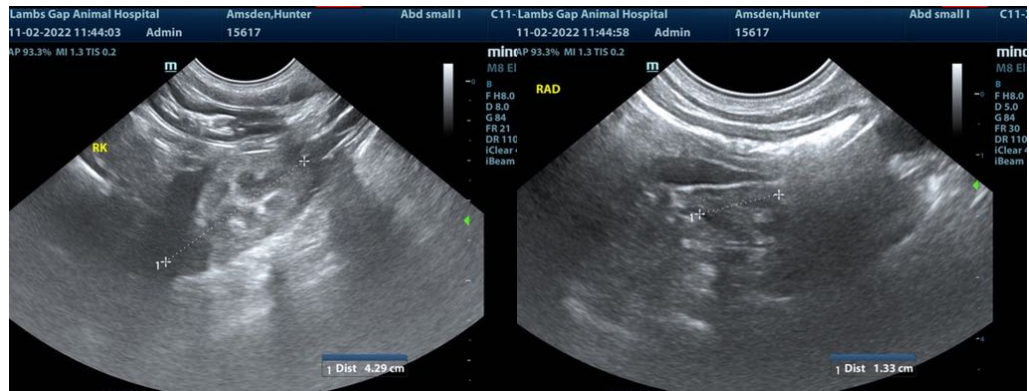
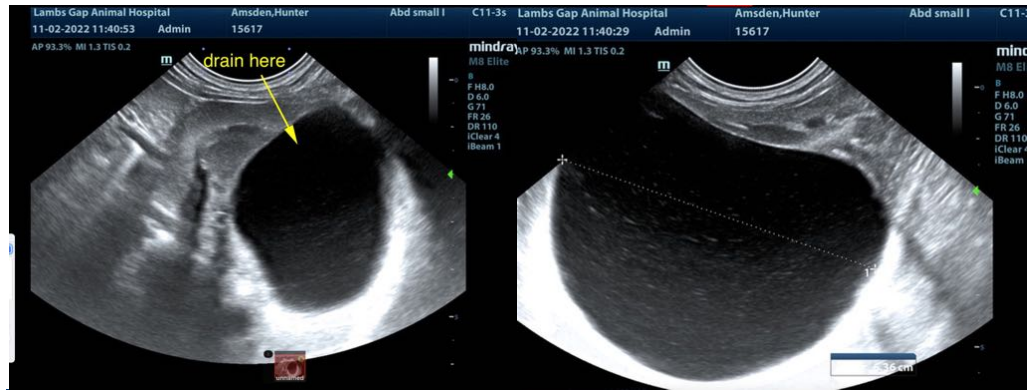
Neutered male

AGE

11 years

WEIGHT

11.5 lbs



INTERPRETED BY

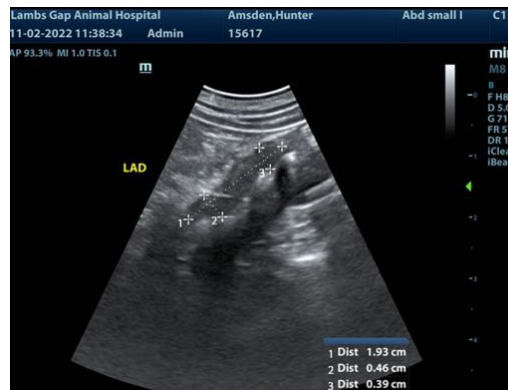Eric Lindquist, DMV
DABVP, Cert. IVUSS

IMAGING PERFORMED BY

Dr. Todd

HOSPITAL NAME

Lambs Gap AH



REFERRING VET

Dr. Todd

INVOICE

42301

DATE

11/2/22

The information and recommendations provided are based on the images presented by the referring veterinarian/sonographer. No evaluation can be communicated regarding pathology that was not visible in the image/video clips provided.

Thank you for this referral. If the clinical or image interpretation does not parallel your findings or if I can be of any further assistance please contact me.

Eric Lindquist, DMV, DABVP, Cert. IVUSS, CEO of SonoPath.com
info@SonoPath.com