



DATE PRESENTING CLINICAL SIGNS

11/2/22

Presented on 10-5-2022 for acute intermittent vomiting; ADR; Grade III/VI left systolic heart murmur, no other significant findings in hospital; responded well to Cerenia + bland diet; large bowel issues/mucous in stool starting on 10-19-2022; empirical dose of Panacur, probiotic, metronidazole; slight improvement in stools; presented on 11-1-2022 for hyporexia, lethargy, relapse of vomiting, large bowel diarrhea; aFAST performed-concern for intestinal neoplasia with secondary free fluid seen; PCV 42%

PATIENT

Hope Thompson

Current Medications: Metronidazole, probiotic, entyce, cerenia
Date of Previous IntraPet Ultrasound: No previous.

SPECIES

Canine

Sedation: Not required to complete full diagnostic ultrasound.
Stat Report: Not requested.
Imaging Performed By: Rachel Brillhart, RDMS.

BREED

Mix

ULTRASONOGRAPHIC EXAMINATION OF THE ABDOMEN

Urinary System

The **urinary bladder**, trigone, and pelvic urethra presented normal thicknesses and normal tone. The ureters were not visible which is normal. No uroliths or sediment were visualized and anechoic urine was present. No evidence of inflammatory or neoplastic changes was noted. Ureteral papillae were normal.

SEX

Spayed female

The **kidneys** revealed normal size and structure, corticomedullary definition and ratio for this age. The cortices presented largely uniform texture with normal echogenic relationship to liver and spleen. Medullary structure differed distinctly from the cortex and no evidence of pelvic dilation was present. The capsules were acceptably uniform without significant irregularities. The right kidney measured 4.01 cm.

AGE

10/9/12

WEIGHT

10 lbs

Adrenal Glands

Both **adrenal glands** were visualized and recognized as having normal shape, size, position and echogenicity for this breed. The phrenic vasculature, glandular echogenicity and detail were unremarkable. Capsule, cortex, and medullary definition were normal for this age patient. The left adrenal gland measured 1.73 x 0.62 cm at the caudal pole and 0.47 cm at the cranial pole. The right adrenal gland measured 1.67 x 0.49 cm at the caudal pole and 0.52 cm at the cranial pole.

INTERPRETED BY

Eric Lindquist, DMV
DABVP, Cert. IVUSS

Spleen

The **spleen** in this patient was mottled and heterogenous with a relatively normal size.

HOSPITAL NAME

Airpark AH

Liver

The **liver** images submitted revealed subjectively normal liver size, contour, and structure. Parenchymal echogenicity was naturally coarse and hypoechoic to the spleen. Vascular and biliary tracts were of normal volume with no evidence of congestion. The gallbladder presented acceptably thin walls with primarily anechoic content. The cystic and common bile ducts were normal. No pathological hepatic lymphadenopathy was evident. No overt structural evidence of inflammatory, infiltrative or regenerative pathology was evident. Transdiaphragmatic view revealed pleural effusion likely owing to metastatic disease to the chest.

REFERRING VET

Dr. Marciszewski

INVOICE

42297

Gastrointestinal

A jejunal mass was noted in this patient. Wall thickness measured up to 1.0 cm. Reactive mesentery was noted throughout the midabdomen with regional free fluid. Other regions of intestinal thickening were also noted with loss of detail. Lymph nodes are enlarged, rounded and hypoechoic with enhanced surrounding mesentery.

Pancreas

The **pancreas** revealed mixed, echogenic changes, obscured owing to the regional mesentery.

ULTRASONOGRAPHIC FINDINGS

Intestinal neoplasia with multi-focal masses and regional lymphadenopathy and free fluid. This is consistent with lymphomatosis or similar.

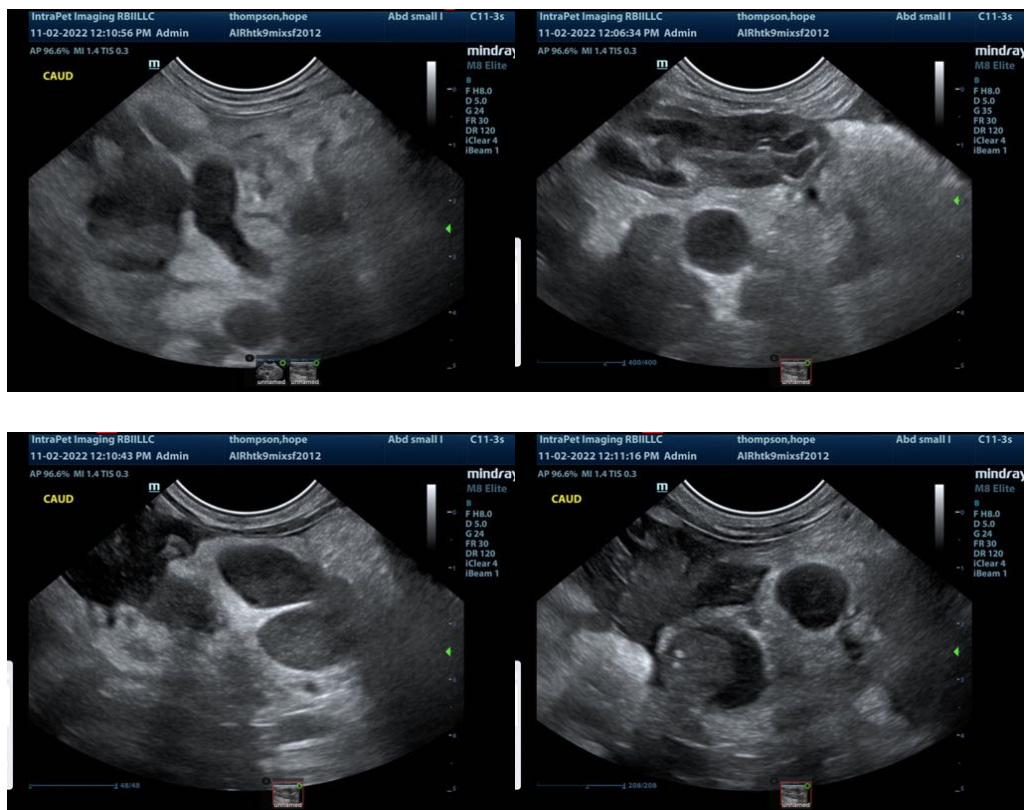
Mottled heterogenous spleen.

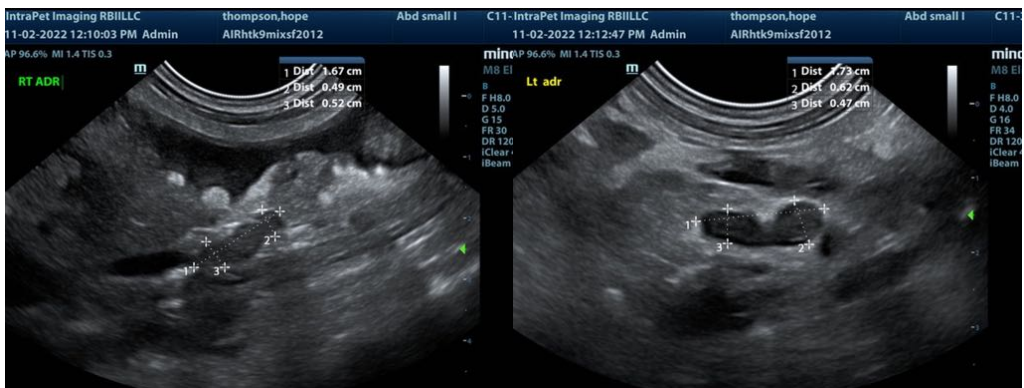
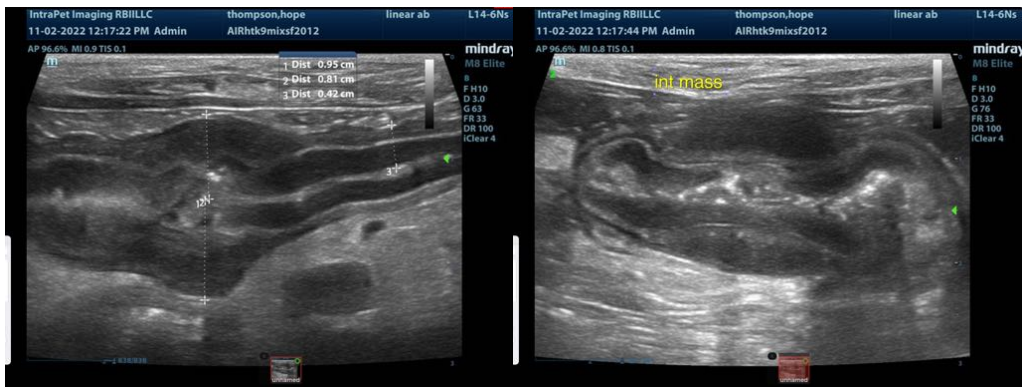
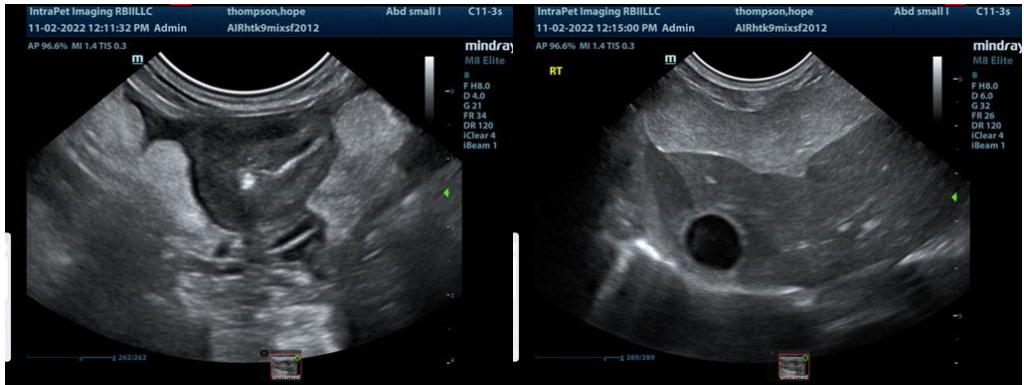
Mixed echogenic pancreatic changes.

Pleural effusion, suggestive for dual cavity neoplasia

INTERPRETATION OF THE FINDINGS & FURTHER RECOMMENDATIONS

FNA of the intestinal mass and lymph nodes are recommended for a definitive diagnosis and immediate chemotherapeutic intervention; however, the pathology is extensive. The prognosis long term is poor.





The information and recommendations provided are based on the images presented by the referring veterinarian. No evaluation can be communicated regarding pathology that was not visible in the image/video clips provided.

Thank you for this referral. If the clinical or image interpretation does not parallel your findings or if I can be of any further assistance please contact me.

Eric Lindquist, DMV, DABVP, Cert. IVUSS, CEO of SonoPath.com
Eric.Lindquist@SonoPath.com