



PATIENT

Gus Dipko

PRESENTING CLINICAL SIGNS

History: Seen 5 days ago for vomiting, losing weight. Tense abd. CBC, Chem, T4 WNL UA had protein 3+, rest NSF UPC 0.7 (high)

SPECIES

Feline

ULTRASONOGRAPHIC EXAMINATION OF THE ABDOMEN

Urinary System

The **urinary bladder** and visible pelvic urethra were unremarkable for the level of repletion presented. The urine, however, did present some mildly echogenic debris consistent with mucous, exfoliated cells from renal or bladder origin, and/or blood clots as these echogenic changes can all present similarly. This is often related to urinary tract infection but may represent simple evidence of exfoliated debris or sterile inflammation. Cystocentesis, urinalysis, +/- culture would be recommended to rule out and define any UTI.

BREED

Domestic Shorthair

SEX

Neutered male

AGE

11 years

The **kidneys** revealed normal size and structure, corticomedullary definition and ratio for this age. The cortices presented largely uniform texture with normal echogenic relationship to liver and spleen. Medullary structure differed distinctly from the cortex and no evidence of pelvic dilation was present. The capsules were acceptably uniform without significant irregularities. The left kidney measured 4.0 cm.

WEIGHT

8 lbs

Adrenal Glands

Both **adrenal glands** were visualized and recognized as having normal shape, size, position and echogenicity for this breed. The phrenic vasculature, glandular echogenicity and detail were unremarkable. Capsule, cortex, and medullary definition were normal for this age patient. The right adrenal gland measured 0.4 cm.

INTERPRETED BY

Eric Lindquist, DMV
DABVP, Cert. IVUSS

IMAGING PERFORMED BY

Kara Wallisch

Spleen

The **spleen** presented a smooth homogeneous parenchyma hyperechoic to liver and renal cortical parenchyma. The capsule was smooth without noticeable expansion or deviation from within the spleen or adjacent pathology. The splenic vasculature demonstrated normal volume without signs of congestion or thrombosis. No sonographic evidence of acute or chronic inflammatory, neoplastic, or infarctual changes was noted.

HOSPITAL NAME

Sondel Family VC

REFERRING VET

Dr. Sondel

Liver

The **liver** images submitted revealed subjectively normal liver size, contour, and structure. Parenchymal echogenicity was naturally coarse and hypoechoic to the spleen. Vascular and biliary tracts were of normal volume with no evidence of congestion. The gallbladder presented acceptably thin walls with primarily anechoic content. The cystic and common bile ducts were normal. No pathological hepatic lymphadenopathy was evident. No overt structural evidence of inflammatory, infiltrative or regenerative pathology was evident.

INVOICE

42291

DATE

11/2/22



PATIENT

Gus Dipko

Gastrointestinal

SPECIES

Feline

There was some residual chyme and gas was noted in the **stomach**, yet not pathological. This is consistent with end post prandial presentation. Transit of chyme into the small intestine was normal. Curvilinear patterns were maintained throughout the GI tract. No evidence of pathology. Small and large intestine demonstrated normal luminal chyme and stool consistency respectively. No obstructive or overt infiltrative disease was noted. The mesenteric lymph node is enlarged, irregular and hypoechoic to the surrounding fat. Other smaller lymph nodes were also enlarged.

BREED

Domestic Shorthair

Pancreas

SEX

Neutered male

The base and limbs of the **pancreas** were observed to be largely isoechoic to surrounding omental fat. Pancreatic duct and capsular contour were acceptably normal and parenchyma respected normal curvilinear patterns. No overt evidence of active inflammatory or neoplastic disease was noted.

AGE

11 years

ULTRASONOGRAPHIC FINDINGS

Enlarged lymph nodes. Reactive lymphadenitis versus round cell neoplasia.

WEIGHT

8 lbs

Remainder of the abdomen was unremarkable.

INTERPRETATION OF THE FINDINGS & FURTHER RECOMMENDATIONS

FNA, cytology and culture of the mesenteric lymph node is recommended.

INTERPRETED BY

Eric Lindquist, DMV
DABVP, Cert. IVUSS

IMAGING PERFORMED BY

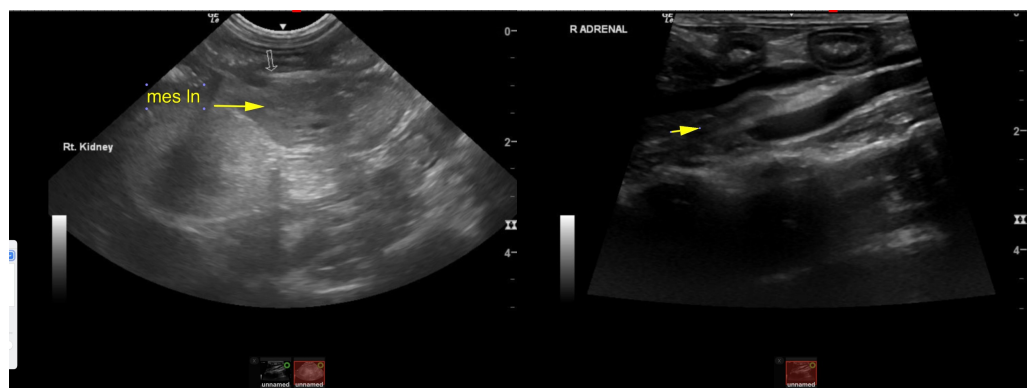
Kara Wallisch

HOSPITAL NAME

Sondel Family VC

REFERRING VET

Dr. Sondel



INVOICE

42291

DATE

11/2/22



PATIENT

Gus Dipko

SPECIES

Feline

BREED

Domestic Shorthair

SEX

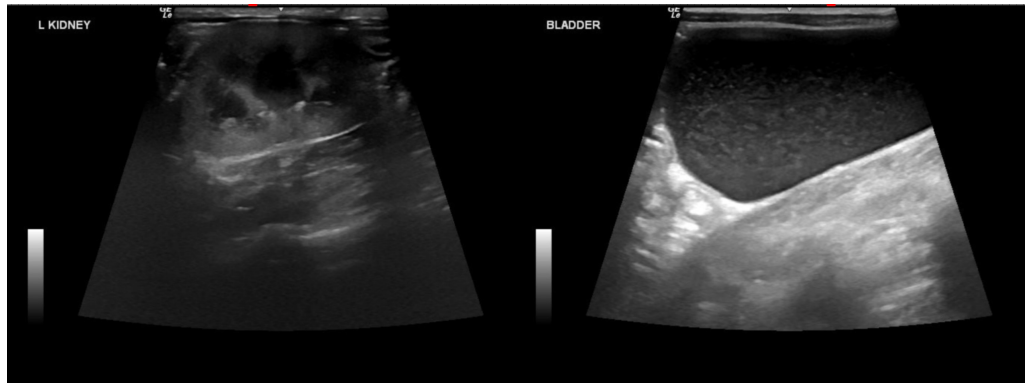
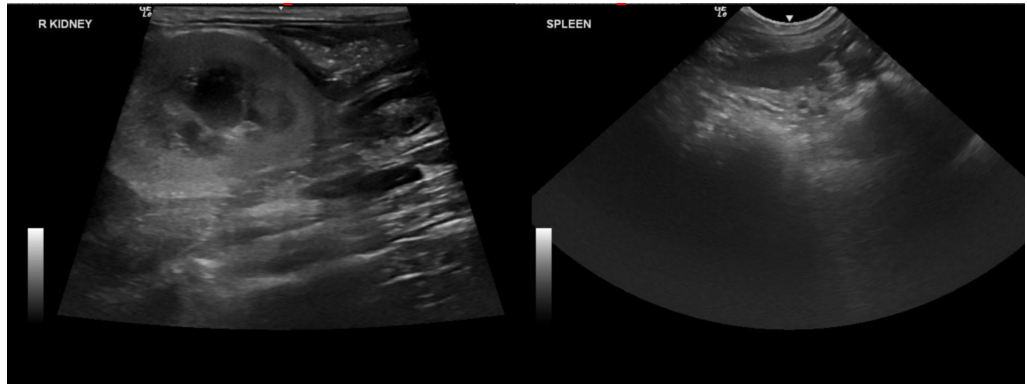
Neutered male

AGE

11 years

WEIGHT

8 lbs



INTERPRETED BY

Eric Lindquist, DMV
DABVP, Cert. IVUSS

IMAGING PERFORMED BY

Kara Wallisch

HOSPITAL NAME

Sondel Family VC

REFERRING VET

Dr. Sondel

INVOICE

42291

DATE

11/2/22

The information and recommendations provided are based on the images presented by the referring veterinarian/sonographer. No evaluation can be communicated regarding pathology that was not visible in the image/video clips provided.

Thank you for this referral. If the clinical or image interpretation does not parallel your findings or if I can be of any further assistance please contact me.

Eric Lindquist, DMV, DABVP, Cert. IVUSS, CEO of SonoPath.com
info@SonoPath.com