



**PATIENT PRESENTING CLINICAL SIGNS**

Fluffy Suto bronchitis, gastroenteritis

**SPECIES ULTRASONOGRAPHIC EXAMINATION OF THE HEART & ABDOMEN**

Feline	<b>FELINE CARDIAC PARAMETERS</b>	<b>BODY WEIGHT (kg)</b>	<b>HR (BPM)</b>	<b>IVSd (cm)</b>	<b>LVIDd (cm)</b>	<b>LVWd (cm)</b>	<b>FS (%)</b>	<b>EF (%)</b>
DLH	<b>NORMAL PARAMETER</b>	-----	150-240	0.3-0.6	1.0-2.1	0.25-0.6	35-67	80-100
	<b>PATIENT</b>		NM	0.5	1.2	0.45	50	90
Female	<b>FELINE CARDIAC PARAMETERS</b>	<b>LA/AO (Boon)</b>	<b>LA/AO HEART BASE (Sisson)</b>	<b>LA 2D 4-chamber long axis AS to FW (Sisson) (cm)</b>		<b>LVOT VEL. (m/s)</b>	<b>RVOT VEL. (m/s)</b>	<b>IVRT (m/)</b>
7 Years	<b>NORMAL PARAMETER</b>	<1.5	0.88-1.79	0.7-1.7		<1.6	<1.3	40-60
	<b>PATIENT</b>		1.37				0.7	NM

Adapted from June Boon, Veterinary Echocardiography, 1998  
Sisson D et al. JVIM 1991; 5: 232, Jacobs et al. Am J Vet Res 1985; 46:1705

**WEIGHT**  
7.3 Pounds

**Cardiac Presentation**

The echocardiogram in this patient demonstrated normal **left atrial** size based on 3 separate LA measurements. The cranial and caudal **mitral** valve leaflets presented normal linear structure and kinetics. The **left ventricle** presented normal thicknesses with linear contour and was not dilated nor restricted. The **myocardium** presented normal echogenicity without subjective evidence of significant fibrotic or ischemic disease. **Contractility** of the ventricular walls was adequate and in normal range for this patient evidenced by the fractional shortening measurement and subjective evaluation of the different regions and angles of the myocardium. The **left ventricular outflow** tract demonstrated normal laminar flow and subjective structural integrity. The **right atrium** and auricle revealed normal size, structure and content. No evidence of masses was noted or chamber overload. **Tricuspid** valvular assessment demonstrated adequate linear morphology and kinetics. The **right ventricle** was of normal size (1/3 diameter of LV), chordae structure, myocardial echogenicity and thickness. **Pulmonic** tract assessment revealed normal valve structure, laminar flow, and diameter (approx. 1:1 pa/ao ratio). No visible **pericardial** or free pleura fluid was noted or extra cardiac pathology in the visible planes. The cranial **mediastinum** and **pericardial regions** were free of masses in the visible window.

**Urinary System**

The **urinary bladder**, trigone, and pelvic urethra presented normal thicknesses and normal tone. The ureters were not visible which is normal. No uroliths or sediment were visualized and anechoic urine was present. No evidence of inflammatory or neoplastic changes were noted. Ureteral papillae were normal.

The **kidneys** revealed normal size and structure, corticomedullary definition and ratio for this age. The cortices presented largely uniform texture with normal echogenic relationship to liver and spleen. Medullary structure differed distinctly from the cortex and no evidence of pelvic dilation was present.

**INTERPRETED BY**

Eric Lindquist, DMV  
DABVP, Cert. IVUSS

**IMAGING PERFORMED BY**

Jenn

**HOSPITAL NAME**

Rockaway AH

**REFERRING VET**

Dr. Maniar

**INVOICE**

42479

**DATE**

11/2/22



**PATIENT**

Fluffy Suto

The capsules were acceptably uniform without significant irregularities. The right kidney measured 2.58 cm.

**Adrenal Glands**

**SPECIES**

Feline

The regions of the **adrenal glands** were unremarkable.

**Spleen**

**BREED**

DLH

The **spleen** presented a smooth homogeneous parenchyma hyperechoic to liver and renal cortical parenchyma. The capsule was smooth without noticeable expansion or deviation from within the spleen or adjacent pathology. The splenic vasculature demonstrated normal volume without signs of congestion or thrombosis. No sonographic evidence of acute or chronic inflammatory, neoplastic, or infarctual changes were noted.

**SEX**

Female

**Liver**

**AGE**

7 Years

The **liver** images submitted revealed subjectively normal liver size, contour, and structure. Parenchymal echogenicity was naturally coarse and hypoechoic to the spleen. Vascular and biliary tracts were of normal volume with no evidence of congestion. The gallbladder presented acceptably thin walls with primarily anechoic content. The cystic and common bile ducts were normal. No pathological hepatic lymphadenopathy was evident. No overt structural evidence of inflammatory, infiltrative or regenerative pathology was evident.

**WEIGHT**

7.3 Pounds

**Gastrointestinal**

Examination of the **gastrointestinal tract** revealed a stomach and intestine free of stasis, of normal wall thickness, acceptable curvilinear mural detail, and peristaltic activity. Small and large intestine demonstrated normal luminal chyme and stool consistency respectively. No obstructive or overt infiltrative disease was noted. No associated abnormal lymphatic activity was noted.

**INTERPRETED BY**

Eric Lindquist, DMV

**Pancreas**

DABVP, Cert. IVUSS

The base and limbs of the **pancreas** were observed to be largely isoechoic to surrounding omental fat. Pancreatic duct and capsular contour were acceptably normal and parenchyma respected normal curvilinear patterns. No overt evidence of active inflammatory or neoplastic disease was noted.

**IMAGING PERFORMED BY**

Jenn

**ULTRASONOGRAPHIC FINDINGS**

**HOSPITAL NAME**

Rockaway AH

- Normal echocardiogram
- Structurally unremarkable abdomen

**INTERPRETATION OF THE FINDINGS & FURTHER RECOMMENDATIONS**

Supportive care for gastroenteritis should prove effective. No evidence of cardiac disease.

**REFERRING VET**

Dr. Maniar

**INVOICE**

42479

**DATE**

11/2/22



**PATIENT**

Fluffy Suto

**SPECIES**

Feline

**BREED**

DLH

**SEX**

Female

**AGE**

7 Years

**WEIGHT**

7.3 Pounds

**INTERPRETED BY**

Eric Lindquist, DMV

DABVP, Cert. IVUSS

**IMAGING PERFORMED BY**

Jenn

**HOSPITAL NAME**

Rockway AH

**REFERRING VET**

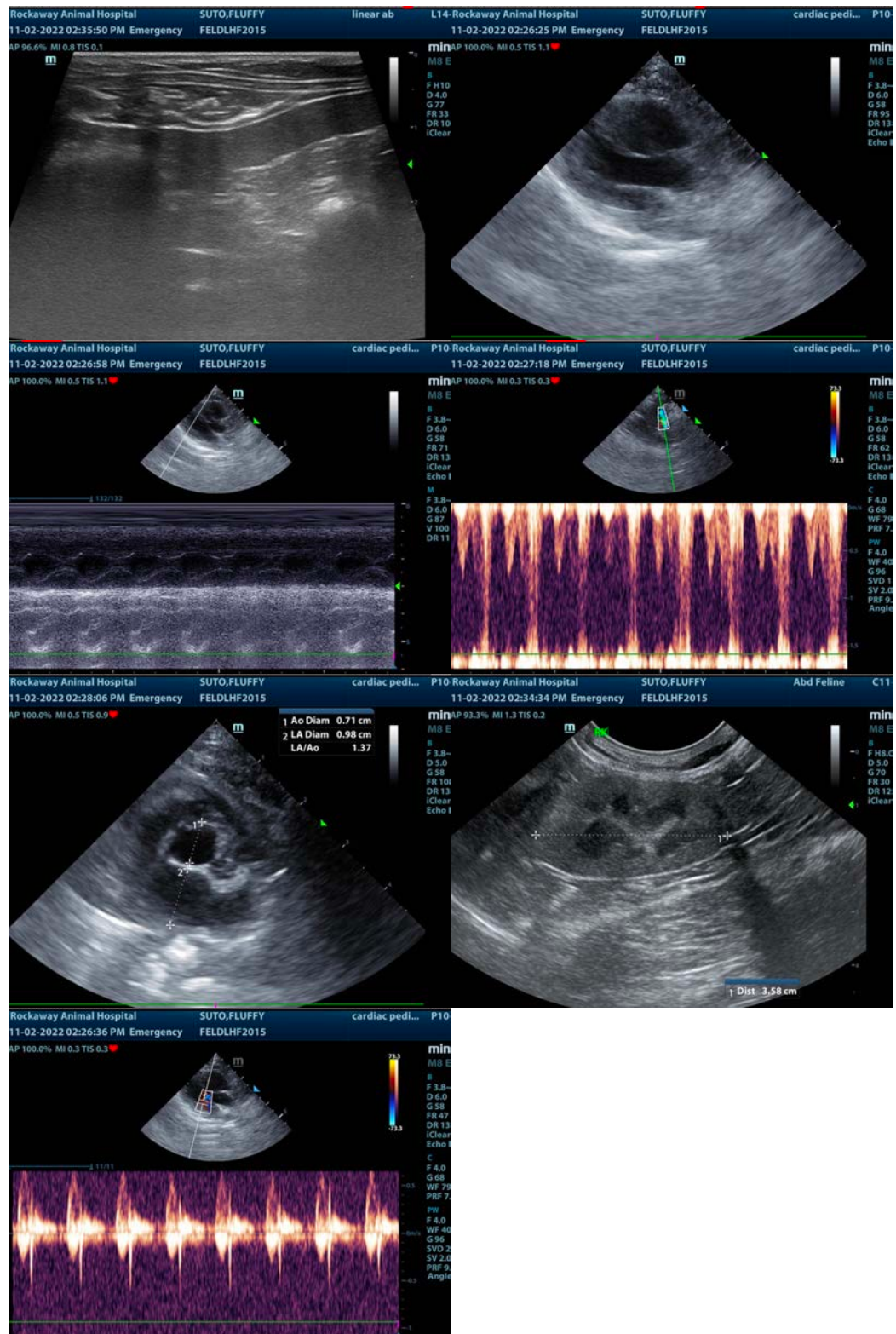
Dr. Maniar

**INVOICE**

42479

**DATE**

11/2/22





**PATIENT**

Fluffy Suto

The information and recommendations provided are based on the images presented by the referring veterinarian/sonographer. No evaluation can be communicated regarding pathology that was not visible in the image/video clips provided.

**SPECIES**

Feline

Thank you for this referral. If the clinical or image interpretation does not parallel your findings or if I can be of any further assistance please contact me.

**Eric Lindquist**, DMV, DABVP, Cert. IVUSS, CEO of SonoPath.com

[info@SonoPath.com](mailto:info@SonoPath.com)

**BREED**

DLH

**SEX**

Female

**AGE**

7 Years

**WEIGHT**

7.3 Pounds

**INTERPRETED BY**

Eric Lindquist, DMV

DABVP, Cert. IVUSS

**IMAGING PERFORMED BY**

Jenn

**HOSPITAL NAME**

Rockaway AH

**REFERRING VET**

Dr. Maniar

**INVOICE**

42479

**DATE**

11/2/22