



PATIENT

Molly Mayer

SPECIES

Canine

BREED

Goldendoodle

SEX

Spayed Female

AGE

10 ½ years

WEIGHT

48 lbs

INTERPRETED BY

Eric Lindquist, DMV
DABVP, Cert. IVUSS

IMAGING PERFORMED BY

Dr. Myers

HOSPITAL NAME

Hershire AH

REFERRING VET

Dr. Myers

INVOICE

92814

DATE

11/2/21

PRESENTING CLINICAL SIGNS

History: chronic mild elevation of ALT. No clinical signs. 11/2020: ALT = 155 9/24/2021 ALT = 249 10/19/21: ALT = 320 all other liver values normal no bile acids done yet Denamarin trial with no change in values

ULTRASONOGRAPHIC EXAMINATION OF THE ABDOMEN

Urinary System

The **urinary bladder**, trigone, and pelvic urethra presented normal thicknesses and normal tone. The pelvic urethra was imaged 2.0 cm beyond the cystourethral junction. The ureters were not visible which is normal. No uroliths or sediment were visualized and anechoic urine was present. No evidence of inflammatory or neoplastic changes was noted. Ureteral papillae were normal.

The **kidneys** revealed largely normal size and structure, corticomedullary definition and ratio (cortex 1/3 of medulla) were essentially maintained with some age-related loss of curvilinear patterns regarding the capsule and C/M junction. The cortices presented largely uniform texture with some increased echogenicity expected for this age patient. Medullary structure differed distinctly from that of the cortex and no evidence of pelvic dilation was present. Slight pinpoint mineralization was noted. The kidneys each measured 6.0 cm.

Adrenal Glands

Both **adrenal glands** were visualized and recognized as having normal shape, size, position and echogenicity for this breed. The phrenic vasculature, glandular echogenicity and detail were unremarkable. Capsule, cortex, and medullary definition were normal for this age patient. The left adrenal gland measured 0.5 cm. The right adrenal gland measured 1.0 cm at the cranial pole and 0.6 cm at the caudal pole.

Spleen

The **spleen** presented a smooth homogeneous parenchyma hyperechoic to liver and renal cortical parenchyma. The capsule was smooth without noticeable expansion or deviation from within the spleen or adjacent pathology. The splenic vasculature demonstrated normal volume without signs of congestion or thrombosis. No sonographic evidence of acute or chronic inflammatory, neoplastic, or infarctual changes was noted.

Liver

The **liver** revealed slight coarse architecture. The changes are expected for this age patient. The gallbladder and common bile duct were unremarkable. This is consistent with on-specific inflammatory hepatopathy, likely reactive hepatopathy given the lack of any significant structural changes.



PATIENT

Molly Mayer

Gastrointestinal

Examination of the **gastrointestinal tract** revealed a stomach and intestine free of stasis, of normal wall thickness, acceptable curvilinear mural detail, and peristaltic activity. Small and large intestine demonstrated normal luminal chyme and stool consistency respectively. No obstructive or overt infiltrative disease was noted. No associated abnormal lymphatic activity was noted.

SPECIES

Canine

BREED

Goldendoodle

Pancreas

The base and limbs of the **pancreas** were observed to be largely isoechoic to surrounding omental fat. Pancreatic duct and capsular contour were acceptably normal and parenchyma respected normal curvilinear patterns. No overt evidence of active inflammatory or neoplastic disease was noted.

SEX

Spayed Female

ULTRASONOGRAPHIC FINDINGS

AGE

10 ½ years

Largely age related hepatic changes, expected for this age and breed, likely reactive hepatopathy as cause of liver enzyme elevations.

WEIGHT

48 lbs

INTERPRETATION OF THE FINDINGS & FURTHER RECOMMENDATIONS

FNA can be considered for further definition.

INTERPRETED BY

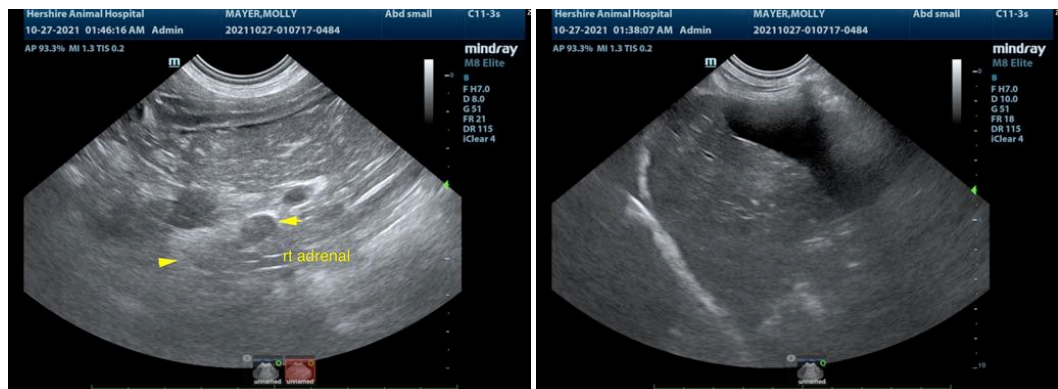
Eric Lindquist, DMV
DABVP, Cert. IVUSS

IMAGING PERFORMED BY

Dr. Myers

HOSPITAL NAME

Hershire AH



REFERRING VET

Dr. Myers

INVOICE

92814

DATE

11/2/21



PATIENT

Molly Mayer

SPECIES

Canine

BREED

Goldendoodle

SEX

Spayed Female

AGE

10 ½ years

WEIGHT

48 lbs

INTERPRETED BY

Eric Lindquist, DMV
DABVP, Cert. IVUSS

IMAGING PERFORMED BY

Dr. Myers

HOSPITAL NAME

Hershire AH

REFERRING VET

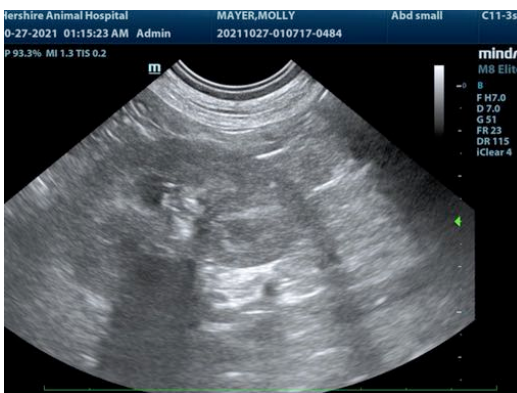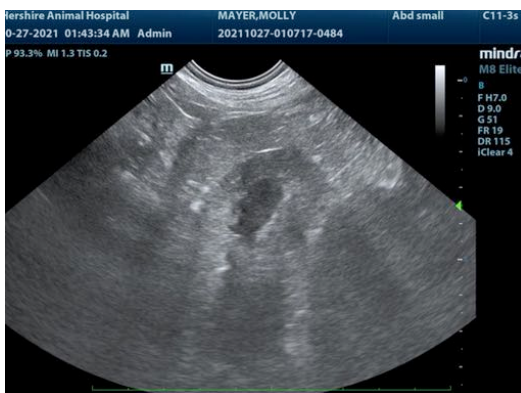
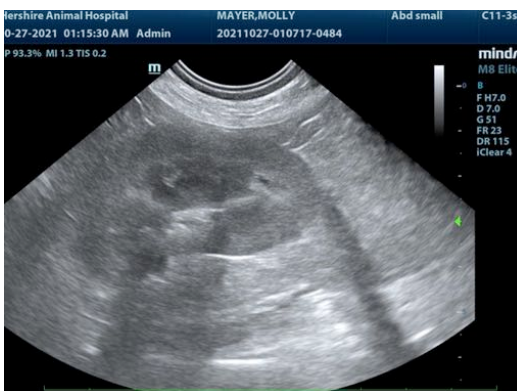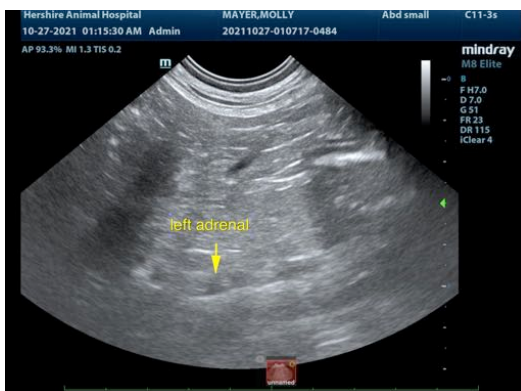
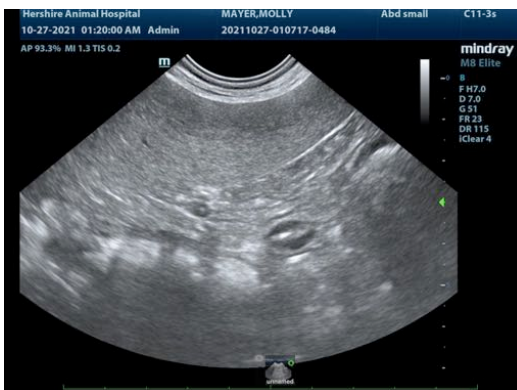
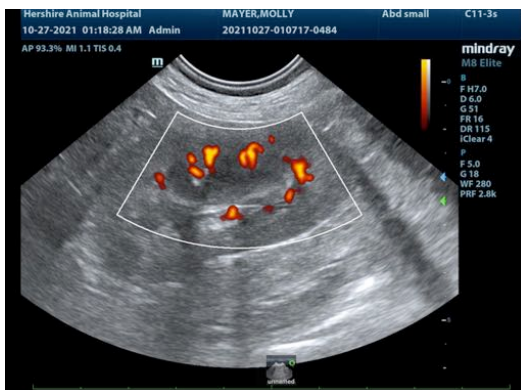
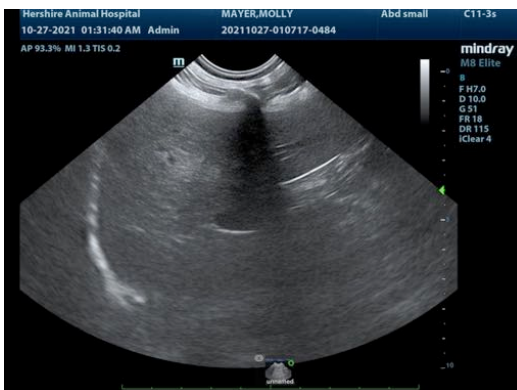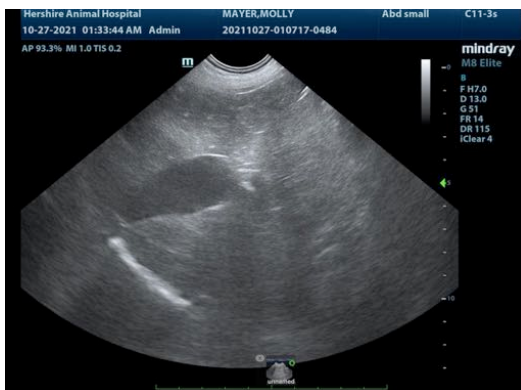Dr. Myers

INVOICE

92814

DATE

11/2/21





PATIENT

Molly Mayer

The information and recommendations provided are based on the images presented by the referring veterinarian. No evaluation can be communicated regarding pathology that was not visible in the image/video clips provided.

SPECIES

Canine

Thank you for this referral. If the clinical or image interpretation does not parallel your findings or if I can be of any further assistance please contact me.

BREED

Goldendoodle

Eric Lindquist, DMV, DABVP, Cert. IVUSS, CEO of SonoPath.com
info@SonoPath.com

SEX

Spayed Female

AGE

10 ½ years

WEIGHT

48 lbs

INTERPRETED BY

Eric Lindquist, DMV
DABVP, Cert. IVUSS

**IMAGING
PERFORMED BY**

Dr. Myers

HOSPITAL NAME

Hershire AH

REFERRING VET

Dr. Myers

INVOICE

92814

DATE

11/2/21