



PATIENT

Isabel Delgado

SPECIES

Canine

BREED

French Bulldog

SEX

Intact female

AGE

8 years

WEIGHT

9.96 kg

INTERPRETED BY

Eric Lindquist, DMV
DABVP, Cert. IVUSS

IMAGING PERFORMED BY

Dr. Wepprich

HOSPITAL NAME

Wilvet Salem

REFERRING VET

Dr. Wepprich

INVOICE

92768

DATE

11/2/21

PRESENTING CLINICAL SIGNS

History: Vomiting, diarrhea, lethargic x 5 days. Raw Salmon exposure multiple times over last few weeks. Recent heat cycle 10 days ago that was shorter than normal per owner.

Abnormal PE/Chem/CBC/UA Results: PE - lethargic, no fever, no vaginal discharge, frequent hematochezia with clots. Rectal exam - circumferential small nodules palpable in rectal mucosa CBC - neutropenia 2k, plt 28k, hct 43 Chem - AST and ALP mildly elevated, Tbili 0.6, cholesterol 240, albumin 2.4 fecal pending

ULTRASONOGRAPHIC EXAMINATION OF THE ABDOMEN

Urinary System

The **urinary bladder**, trigone, and pelvic urethra presented normal thicknesses and normal tone. The ureters were not visible which is normal. A minor amount of suspended debris was noted in the urinary bladder. No evidence of inflammatory or neoplastic changes was noted. Ureteral papillae were normal.

The **kidneys** were normal in size with mildly irregular contour and mildly increased cortical echogenicity and loss of corticomedullary detail. Both kidneys measured 5.0 cm.

Adrenal Glands

The right **adrenal gland** was uniform and measured 0.5 cm. The region of the left adrenal gland was imaged with no evidence of pathology.

Spleen

The **spleen** was mildly enlarged and slightly swollen with enhanced mesentery associated with the cranial abdomen.

Liver

The **liver** revealed slightly increased portal markings with minor swelling. The gallbladder and common bile duct were unremarkable. The hepatic lymph nodes were enlarged and rounded measuring up to 2.0x 1.0 cm.

Gastrointestinal

The upper **gastrointestinal tract** was largely unremarkable. The gastric wall was also thickened. The small intestine revealed mildly increased submucosal thickening with areas of fluid filled lumen. Trace amounts of free fluid were noted. The colonic wall was significantly thickened and measured 0.8 cm at the wall thickness. There was loss of detail.

Pancreas



PATIENT Heterogenous pancreatic changes were noted in the right limb.

Isabel Delgado **Free Abdomen**

The iliac lymph nodes were enlarged, hypoechoic and rounded with enhanced surrounding mesentery. The iliac lymph nodes are likely associated with the colonic thickening.

SPECIES

Canine

ULTRASONOGRAPHIC FINDINGS

Iliac lymphadenopathy with variable gastrointestinal and colonic thickening.

French Bulldog

Reactive mesentery.

SEX

Minor hepatosplenic swelling and hepatic lymphadenopathy.

Intact female

INTERPRETATION OF THE FINDINGS & FURTHER RECOMMENDATIONS

AGE

Ultrasound-guided FNA of the accessible lymph nodes, spleen and liver would be recommended. Colonoscopy would be ideal with mucosal biopsies. Emerging round cell neoplasia versus infectious agents are both possible in this patient especially salmon poisoning. There was no evidence of pyometra or reproductive pathology. Guarded prognosis. Sampling is essential in this case given the low albumin. Protein losing enteropathy is likely if no significant proteinuria is present.

8 years

WEIGHT

9.96 kg

INTERPRETED BY

Eric Lindquist, DMV
DABVP, Cert. IVUSS

IMAGING PERFORMED BY

Dr. Wepprich

HOSPITAL NAME

Wilvet Salem

REFERRING VET

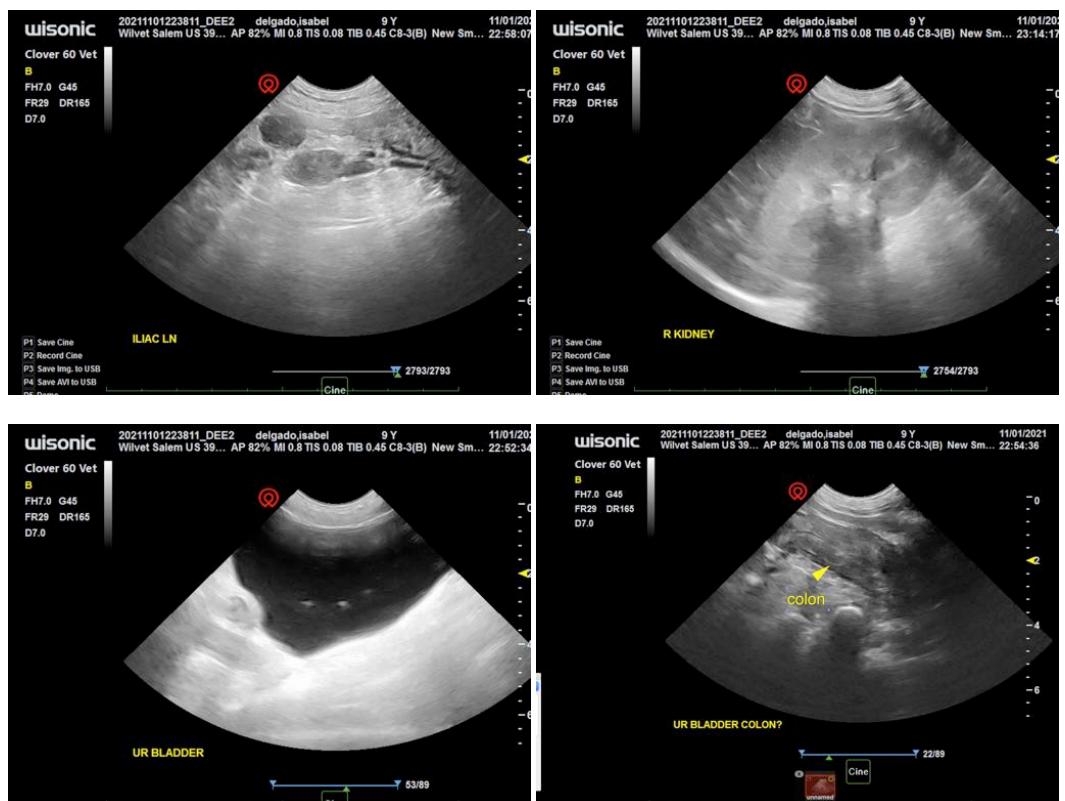
Dr. Wepprich

INVOICE

92768

DATE

11/2/21



The information and recommendations provided are based on the images presented by the referring



PATIENT

Isabel Delgado

veterinarian. No evaluation can be communicated regarding pathology that was not visible in the image/video clips provided.

Thank you for this referral. If the clinical or image interpretation does not parallel your findings or if I can be of any further assistance please contact me.

SPECIES

Canine

Eric Lindquist, DMV, DABVP, Cert. IVUSS, CEO of SonoPath.com
info@SonoPath.com

BREED

French Bulldog

SEX

Intact female

AGE

8 years

WEIGHT

9.96 kg

INTERPRETED BY

Eric Lindquist, DMV
DABVP, Cert. IVUSS

**IMAGING
PERFORMED BY**

Dr. Wepprich

HOSPITAL NAME

Wilvet Salem

REFERRING VET

Dr. Wepprich

INVOICE

92768

DATE

11/2/21