



PATIENT

Benjamin Ghertler

SPECIES

Feline

BREED

British Shorthair

SEX

Neutered Male

AGE

2009

WEIGHT

13.03 lbs

INTERPRETED BY

Eric Lindquist, DMV
DABVP, Cert IVUSS

**IMAGING
PERFORMED BY**

Denise Bruno, LVT,
RDMS

HOSPITAL NAME

Brooklyn Heights VH

REFERRING VET

Dr. Thomson

INVOICE

92822

DATE

11/02/21

PRESENTING CLINICAL SIGNS

History: Severely matted fur, ocular discharge

ADR

Evaluate for IBD, occult neoplasia, other

Labs attached

ULTRASONOGRAPHIC EXAMINATION OF THE ABDOMEN

Urinary System

The **urinary bladder**, trigone, and pelvic urethra presented normal thicknesses and normal tone. The ureters were not visible which is normal. No uroliths or sediment were visualized and anechoic urine was present. No evidence of inflammatory or neoplastic changes was noted. Ureteral papillae were normal.

The **kidneys** revealed largely normal size and structure, corticomedullary definition and ratio (cortex 1/3 of medulla) were essentially maintained with some age-related loss of curvilinear patterns regarding the capsule and C/M junction. The cortices presented largely uniform texture with some increased echogenicity expected for this age patient. Medullary structure differed distinctly from that of the cortex and no evidence of pelvic dilation was present. The right kidney measured 4.0 cm.

Adrenal Glands

Both **adrenal glands** were visualized and recognized as having normal shape, size, position and echogenicity for this breed. The phrenic vasculature, glandular echogenicity and detail were unremarkable. Capsule, cortex, and medullary definition were normal for this age patient. The right adrenal gland measured 0.3 cm. The left adrenal gland measured

Spleen

The **spleen** presented a smooth homogeneous parenchyma hyperechoic to liver and renal cortical parenchyma. The capsule was smooth without noticeable expansion or deviation from within the spleen or adjacent pathology. The splenic vasculature demonstrated normal volume without signs of congestion or thrombosis. No sonographic evidence of acute or chronic inflammatory, neoplastic, or infarctual changes was noted.

Liver

The **liver** images from right and left intercostal as well as subcostal views revealed subjectively normal liver size, contour, and structure. Some age-related parenchymal remodeling was noted but likely not clinically significant at this time. Vascular and biliary tracts were of normal volume and no evidence of congestion was noted. The gallbladder presented some dependent debris with essentially normal contour. The cystic and common bile ducts were normal. No overt evidence of active inflammatory, infiltrative or regenerative pathology was noted but should be paired with current or past LE elevations regarding any clinical significance to this presentation. The hepatic lymph nodes were unremarkable.



PATIENT

Gastrointestinal

Benjamin Ghertler

The **gastrointestinal tract** revealed minor variable thickening and echogenic submucosal changes most consistent with low grade end result of chronic GI disease such as IBD and may be related to malassimilation of nutrients if any weight loss is present. No obvious neoplastic patterns were noted and luminal content as unremarkable. Soft stool was noted in the colon.

SPECIES

Feline

BREED

British Shorthair

Pancreas

The **pancreas** was hypoechoic and irregular with a dilated duct measuring 0.16 cm. The left pancreatic limb measured 1.18 cm. The pancreatic lymph node was reactive and measured 1.33 x 0.28 cm.

SEX

Neutered Male

ULTRASONOGRAPHIC FINDINGS

Prominent pancreas.

AGE

Mild, chronic GI changes.

2009

Otherwise, unremarkable abdomen.

WEIGHT

13.03 lbs

INTERPRETATION OF THE FINDINGS & FURTHER RECOMMENDATIONS

There was no evidence of significant disease. If systemic lymphocytosis is a continual issue then PCR upon CBC blood smear may be optimal in this patient or bone marrow aspirate, yet structurally the abdominal changes are largely expected for this age patient with the possibility of low-grade pancreatitis.

INTERPRETED BY

Eric Lindquist, DMV
DABVP, Cert IVUSS

IMAGING PERFORMED BY

Denise Bruno, LVT,
RDMS

HOSPITAL NAME

Brooklyn Heights VH

REFERRING VET

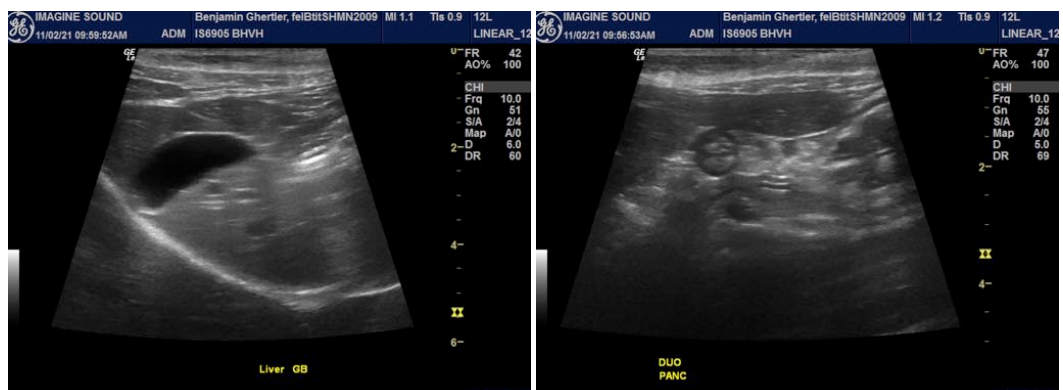
Dr. Thomson

INVOICE

92822

DATE

11/02/21





PATIENT

Benjamin Ghertler

SPECIES

Feline

BREED

British Shorthair

SEX

Neutered Male

AGE

2009

WEIGHT

13.03 lbs

INTERPRETED BY

Eric Lindquist, DMV
DABVP, Cert IVUSS

**IMAGING
PERFORMED BY**

Denise Bruno, LVT,
RDMS

HOSPITAL NAME

Brooklyn Heights VH

REFERRING VET

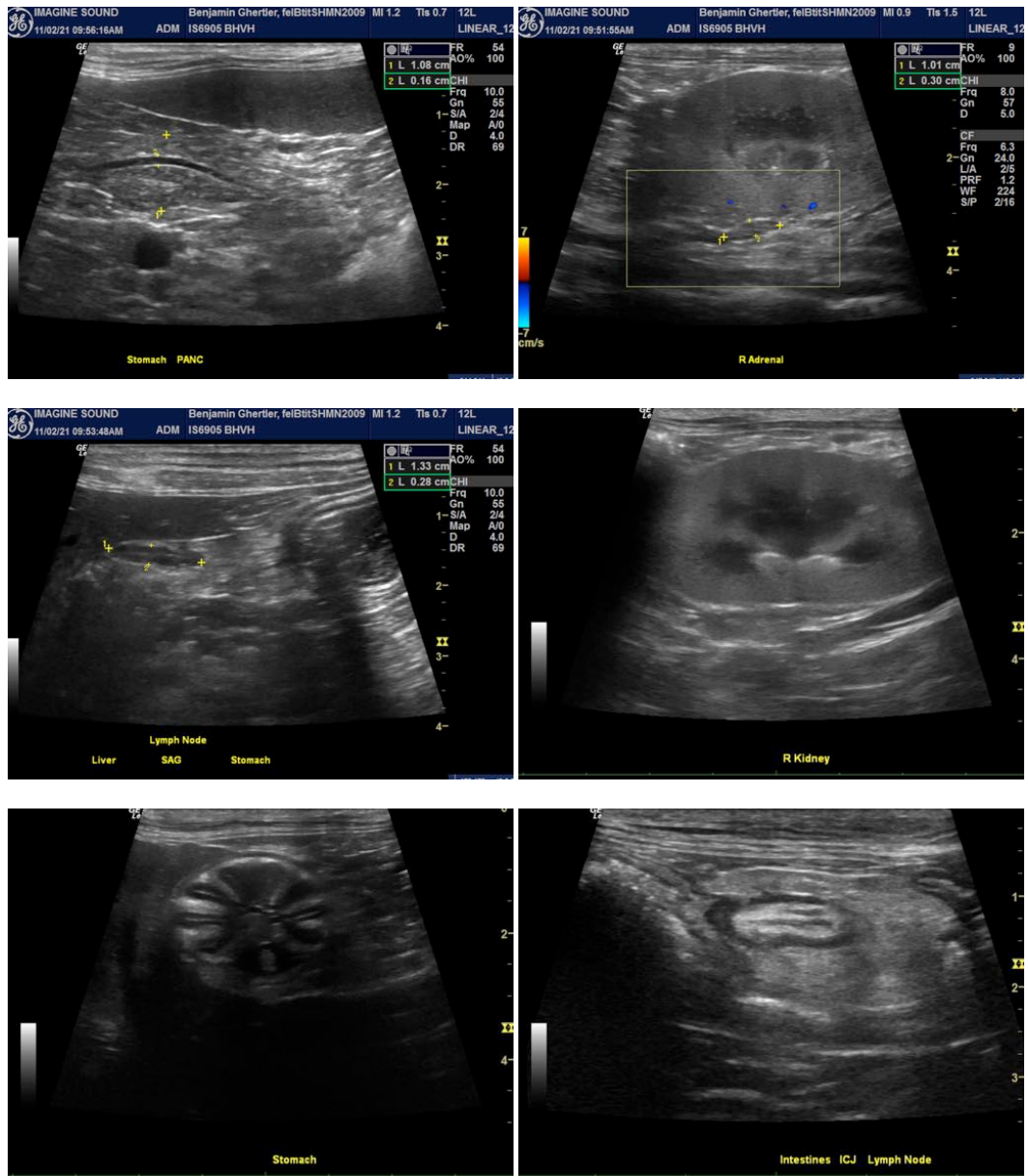
Dr. Thomson

INVOICE

92822

DATE

11/02/21



The information and recommendations provided are based on the images presented by the referring veterinarian. No evaluation can be communicated regarding pathology that was not visible in the image/video clips provided.

Thank you for this referral. If the clinical or image interpretation does not parallel your findings or if I can be of any further assistance please contact me.

Eric Lindquist, DMV, DABVP, Cert. IVUSS, CEO of SonoPath.com
Eric.Lindquist@SonoPath.com