



PATIENT

Keeper Wagner

SPECIES

Canine

BREED

Labrador Retriever

SEX

Male

AGE

11 years

WEIGHT

59.8 lbs

INTERPRETED BY

Eric Lindquist, DMV
DABVP, Cert. IVUSS

IMAGING PERFORMED BY

Susan Lincoski, VMD

HOSPITAL NAME

University Drive VH

REFERRING VET

Dr. Lincoski

INVOICE

68842

DATE

11/19/25

PRESENTING CLINICAL SIGNS

History: Pollakiuria, no straining. note. Intact male, no nephro-uro-or ureteroliths evident radiographically and prostates does not appear enlarged, and no ventral colon deviation noted on lateral radiograph. Normal rectal exam, obvious prostatomegaly and non-painful. Normal exam including testicular

Abnormal PE/Chem/CBC/UA Results: UA pending

ULTRASONOGRAPHIC EXAMINATION OF THE ABDOMEN

Urinary System

The **urinary bladder** was structurally unremarkable with a trace amount of dependent debris. The proximal urethra was slightly thickened. There was no evidence of calculi. The pelvic urethra was imaged 3.0 cm beyond the cystourethral junction and appeared normal.

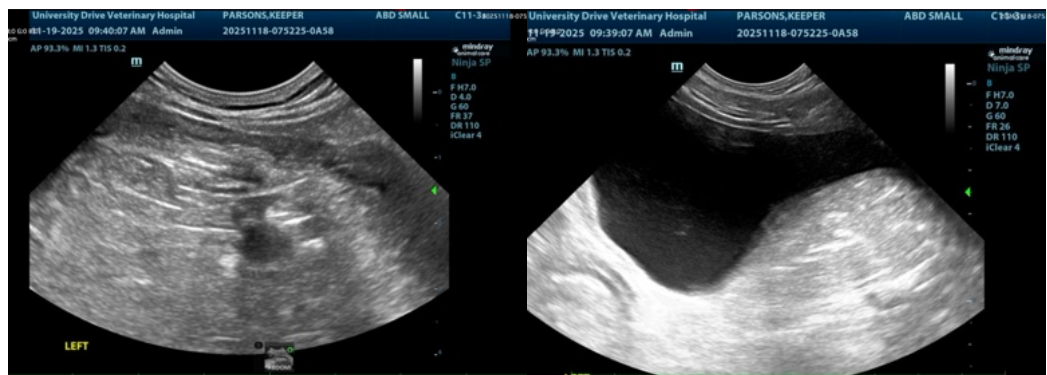
The **prostate** was not visualized. It appears to be deep in the pelvis.

ULTRASONOGRAPHIC FINDINGS

Slightly thickened pelvic urethra.

INTERPRETATION OF THE FINDINGS & FURTHER RECOMMENDATIONS

I recommend BRAF testing in case of urethral carcinoma versus urethritis. Catheter passage and injection of saline in the deep pelvic urethra is recommended to enhance visibility. Management for occult UTI/urethritis is indicated in the meantime.





PATIENT

Keeper Wagner

SPECIES

Canine

BREED

Labrador Retriever

SEX

Male

AGE

11 years

WEIGHT

59.8 lbs

INTERPRETED BY

Eric Lindquist, DMV
DABVP, Cert. IVUSS

IMAGING PERFORMED BY

Susan Lincoski, VMD

HOSPITAL NAME

University Drive VH

REFERRING VET

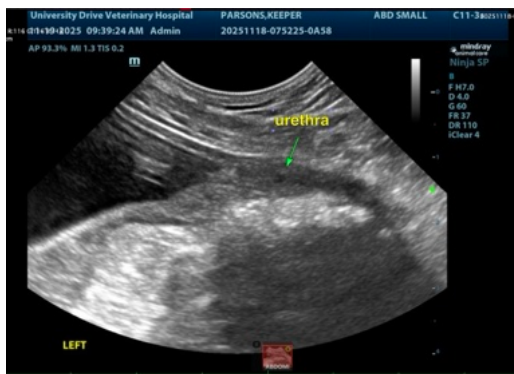Dr. Lincoski

INVOICE

68842

DATE

11/19/25



The information and recommendations provided are based on the images presented by the referring veterinarian/sonographer. No evaluation can be communicated regarding pathology that was not visible in the image/video clips provided.

Thank you for this referral. If the clinical or image interpretation does not parallel your findings or if I can be of any further assistance please contact me.

Eric Lindquist, DMV, DABVP (CFM), Cert. IVUSS, CEO of SonoPath.com

info@SonoPath.com