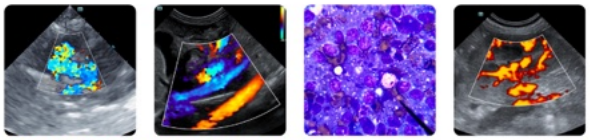

PATIENT
Hendley Queler

SPECIES
Canine

BREED
Goldendoodle

SEX
Spayed female

AGE
11 years

WEIGHT
50 lbs

INTERPRETED BY
Eric Lindquist, DMV
DABVP, Cert. IVUSS

IMAGING PERFORMED BY
Dr. Hadley Harris

HOSPITAL NAME
TotalBond VH

REFERRING VET
Dr. Salmon

INVOICE
68841

DATE
11/19/25

PRESENTING CLINICAL SIGNS

History: On annual screening labs, Neutropenia at 1300 (norm-3000-9000), Leukopenia 2700(norm 5800-16000), and lymphopenia 491 (norm 982-4200). Remainder of labwork was unremarkable. Patient has lost about 4 pounds in the last 6 months, but has been more active. Otherwise asymptomatic. 4dx neg. Evaluated thorax and abdomen radiographs and a 5cm ovoid soft tissue mass effect present in right caudal abdomen (in expected location of tail of spleen). Sending for AUS to determine if splenic vs GI or other in origin.

ULTRASONOGRAPHIC EXAMINATION OF THE ABDOMEN

Urinary System

The **urinary bladder**, trigone, and pelvic urethra presented normal thicknesses and normal tone. The pelvic urethra was imaged 2.0 cm beyond the cystourethral junction and appeared normal. The ureters were not visible which is normal. No uroliths or sediment were visualized and anechoic urine was present. No evidence of inflammatory or neoplastic changes was noted. Ureteral papillae were normal.

The **kidneys** revealed largely normal size and structure, corticomedullary definition and ratio (cortex 1/3 of medulla) were essentially maintained with some age-related loss of curvilinear patterns regarding the capsule and C/M junction. The cortices presented largely uniform texture with some increased echogenicity expected for this age patient. Medullary structure differed distinctly from that of the cortex and no evidence of pelvic dilation was present. The right kidney measured 6.4 cm. The left kidney measured 7.3 cm.

Adrenal Glands

Both **adrenal glands** were visualized and recognized as having normal shape, size, position and echogenicity for this breed. The phrenic vasculature, glandular echogenicity and detail were unremarkable. Capsule, cortex, and medullary definition were normal for this age patient. The left adrenal gland measured 2.0 x 0.7 cm. The right adrenal gland was visualized obliquely and measured approximately 1.0 cm in maximum width.

Spleen

The **spleen** revealed a microcavitated and parenchymal mass that measured 4.2 cm. The mass was deriving from the cranial pole.

Liver

The **liver** images from right and left intercostal as well as subcostal views revealed subjectively normal liver size, contour, and structure. Some age-related parenchymal remodeling was noted but likely not clinically significant at this time. Vascular and biliary tracts were of normal volume and no evidence of congestion was noted. The gallbladder presented some dependent debris with essentially normal contour. The cystic and common bile ducts were normal. No overt evidence of active inflammatory,

PATIENT
Hendley Queler

SPECIES
Canine

BREED
Goldendoodle

SEX
Spayed female

AGE
11 years

WEIGHT
50 lbs

INTERPRETED BY
Eric Lindquist, DMV DABVP, Cert. IVUSS

IMAGING PERFORMED BY
Dr. Hadley Harris

HOSPITAL NAME
TotalBond VH

REFERRING VET
Dr. Salmon

INVOICE
68841

DATE
11/19/25

infiltrative or regenerative pathology was noted but should be paired with current or past LE elevations regarding any clinical significance to this presentation. The hepatic lymph nodes were unremarkable.

Gastrointestinal

Examination of the **gastrointestinal tract** revealed a stomach and intestine free of stasis, of normal wall thickness, acceptable curvilinear mural detail, and peristaltic activity. Small and large intestine demonstrated normal luminal chyme and stool consistency respectively. No obstructive or overt infiltrative disease was noted. No associated abnormal lymphatic activity was noted.

Pancreas

The base and limbs of the **pancreas** were observed to be largely isoechoic to surrounding omental fat. Pancreatic duct and capsular contour were acceptably normal and parenchyma respected normal curvilinear patterns. No overt evidence of active inflammatory or neoplastic disease was noted.

ULTRASONOGRAPHIC FINDINGS

Splenic mass. Differentials include benign hyperplasia, hemangiosarcoma. Round cell neoplasia is unlikely, yet possible. Stromal tumor is also possible.

Age related abdominal changes otherwise.

INTERPRETATION OF THE FINDINGS & FURTHER RECOMMENDATIONS

There was no evidence of rupture; however, the splenic mass is highly precarious. The splenic mass may be completely incidental given the patient's history. CBC path review, bone marrow aspirate and splenectomy are all justified if chest radiographs and echocardiogram are free of evident pathology.

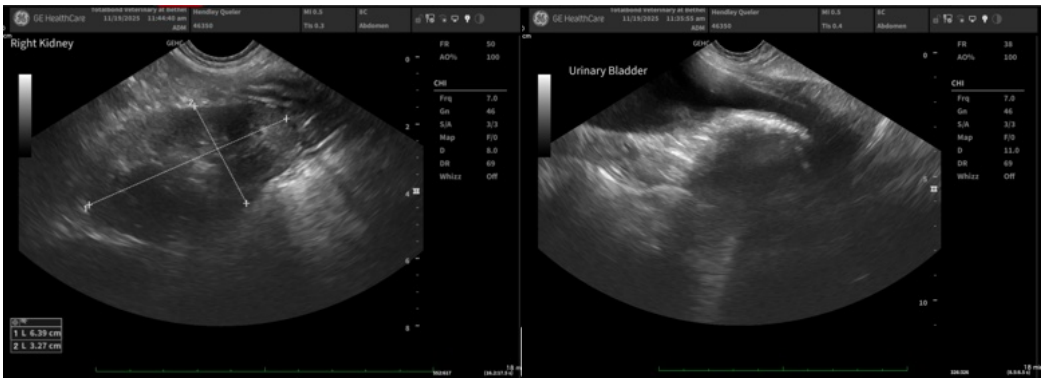

SonoPath
FOSTERING THE ART OF VETERINARY MEDICINE™

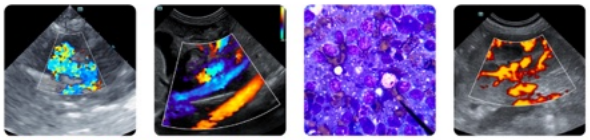

Clinical Sonography & Telecytology
Educational Teleconsultation Services™

SonoPath.com info@sonopath.com 1.800.838.4268

PATIENT

Hendley Queler

SPECIES

Canine

BREED

Goldendoodle

SEX

Spayed female

AGE

11 years

WEIGHT

50 lbs

INTERPRETED BY

Eric Lindquist, DMV
DABVP, Cert. IVUSS

IMAGING PERFORMED BY

Dr. Hadley Harris

HOSPITAL NAME

TotalBond VH

REFERRING VET

Dr. Salmon

INVOICE

68841

DATE

11/19/25

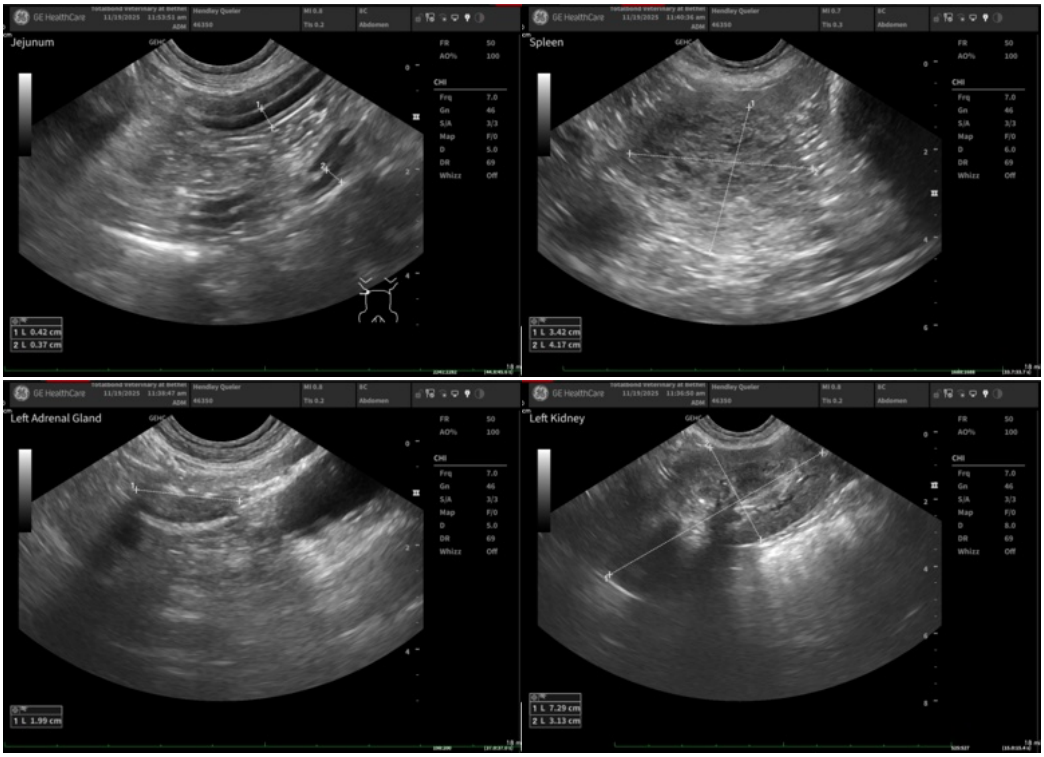

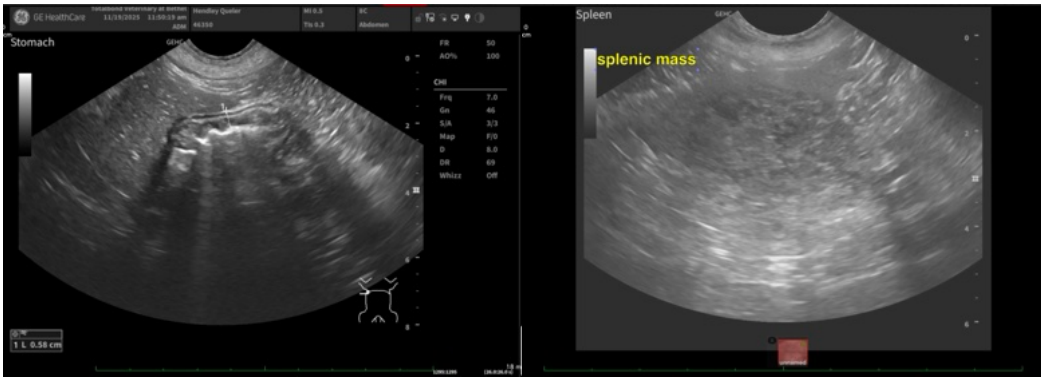

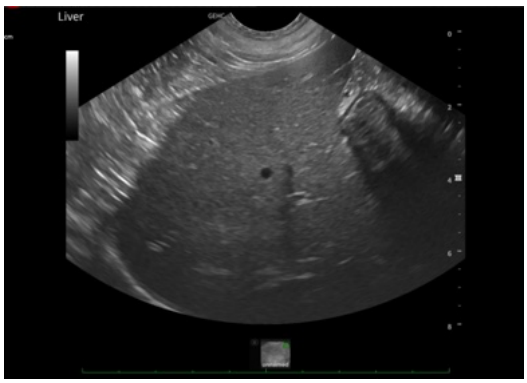

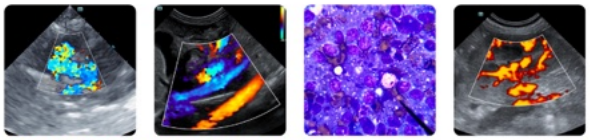

PATIENT

Hendley Queler

SPECIES

Canine

BREED

Goldendoodle

SEX

Spayed female

AGE

11 years

WEIGHT

50 lbs

INTERPRETED BY

Eric Lindquist, DMV
DABVP, Cert. IVUSS

IMAGING PERFORMED BY

Dr. Hadley Harris

HOSPITAL NAME

TotalBond VH

REFERRING VET

Dr. Salmon

INVOICE

68841

DATE

11/19/25

The information and recommendations provided are based on the images presented by the referring veterinarian/sonographer. No evaluation can be communicated regarding pathology that was not visible in the image/video clips provided.

Thank you for this referral. If the clinical or image interpretation does not parallel your findings or if I can be of any further assistance please contact me.

Eric Lindquist, DMV, DABVP (CFM), Cert. IVUSS, CEO of SonoPath.com

info@SonoPath.com