



PATIENT

Balto Lombardo

SPECIES

Canine

BREED

Pom

SEX

Neutered Male

AGE

8

WEIGHT

8

INTERPRETED BY

Eric Lindquist, DMV,
DABVP(CFM), Cert.
IVUSS

IMAGING PERFORMED BY

Jenn

HOSPITAL NAME

Rockaway Animal
Hospital

REFERRING VET

Dr. Maniar

INVOICE

12325

DATE

11/19/25

PRESENTING CLINICAL SIGNS

Shaking, panting, O concerned could have eaten chocolate Increased HR on intake

Abnormal PE/Chem/CBC/UA Results: ALT 151

ULTRASONOGRAPHIC EXAMINATION OF THE HEART & ABDOMEN

CANINE CARDIAC PARAMETERS	MR VMAX (m/s)	TR VMAX (m/s)	LA/AO (M-Mode)	LA/AO (Heart Base; Swe)	FS (%)	EF (%)	EPSS (cm)
NORMAL PARAMETER	4.5-5.5	<2.7	1.3	Up to 1.6	28-40	40-100	<0.6
PATIENT	--	--	1.1	1.2	--	67	35
CANINE CARDIAC PARAMETERS	HR (BPM)	AV VMAX (m/s)	PV MAX (m/s)	BODY WEIGHT (kg)	LAD LA MAX 4 Chamber	LVIDd Avg; 2D and m-mode short axis (cm)	LVIDs Avg; 2D and m-mode short axis (cm)
NORMAL PARAMETER	50-100	0.7-1.7	0.7-1.6				
PATIENT	60	--	0.67	--	--	2.17	--

Cardiac Presentation

The echocardiogram in this patient demonstrated normal **left atrial** size based on 3 separate methods of LA evaluation. Trivial mitral insufficiency was noted (not clinically significant). The **left ventricle** presented normal thicknesses with linear contour and was not dilated nor restricted. The **myocardium** presented normal echogenicity without subjective evidence of significant fibrotic or ischemic disease. **Contractility** of the ventricular walls was adequate and in normal range for this patient evidenced by the fractional shortening measurement and subjective evaluation of the different regions of the myocardium. The **left ventricular outflow** tract demonstrated normal laminar flow and subjective structural integrity. The **right atrium** and auricle revealed normal size, structure and content. No evidence of masses was noted. **Tricuspid** valvular assessment demonstrated adequate linear morphology and kinesis. The **right ventricle** was of normal size (1/3 diameter of LV), chordae structure, myocardial echogenicity and thickness. **Pulmonary outflow** tract assessment revealed normal valve structure, laminar flow, and diameter (approx.1:1 pa/ao ratio). No visible **pericardial** or free pleura fluid was noted. The cranial **mediastinum and pericardial and extra-cardiac regions** were free of masses in the visible window. Periodic arrhythmia was noted in this patient.

Urinary System

The **urinary bladder**, trigone, and pelvic urethra (to a depth of 2.0 cm) presented normal thicknesses and normal tone. The ureters were not visible which is normal. No uroliths or sediment were visualized, and anechoic urine was present. No evidence of inflammatory or neoplastic changes were noted. Ureteral papillae were normal.



PATIENT

Balto Lombardo

SPECIES

Canine

BREED

Pom

SEX

Neutered Male

AGE

8

WEIGHT

8

INTERPRETED BY

Eric Lindquist, DMV,
DABVP(CFM), Cert.
IVUSS

IMAGING PERFORMED BY

Jenn

HOSPITAL NAME

Rockaway Animal
Hospital

REFERRING VET

Dr. Maniar

INVOICE

12325

DATE

11/19/25

The **kidneys** revealed normal size and structure, corticomedullary definition and ratio for this age. The cortices presented largely uniform texture with normal echogenic relationship to liver and spleen. Medullary structure differed distinctly from the cortex and no evidence of pelvic dilation was present. The capsules were acceptably uniform without significant irregularities. The left kidney measured 3.40 cm in length. The right kidney measured 3.40 cm in length.

Adrenal Glands

Both **adrenal glands** were visualized and recognized as having normal shape, size, position and echogenicity for this breed. The phrenic vasculature, glandular echogenicity and detail were unremarkable. Capsule, cortex, and medullary definition were normal for this age patient. The left adrenal gland measured 1.46 cm width x 0.44 cm width at the caudal pole and 0.60 cm width at the cranial pole. The right adrenal gland measured 1.42 cm x 0.66 cm width at the caudal pole and 0.86 cm width at the cranial pole.

Spleen

The **spleen** presented a smooth homogeneous parenchyma hyperechoic to liver and renal cortical parenchyma. The capsule was smooth without noticeable expansion or deviation from within the spleen or adjacent pathology. The splenic vasculature demonstrated normal volume without signs of congestion or thrombosis. No sonographic evidence of acute or chronic inflammatory, neoplastic, or infarctual changes were noted.

Liver

The **liver** images submitted revealed subjectively normal liver size, contour, and structure. Parenchymal echogenicity was naturally coarse and hypoechoic to the spleen. Vascular and biliary tracts were of normal volume with no evidence of congestion. The gallbladder presented acceptably thin walls with primarily anechoic content. The cystic and common bile ducts were normal. No pathological hepatic lymphadenopathy was evident. No overt structural evidence of inflammatory, infiltrative or regenerative pathology was evident.

Gastrointestinal

Examination of the **gastrointestinal tract** revealed an unremarkable stomach and small intestine regarding structure. There were minor areas of luminal fluid noted. There was no evidence of obstructive pattern. Curvilinear patterns were retained throughout the gastrointestinal tract. Areas of hyperperistalsis were noted. This is consistent with response to irritation. The colon was unremarkable.

Pancreas

The base and limbs of the **pancreas** were observed to be largely isoechoic to surrounding omental fat. Pancreatic duct and capsular contour were acceptably normal and parenchyma respected normal curvilinear patterns. No overt evidence of active inflammatory or neoplastic disease was noted.

ULTRASONOGRAPHIC FINDINGS

- Normal echocardiogram with no evidence of pathology.
- Periodic arrhythmia.
- Nonspecific gastroenteritis presentation.



PATIENT

Balto Lombardo

SPECIES

Canine

BREED

Pom

SEX

Neutered Male

AGE

8

WEIGHT

8

INTERPRETED BY

Eric Lindquist, DMV,
DABVP(CFM), Cert.
IUUSS

IMAGING PERFORMED BY

Jenn

HOSPITAL NAME

Rockaway Animal
Hospital

REFERRING VET

Dr. Maniar

INVOICE

12325

DATE

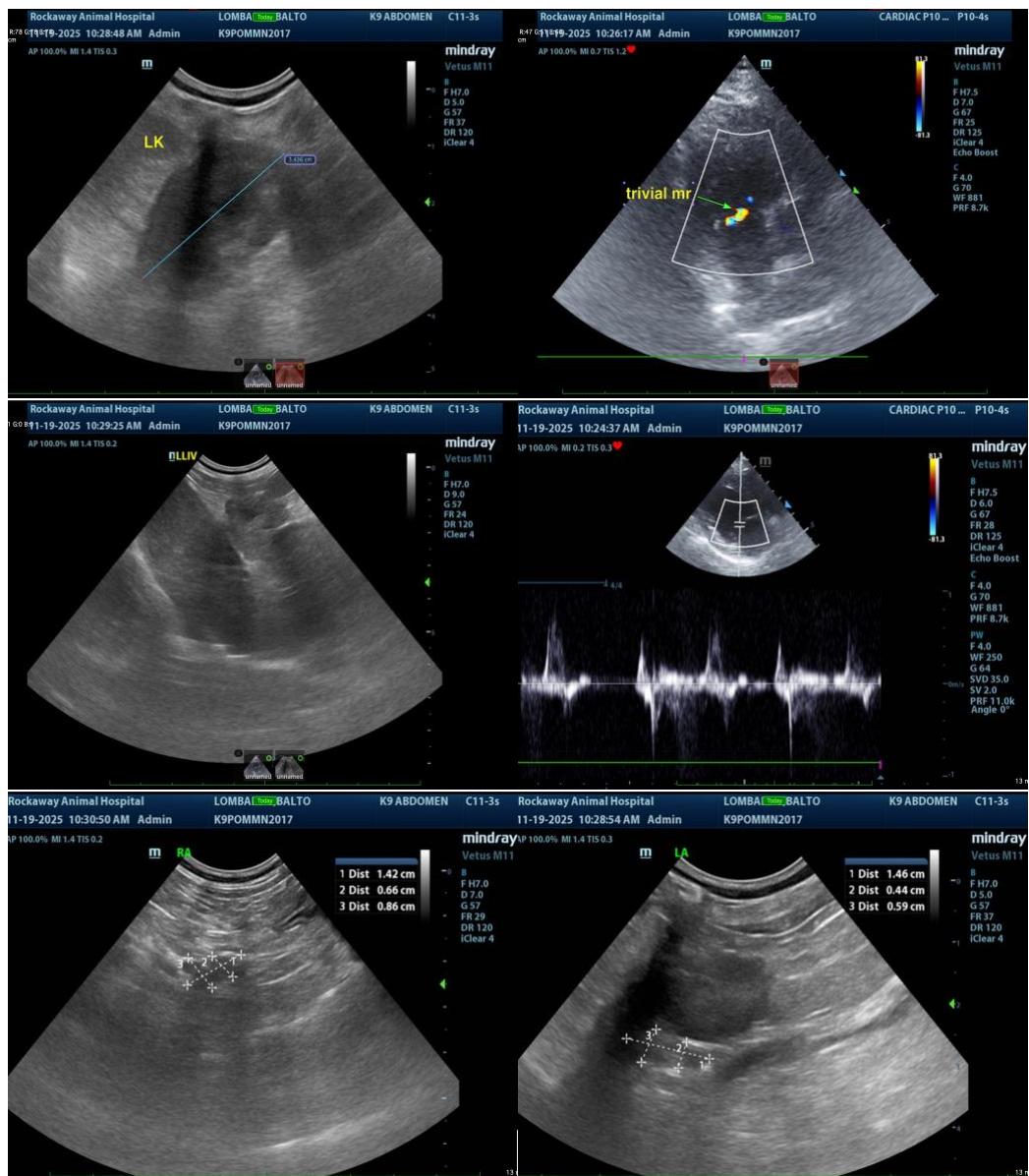
11/19/25

INTERPRETATION OF THE FINDINGS & FURTHER RECOMMENDATIONS

An EKG is warranted to ensure the periodic arrhythmia is likely a sinus arrhythmia. The heart is stable without clinical disease. No overt contraindication for anesthesia of brief to moderate duration. I suggest Torbutrol premed, Propofol induction, Isoflor maintenance or similar protocol if anesthesia is desired. Blood pressure, EKG and chest radiographs are recommended if not already performed.

Target white coat negative systolic pressure of < 160 mmHg. If higher than this ACE-inhibitor is suggested to reach this level. Recheck echocardiogram is recommended in 6-12 months, earlier if murmur grade increases or clinical signs initiate.

Supportive care should prove effective.





PATIENT

Balto Lombardo

SPECIES

Canine

BREED

Pom

SEX

Neutered Male

AGE

8

WEIGHT

8

INTERPRETED BY

Eric Lindquist, DMV,
DABVP(CFM), Cert.
IVUSS

**IMAGING
PERFORMED BY**

Jenn

HOSPITAL NAME

Rockaway Animal
Hospital

REFERRING VET

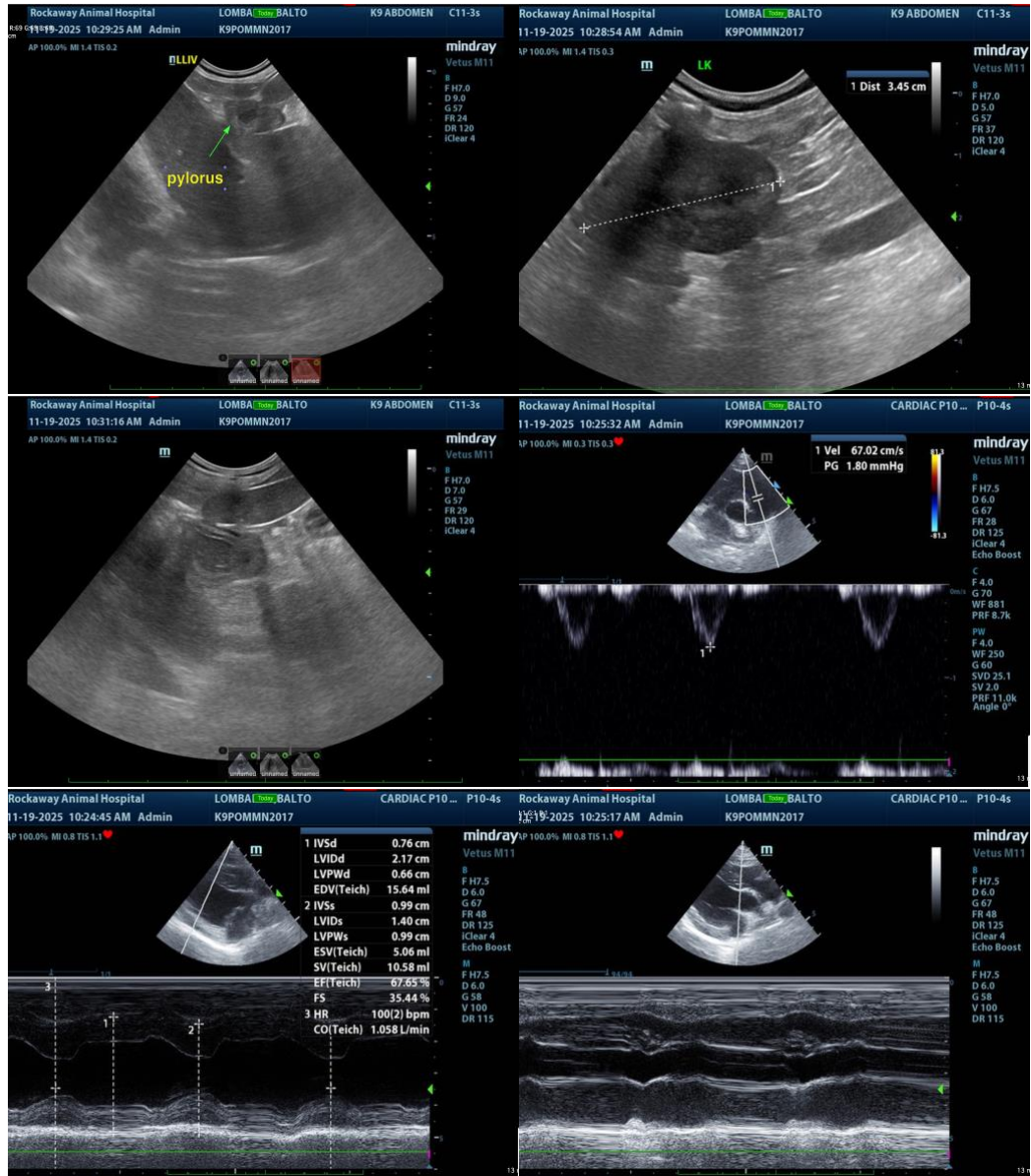
Dr. Maniar

INVOICE

12325

DATE

11/19/25



The information and recommendations provided are based on the images presented by the referring veterinarian/sonographer. No evaluation can be communicated regarding pathology that was not visible in the image/video clips provided.

Thank you for this referral. If the clinical or image interpretation does not parallel your findings or if I can be of any further assistance, please contact me.

Eric Lindquist, DMV, DABVP(CFM), Cert. IVUSS,

CEO, Owner, Founder -- SonoPath.com

info@SonoPath.com



PATIENT

Balto Lombardo

SPECIES

Canine

BREED

Pom

SEX

Neutered Male

AGE

8

WEIGHT

8

INTERPRETED BY

Eric Lindquist, DMV,
DABVP(CFM), Cert.
IVUSS

IMAGING PERFORMED BY

Jenn

HOSPITAL NAME

Rockaway Animal
Hospital

REFERRING VET

Dr. Maniar

INVOICE

12325

DATE

11/19/25