



PATIENT

Nala Alite

SPECIES

Canine

BREED

American PitBull

SEX

Spayed female

AGE

1 year

WEIGHT

90 lbs

INTERPRETED BY

Eric Lindquist, DMV
DABVP, Cert. IVUSS

IMAGING PERFORMED BY

Dr. Jeremiah Gabriel

HOSPITAL NAME

Central Jersey AH

REFERRING VET

Dr. Gabriel

INVOICE

68797

DATE

11/18/25

PRESENTING CLINICAL SIGNS

History: vomiting anorexic o thinks she ate a piece of plastic

ULTRASONOGRAPHIC EXAMINATION OF THE ABDOMEN

Urinary System

The **urinary bladder**, trigone, and pelvic urethra presented normal thicknesses and normal tone. The pelvic urethra was imaged 1.0 cm beyond the cystourethral junction and appeared normal. The ureters were not visible which is normal. No uroliths or sediment were visualized and anechoic urine was present. No evidence of inflammatory or neoplastic changes was noted. Ureteral papillae were normal.

The **kidneys** revealed normal size and structure, corticomedullary definition and ratio for this age. The cortices presented largely uniform texture with normal echogenic relationship to liver and spleen. Medullary structure differed distinctly from the cortex and no evidence of pelvic dilation was present. The capsules were acceptably uniform without significant irregularities. The left and right kidney measured 5.0 cm.

Adrenal Glands

The **adrenal glands** were not visualized.

Spleen

The **spleen** presented a smooth homogeneous parenchyma hyperechoic to liver and renal cortical parenchyma. The capsule was smooth without noticeable expansion or deviation from within the spleen or adjacent pathology. The splenic vasculature demonstrated normal volume without signs of congestion or thrombosis. No sonographic evidence of acute or chronic inflammatory, neoplastic, or infarctual changes was noted.

Liver

The **liver** images submitted revealed subjectively normal liver size, contour, and structure. Parenchymal echogenicity was naturally coarse and hypoechoic to the spleen. Vascular and biliary tracts were of normal volume with no evidence of congestion. The gallbladder presented acceptably thin walls with primarily anechoic content. The cystic and common bile ducts were normal. No pathological hepatic lymphadenopathy was evident. No overt structural evidence of inflammatory, infiltrative or regenerative pathology was evident.

Gastrointestinal

The **gastrointestinal** presentation revealed mild uniform prominence of the gastric mucosa as well as areas of "ropy" small intestinal wall with slight disruption of the normal 1:3 muscularis/mucosal ratio. The upper duodenum was not well visualized. The intestinal submucosa was slightly irregular, thickened



PATIENT

Nala Alite

SPECIES

Canine

BREED

American PitBull

SEX

Spayed female

AGE

1 year

WEIGHT

90 lbs

INTERPRETED BY

Eric Lindquist, DMV
DABVP, Cert. IVUSS

IMAGING PERFORMED BY

Dr. Jeremiah Gabriel

HOSPITAL NAME

Central Jersey AH

REFERRING VET

Dr. Gabriel

INVOICE

68797

DATE

11/18/25

and hyperechoic suggestive of low grade, chronic disease. No concerning lymphadenopathy was visible. Soft stool was noted in the colon. No obstructive or overt infiltrative disease was noted. The mesenteric lymph nodes were reactive and measured up to 2.0 x 1.0 cm.

Pancreas

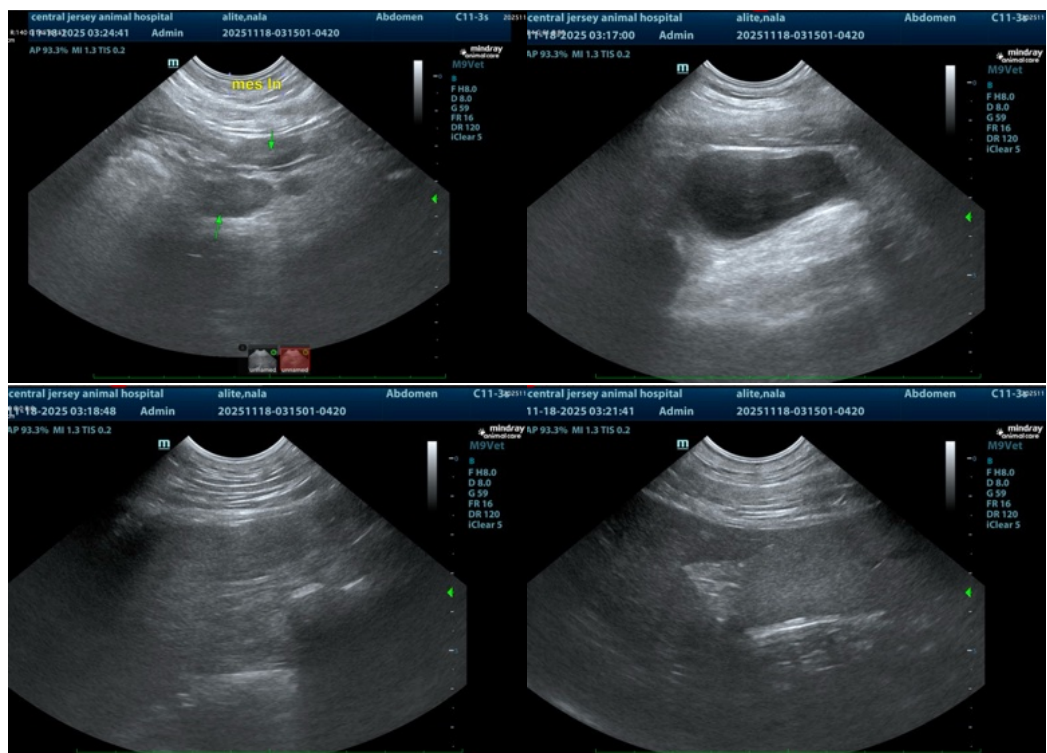
The base and limbs of the **pancreas** were observed to be largely isoechoic to surrounding omental fat. Pancreatic duct and capsular contour were acceptably normal and parenchyma respected normal curvilinear patterns. No overt evidence of active inflammatory or neoplastic disease was noted.

ULTRASONOGRAPHIC FINDINGS

Mild intestinal thickening with reactive mesenteric lymph nodes. No overt evidence of pathology. The upper duodenum was not well visualized, yet no obstructive patterns were noted.

INTERPRETATION OF THE FINDINGS & FURTHER RECOMMENDATIONS

Medical management is indicated. If clinical signs persist further imaging, possibly under sedation is recommended.





PATIENT

Nala Alite

SPECIES

Canine

BREED

American PitBull

SEX

Spayed female

AGE

1 year

WEIGHT

90 lbs

INTERPRETED BY

Eric Lindquist, DMV
DABVP, Cert. IVUSS

IMAGING PERFORMED BY

Dr. Jeremiah Gabriel

HOSPITAL NAME

Central Jersey AH

REFERRING VET

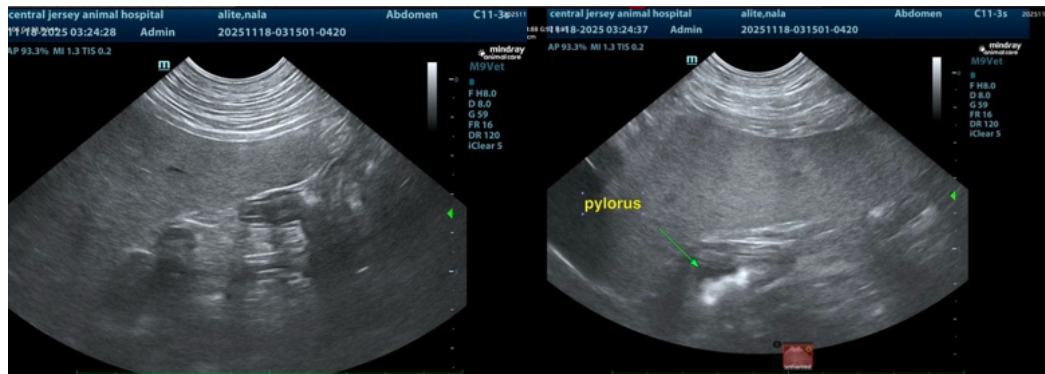
Dr. Gabriel

INVOICE

68797

DATE

11/18/25



The information and recommendations provided are based on the images presented by the referring veterinarian/sonographer. No evaluation can be communicated regarding pathology that was not visible in the image/video clips provided.

Thank you for this referral. If the clinical or image interpretation does not parallel your findings or if I can be of any further assistance please contact me.

Eric Lindquist, DMV, DABVP (CFM), Cert. IVUSS, CEO of SonoPath.com

info@SonoPath.com