



## PATIENT

Cooper Anisko

## SPECIES

Canine

## BREED

Border Collie Mix

## SEX

Neutered male

## AGE

15 years

## WEIGHT

30 lbs

## INTERPRETED BY

Eric Lindquist, DMV  
DABVP, Cert. IVUSS

## IMAGING PERFORMED BY

Jenn

## HOSPITAL NAME

Rockaway AH

## REFERRING VET

Dr. Maniar

## INVOICE

68770

## DATE

11/18/25

## PRESENTING CLINICAL SIGNS

History: recheck prev u/s 11/13

## ULTRASONOGRAPHIC EXAMINATION OF THE ABDOMEN

### Urinary System

The **urinary bladder**, trigone, and pelvic urethra presented normal thicknesses and normal tone. The pelvic urethra was imaged 2.0 cm beyond the cystourethral junction and appeared normal. The ureters were not visible which is normal. A minor amount of sand was noted and was non-obstructive. Grouping of sand measured approximately 1.5 cm. No evidence of inflammatory or neoplastic changes was noted. Ureteral papillae were normal.

The **kidneys** revealed largely normal size and structure, corticomedullary definition and ratio (cortex 1/3 of medulla) were essentially maintained with some age-related loss of curvilinear patterns regarding the capsule and C/M junction. The cortices presented largely uniform texture with some increased echogenicity expected for this age patient. Medullary structure differed distinctly from that of the cortex. Corticomedullary calculi were noted. The left kidney measured 4.52 cm with pyelectasia. The right kidney measured 4.5 cm. Power Doppler assessment was subnormal.

### Adrenal Glands

Both **adrenal glands** were visualized and recognized as having normal shape, size, position and echogenicity for this breed. The phrenic vasculature, glandular echogenicity and detail were unremarkable. Capsule, cortex, and medullary definition were normal for this age patient. The right adrenal gland measured 1.75 x 1.28 cm at the cranial pole and 0.7 cm at the caudal pole. The left adrenal gland measured 2.29 x 0.84 cm at the caudal pole and 0.85 cm at the cranial pole.

### Spleen

The **spleen** presented a smooth homogeneous parenchyma hyperechoic to liver and renal cortical parenchyma. The capsule was smooth without noticeable expansion or deviation from within the spleen or adjacent pathology. The splenic vasculature demonstrated normal volume without signs of congestion or thrombosis. No sonographic evidence of acute or chronic inflammatory, neoplastic, or infarctual changes was noted.

### Liver

The **liver** images from right and left intercostal as well as subcostal views revealed subjectively normal liver size, contour, and structure. Some age-related parenchymal remodeling was noted but likely not clinically significant at this time. Vascular and biliary tracts were of normal volume and no evidence of congestion was noted. The gallbladder presented some dependent debris with essentially normal contour. The cystic and common bile ducts were normal. No overt evidence of active inflammatory,



**PATIENT**

Cooper Anisko

**SPECIES**

Canine

**BREED**

Border Collie Mix

**SEX**

Neutered male

**AGE**

15 years

**WEIGHT**

30 lbs

**INTERPRETED BY**

Eric Lindquist, DMV  
DABVP, Cert. IVUSS

**IMAGING PERFORMED BY**

Jenn

**HOSPITAL NAME**

Rockaway AH

**REFERRING VET**

Dr. Maniar

**INVOICE**

68770

**DATE**

11/18/25

infiltrative or regenerative pathology was noted but should be paired with current or past LE elevations regarding any clinical significance to this presentation. The hepatic lymph nodes were unremarkable.

**Gastrointestinal**

Examination of the **gastrointestinal tract** revealed an unremarkable stomach regarding structure. There were minor areas of luminal fluid noted. There was no evidence of obstructive pattern. Small intestinal thickening was noted with reactive mesentery. Curvilinear patterns were retained throughout the gastrointestinal tract. Areas of hyperperistalsis were noted. This is consistent with response to irritation. The colon was unremarkable.

**Pancreas**

The base and limbs of the **pancreas** were observed to be largely isoechoic to surrounding omental fat. Pancreatic duct and capsular contour were acceptably normal and parenchyma respected normal curvilinear patterns. No overt evidence of active inflammatory or neoplastic disease was noted.

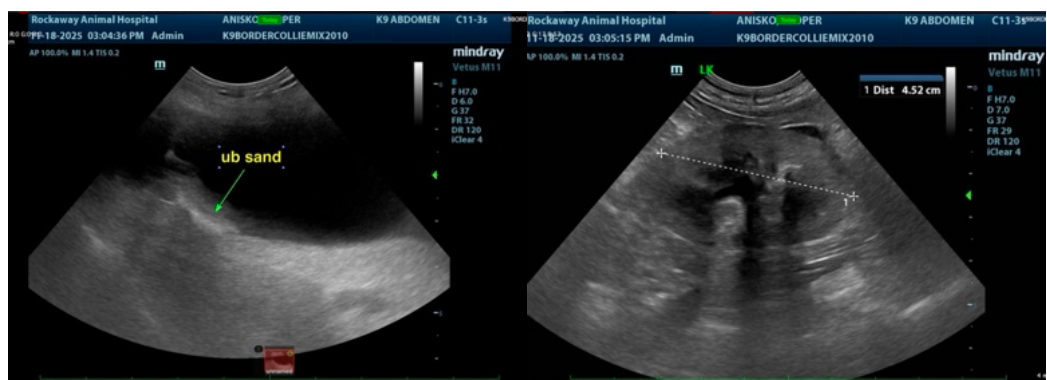
**ULTRASONOGRAPHIC FINDINGS**

Polycystic cortical renal changes were noted with slight subcapsular fluid accumulation. Dystrophic mineralization on right kidney.

Gastroenteritis presentation with reactive mesentery.

**INTERPRETATION OF THE FINDINGS & FURTHER RECOMMENDATIONS**

I am most concerned about the long term viability of the kidneys and gastrointestinal presentation. Management for gastrointestinal upset is indicated.





## PATIENT

Cooper Anisko

## SPECIES

Canine

## BREED

Border Collie Mix

## SEX

Neutered male

## AGE

15 years

## WEIGHT

30 lbs

## INTERPRETED BY

Eric Lindquist, DMV  
DABVP, Cert. IVUSS

## IMAGING PERFORMED BY

Jenn

## HOSPITAL NAME

Rockaway AH

## REFERRING VET

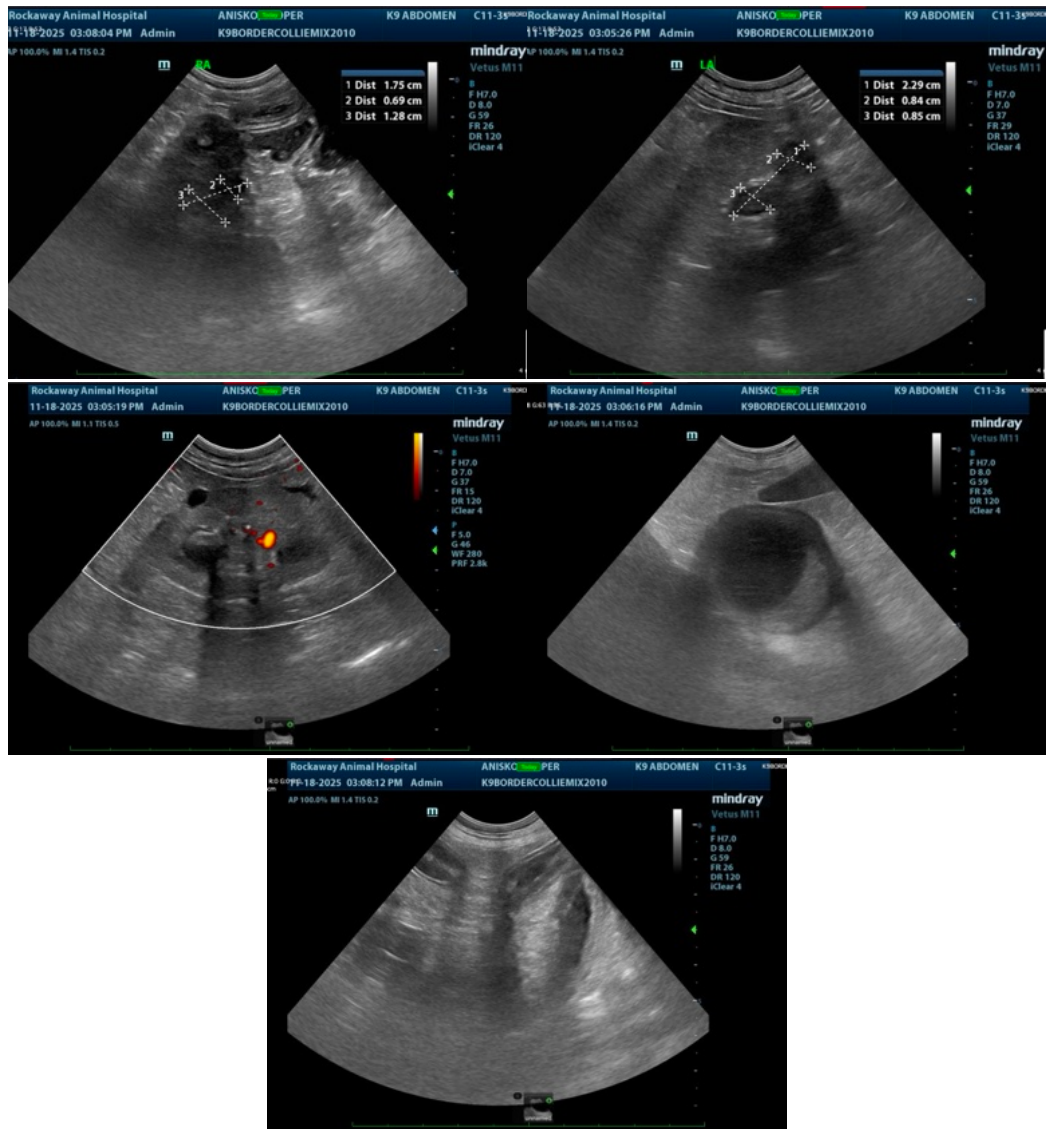
Dr. Maniar

## INVOICE

68770

## DATE

11/18/25



The information and recommendations provided are based on the images presented by the referring veterinarian/sonographer. No evaluation can be communicated regarding pathology that was not visible in the image/video clips provided.

Thank you for this referral. If the clinical or image interpretation does not parallel your findings or if I can be of any further assistance please contact me.

Eric Lindquist, DMV, DABVP (CFM), Cert. IVUSS, CEO of SonoPath.com

[info@SonoPath.com](mailto:info@SonoPath.com)