



**PATIENT**

Alie Cammarata

**SPECIES**

Canine

**BREED**

Dachshund x

**SEX**

Spayed Female

**AGE**

12 Years 2 Months

**WEIGHT**

20 lbs

**INTERPRETED BY**

Eric Lindquist, DMV,  
DABVP (CFM), Cert.  
IVUSS

**IMAGING PERFORMED BY**

Kerri Becker

**HOSPITAL NAME**

Legacy Animal Hospital

**REFERRING VET**

Dr. Potenzzone

**INVOICE**

71928

**DATE**

11/18/25

**PRESENTING CLINICAL SIGNS**

Coughing, elev. RR, panting, HM/ cardiomegaly. No pleural effusion. Meds- CBD, enalapril, pimo, vetmedin, gaba, lasix, thyroid tabs

Abnormal PE/Chem/CBC/UA Results: July 2025 ALP-1327 ALT-198 ABD US normal adrenals stim neg urine normal.

**ULTRASONOGRAPHIC EXAMINATION OF THE HEART**

CANINE CARDIAC PARAMETERS	MR VMAX (m/s)	TR VMAX (m/s)	LA/AO (M-Mode)	LA/AO (Heart Base; Swe)	FS (%)	EF (%)	EPSS (cm)
NORMAL PARAMETER	4.5-5.5	<2.7	1.3	Up to 1.6	28-40	40-100	<0.6
PATIENT	6.2	--	2.28	2.24			0.1
CANINE CARDIAC PARAMETERS	HR (BPM)	AV VMAX (m/s)	PV MAX (m/s)	BODY WEIGHT (lbs)	LAD LA MAX 4 Chamber	LVIDd Avg; 2D and m-mode short axis (cm)	LVIDs Avg; 2D and m-mode short axis (cm)
NORMAL PARAMETER	50-100	0.7-1.7	0.7-1.6				
PATIENT		1.9		20	4.9		

**Cardiac Presentation**

The cardiac presentation is significantly decompensated from the prior sonogram. Moderate to severe left atrial enlargement noted with mitral and tricuspid insufficiency and prolapse of the anterior mitral valve leaflet. Tachycardia noted with volume overload of the left heart. Hepatic veins were not dilated. No evidence of pulmonary hypertension. No pericardial effusions.

**ULTRASONOGRAPHIC FINDINGS**

- Progressive volume overload, Stage C1 valvular disease.

**INTERPRETATION OF THE FINDINGS & FURTHER RECOMMENDATIONS**

Recommend maximizing Pimobendan at 0.25-0.30 mg TID, Enalapril 0.5 mg/kg BID, adding Spironolactone at 1-2 mg/kg SID, and increasing Lasix dose by 1-2 mg/kg BID, and monitoring blood pressures. If hypertension is present, Telmisartan could also be considered. Renal values should be monitored carefully as well as blood pressure. Prognosis is guarded. EKG indicated. Recheck echo in one month, earlier if clinical signs progress. Any coughing may be controlled with hydrocodone.

The heart is in a somewhat precarious state with volume overload and a heart that is working to compensate for the valvular insufficiency. Target respiratory rate is < 20 resp/minute after therapy. After initiating therapy, I recommend recheck on the clinical exam, BUN, Creatinine, USG, Chest radiographs & Blood pressure in 5-7 days. Recheck echo in 1 month. Earlier if clinical decompensation is



**PATIENT**

Alie Cammarata

**SPECIES**

Canine

**BREED**

Dachshund x

**SEX**

Spayed Female

**AGE**

12 Years 2 Months

**WEIGHT**

20 lbs

**INTERPRETED BY**

Eric Lindquist, DMV,  
 DABVP (CFM), Cert.  
 IVUSS

**IMAGING PERFORMED BY**

Kerri Becker

**HOSPITAL NAME**

Legacy Animal Hospital

**REFERRING VET**

Dr. Potenzone

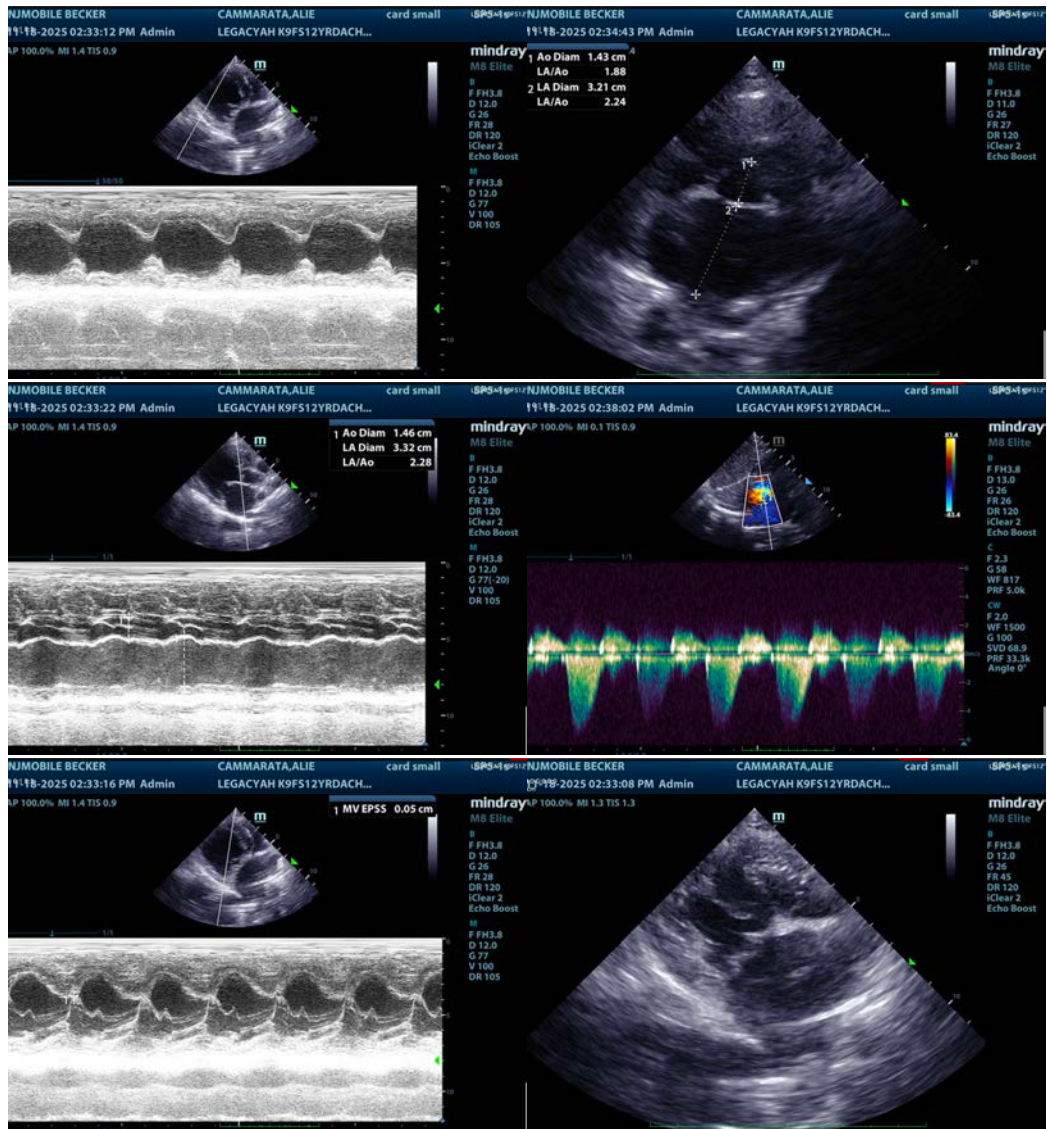
**INVOICE**

71928

**DATE**

11/18/25

occurring, I do not recommend anesthesia at this time until stabilization has occurred on the recommended medications. Repeat preanesthetic echo is ideal if anesthesia is eventually necessary. There is severe anesthetic risk for this patient. Light dose opioids may be used to calm but I do not recommend anesthesia.





**PATIENT**

Alie Cammarata

**SPECIES**

Canine

**BREED**

Dachshund x

**SEX**

Spayed Female

**AGE**

12 Years 2 Months

**WEIGHT**

20 lbs

**INTERPRETED BY**

Eric Lindquist, DMV,  
 DABVP (CFM), Cert.  
 IVUSS

**IMAGING PERFORMED BY**

Kerri Becker

**HOSPITAL NAME**

Legacy Animal Hospital

**REFERRING VET**

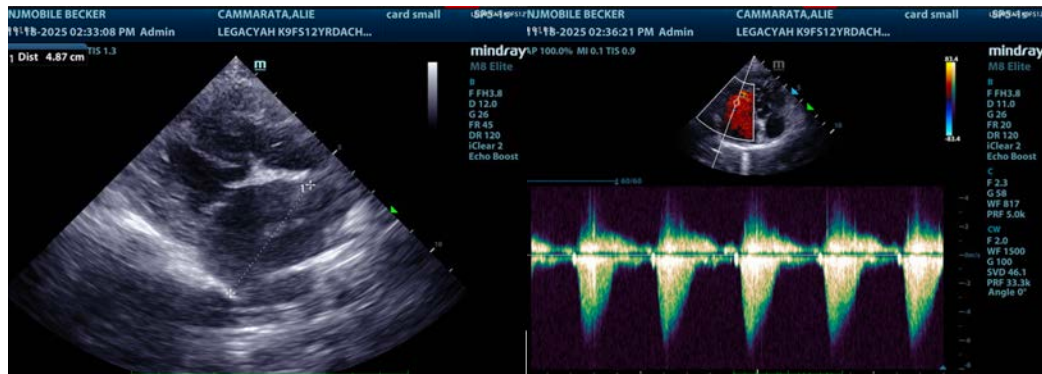Dr. Potenzzone

**INVOICE**

71928

**DATE**

11/18/25



The information and recommendations provided are based on the images presented by the referring veterinarian/sonographer. No evaluation can be communicated regarding pathology that was not visible in the image/video clips provided.

Thank you for this referral. If the clinical or image interpretation does not parallel your findings or if I can be of any further assistance please contact me.

**Eric Lindquist**, DMV, DABVP(CFM), Cert. IVUSS,  
 CEO, Owner, Founder -- SonoPath.com  
[info@SonoPath.com](mailto:info@SonoPath.com)