

**DATE PRESENTING CLINICAL SIGNS**

11/18/22

Controlled diabetic. Recently losing weight, decreased appetite, lethargy, increased urination. Hx of atopic dermatitis.

PATIENT

Rocky Henry

Current Medications: Starting Clavamox 13.75mg/kg BID, Denamarin SID.

Lab Results: CBC WNL. Chem- ALT 283, ALKP 719, BUN 37, Glu 85. UA- Cocci, no glucose or ketones. Urine culture pending.

SPECIES

Canine

Date of Previous IntraPet Ultrasound: No previous.

Sedation: Not required to complete full diagnostic ultrasound.

Stat Report: Not requested.

BREED

Miniature Pinscher

ULTRASONOGRAPHIC EXAMINATION OF THE ABDOMEN**SEX**

Intact Male

Urinary System

The **urinary bladder**, trigone, and pelvic urethra presented normal thicknesses and normal tone. The ureters were not visible which is normal. No uroliths or sediment were visualized, and anechoic urine was present. No evidence of inflammatory or neoplastic changes were noted. Ureteral papillae were normal.

AGE

4/18/09

The **prostate** was slightly heterogenous, measuring 2.6 cm, consistent with BPH.

WEIGHT

13.8 Pounds

The **kidneys** revealed largely normal size and structure, corticomedullary definition and ratio (cortex 1/3 of medulla) were essentially maintained with some moderate age-related loss of curvilinear patterns regarding the capsule and C/M junction. The cortices presented largely uniform texture with some increased echogenicity expected for his age patient. Medullary structure differed distinctly from that of the cortex and no evidence of pelvic dilation was present. The left kidney measured 4.63 cm. The right kidney measured 5.21 cm.

INTERPRETED BY

Eric Lindquist, DMV
DABVP, Cert. IVUSS

Adrenal Glands

Both **adrenal glands** were visualized and recognized as having normal shape, size, position and echogenicity for this breed. The phrenic vasculature, glandular echogenicity and detail were unremarkable. Capsule, cortex, and medullary definition were normal for this age patient. The left adrenal gland measured 2.06 cm x 0.76 cm at the caudal pole and 0.74 cm at the cranial pole. The right adrenal gland measured 2.77 cm x 0.57 cm at the caudal pole and 0.64 cm at the cranial pole.

IMAGING PERFORMED BY

Rachel Brillhart RDMS

Spleen

The **spleen** presented a smooth homogeneous parenchyma hyperechoic to liver and renal cortical parenchyma. The capsule was smooth without noticeable expansion or deviation from within the spleen or adjacent pathology. The splenic vasculature demonstrated normal volume without signs of congestion or thrombosis. No sonographic evidence of acute or chronic inflammatory, neoplastic, or infarctual changes were noted. Caudal folding of the spleen was noted.

HOSPITAL NAME

Banfield Timonium

REFERRING VET

Dr. Adu

Liver

The **liver** was uniformly swollen with minor, excessive gallbladder debris and over distension with dependent and suspended bile without evidence of overt mucocele formation. However, excessive sludge was present. The liver presented coarse architecture with mildly increased portal markings and subtle, mixed echogenic changes. This is consistent with vacuolar hepatopathy and some level of remodeling and history of inflammatory component. There was no overt suspicion of neoplasia. This is a moderate change.

INVOICE

18143

Gastrointestinal

Some retention of ingesta was noted in the **stomach**. Some level of delayed outflow appears to be present. The small intestine and colon were unremarkable.

Pancreas

The **pancreas** was hypochoic and irregular with coarse architecture and enhanced surrounding mesentery, suggestive for inflammation.

Other

The **testicles** were imaged and found to be fairly uniform. A minor amount of remodeling was noted. The testicles measured approximately 2.0 cm each.

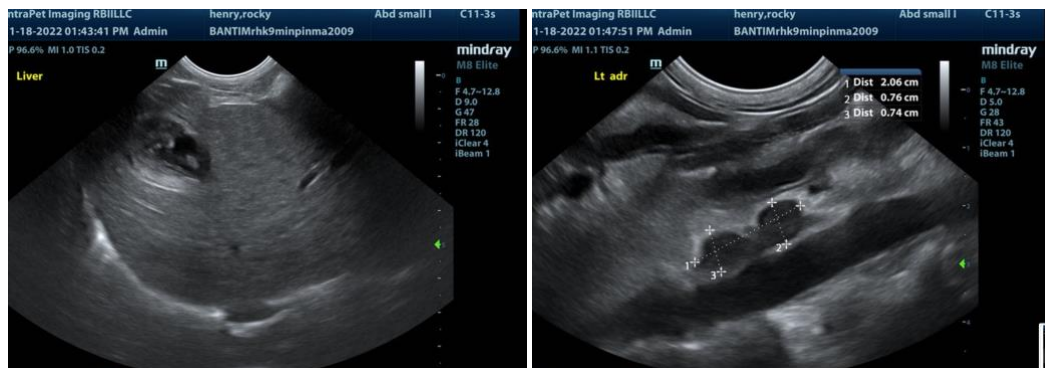
ULTRASONOGRAPHIC FINDINGS

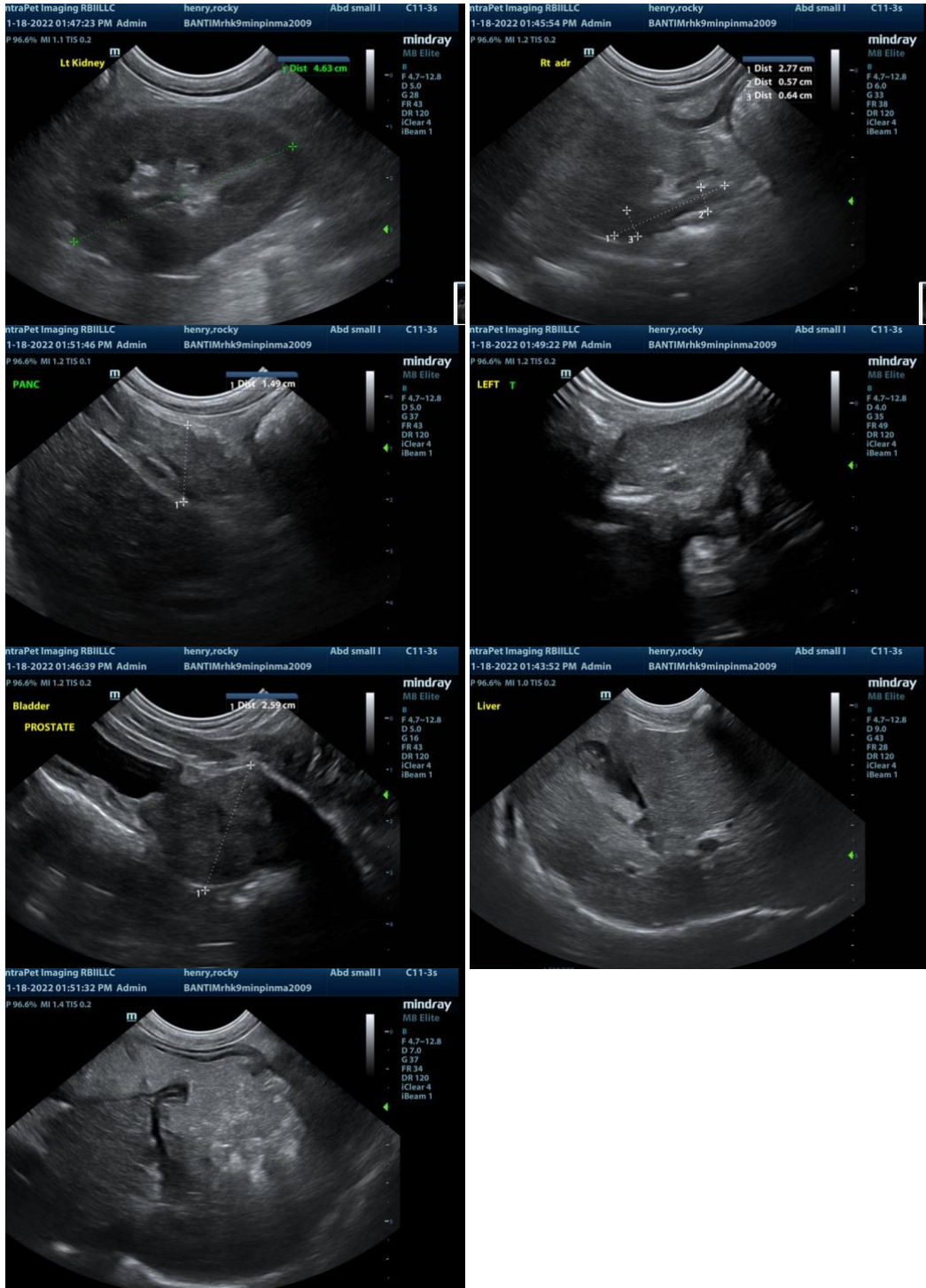
- Suspected low grade pancreatitis
- Benign hepatopathy
- Age-related renal changes
- Minor BPH prostate
- Minor remodeled testicles
- Stomach ingesta

INTERPRETATION OF THE FINDINGS & FURTHER RECOMMENDATIONS

FNA of the liver could be considered for further definition. The pancreatic presentation could be responsible for the poor appetite. Structurally the adrenal glands measure normally, however, emerging PDH is a potential. If urine specific gravity is <1.020 and the patient appears cushingoid, eventual work up for PDH/Cushing's is indicated. However, no evidence of neoplasia is noted or obvious cause of weight loss.

Maldigestion panel, three view chest radiographs and full CNS examination is recommended to examine for occult disease that could be responsible for the weight loss. Evaluation for competitive eating environments should also be considered.





The information and recommendations provided are based on the images presented by the referring veterinarian/sonographer. No evaluation can be communicated regarding pathology that was not visible in the image/video clips provided.

Thank you for this referral. If the clinical or image interpretation does not parallel your findings or if I can be of any further assistance please contact me.

Eric Lindquist, DMV, DABVP, Cert. IVUSS, CEO of SonoPath.com
info@SonoPath.com