



PATIENT

Rocky Alcibar

SPECIES

Feline

BREED

Domestic Shorthair

SEX

Neutered male

AGE

4 years

WEIGHT

16 lbs

INTERPRETED BY

Eric Lindquist, DMV
DABVP, Cert. IVUSS

IMAGING PERFORMED BY

Dr. Leal

HOSPITAL NAME

Wellesley AH

REFERRING VET

Dr. Dean

INVOICE

68723

DATE

11/17/25

PRESENTING CLINICAL SIGNS

History: Pt presents for evaluation of a broken tooth. Pt noted as having a grade II/VI parasternal systolic murmur. Pt scheduled for a COHAT. Pt had butorphanol/alfaxalone to facilitate radiographs of the fractured canine. Screening performed after radiographs.
Abnormal PE/Chem/CBC/UA Results: PE: BCS 7/9; 2/6 parasternal systolic murmur, significant dental dz with fractured 104,

ULTRASONOGRAPHIC EXAMINATION OF THE HEART

8 efficiency video clips from SDEP protocol provided.

All four chambers revealed normal volumes and contractility. No evidence of volume overload nor pressure overload. No pericardial or pleural effusion noted.

No gross abnormalities that would preclude anesthesia.

ULTRASONOGRAPHIC FINDINGS

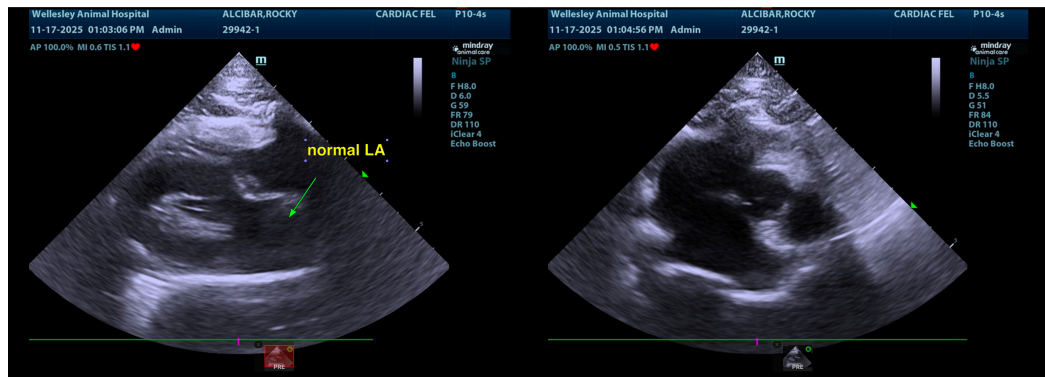
- Normal pre-anesthetic echocardiogram.

INTERPRETATION OF THE FINDINGS & FURTHER RECOMMENDATIONS

The cause of murmur is unknown, yet likely flow murmur.

Anesthetic risk is considered minimal: No gross abnormalities noted on SDEP^R Screening Echo to contraindicate anesthesia. No volume overload noted on the images presented.

1. Monitoring of blood pressure, SpO₂, CO₂, and auscultation of heart and lungs during anesthesia should be done during every procedure.





PATIENT

Rocky Alcibar

SPECIES

Feline

BREED

Domestic Shorthair

SEX

Neutered male

AGE

4 years

WEIGHT

16 lbs

INTERPRETED BY

Eric Lindquist, DMV
DABVP, Cert. IVUSS

IMAGING PERFORMED BY

Dr. Leal

HOSPITAL NAME

Wellesley AH

REFERRING VET

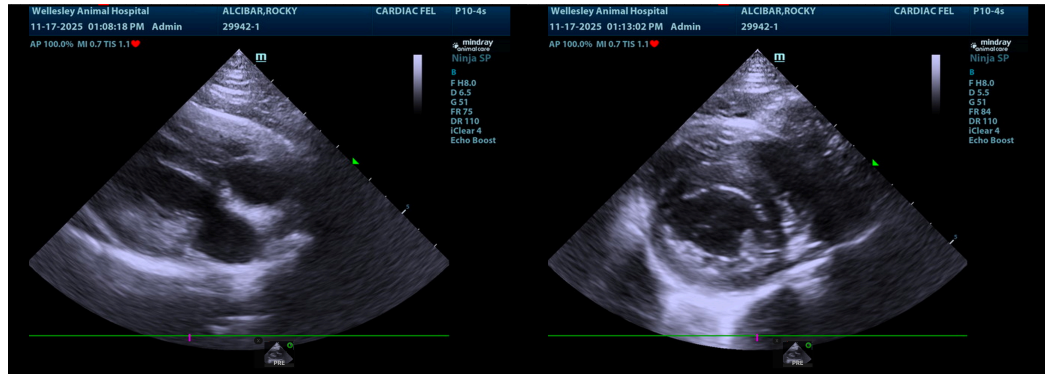
Dr. Dean

INVOICE

68723

DATE

11/17/25



The information and recommendations provided are based on the images presented by the referring veterinarian/sonographer. No evaluation can be communicated regarding pathology that was not visible in the image/video clips provided.

Thank you for this referral. If the clinical or image interpretation does not parallel your findings or if I can be of any further assistance please contact me.

Eric Lindquist, DMV, DABVP (CFM), Cert. IVUSS, CEO of SonoPath.com

info@SonoPath.com