



PATIENT

Penny Bartoo

SPECIES

Canine

BREED

Goldendoodle

SEX

Spayed Female

AGE

11 Years 4 Months

WEIGHT

65 lbs

INTERPRETED BY

Eric Lindquist, DMV,
DABVP (CFM), Cert.
IVUSS

IMAGING PERFORMED BY

Not Provided

HOSPITAL NAME

Bayside Animal
Medical Center.

REFERRING VET

Not Provided

INVOICE

71884

DATE

11/17/25

PRESENTING CLINICAL SIGNS

increasingly hind end weakness/muscle wasting; on exam suspected abdominal mass palpated; O opts for US to screen for abnormal pathology; P was fasted for US scan, no sedation needed

Abnormal PE/Chem/CBC/UA Results: Attached

ULTRASONOGRAPHIC EXAMINATION OF THE ABDOMEN

Urinary System

The **urinary bladder**, trigone, and pelvic urethra presented normal thicknesses and normal tone. The ureters were not visible which is normal. No uroliths or sediment were visualized and anechoic urine was present. No evidence of inflammatory or neoplastic changes were noted. Ureteral papillae were normal.

The **kidneys** revealed normal size and structure, corticomedullary definition and ratio for this age. The cortices presented largely uniform texture with normal echogenic relationship to liver and spleen. Medullary structure differed distinctly from the cortex and no evidence of pelvic dilation was present. The capsules were acceptably uniform without significant irregularities. The right kidney measured 6.6 cm. The left kidney measured 6.17 cm.

Adrenal Glands

Both **adrenal glands** were visualized and recognized as having normal shape, size, position and echogenicity for this breed. The phrenic vasculature, glandular echogenicity and detail were unremarkable. Capsule, cortex, and medullary definition were normal for this age patient. The right adrenal gland measured 1.0 cm at the caudal pole and 0.82 cm at the cranial pole. The left adrenal gland measured 0.71 cm at the caudal pole and 0.67 cm at the cranial pole.

Spleen

The **spleen** presented a smooth homogeneous parenchyma hyperechoic to liver and renal cortical parenchyma. The capsule was smooth without noticeable expansion or deviation from within the spleen or adjacent pathology. The splenic vasculature demonstrated normal volume without signs of congestion or thrombosis. No sonographic evidence of acute or chronic inflammatory, neoplastic, or infarctual changes were noted.

Liver

The **liver** images from right and left intercostal as well as subcostal views revealed subjectively normal liver size, contour, and structure. Some age-related parenchymal remodeling was noted but likely not clinically significant at this time. Vascular and biliary tracts were of normal volume and no evidence of congestion was noted. The gallbladder presented some dependent debris with essentially normal contour. The cystic and common bile ducts were normal. No overt evidence of active inflammatory, infiltrative or regenerative pathology was noted but should be paired with current or past LE elevations regarding any clinical significance to this presentation. The hepatic lymph nodes were unremarkable.

Gastrointestinal

Examination of the **gastrointestinal tract** revealed a stomach and intestine free of stasis, of normal wall thickness, acceptable curvilinear mural detail, and peristaltic activity. Small and large intestine



PATIENT

Penny Bartoo

SPECIES

Canine

BREED

Goldendoodle

SEX

Spayed Female

AGE

11 Years 4 Months

WEIGHT

65 lbs

INTERPRETED BY

Eric Lindquist, DMV,
DABVP (CFM), Cert.
IVUS

IMAGING PERFORMED BY

Not Provided

HOSPITAL NAME

Bayside Animal
Medical Center.

REFERRING VET

Not Provided

INVOICE

71884

DATE

11/17/25

demonstrated normal luminal chyme and stool consistency respectively. No obstructive or overt infiltrative disease was noted. No associated abnormal lymphatic activity was noted.

Pancreas

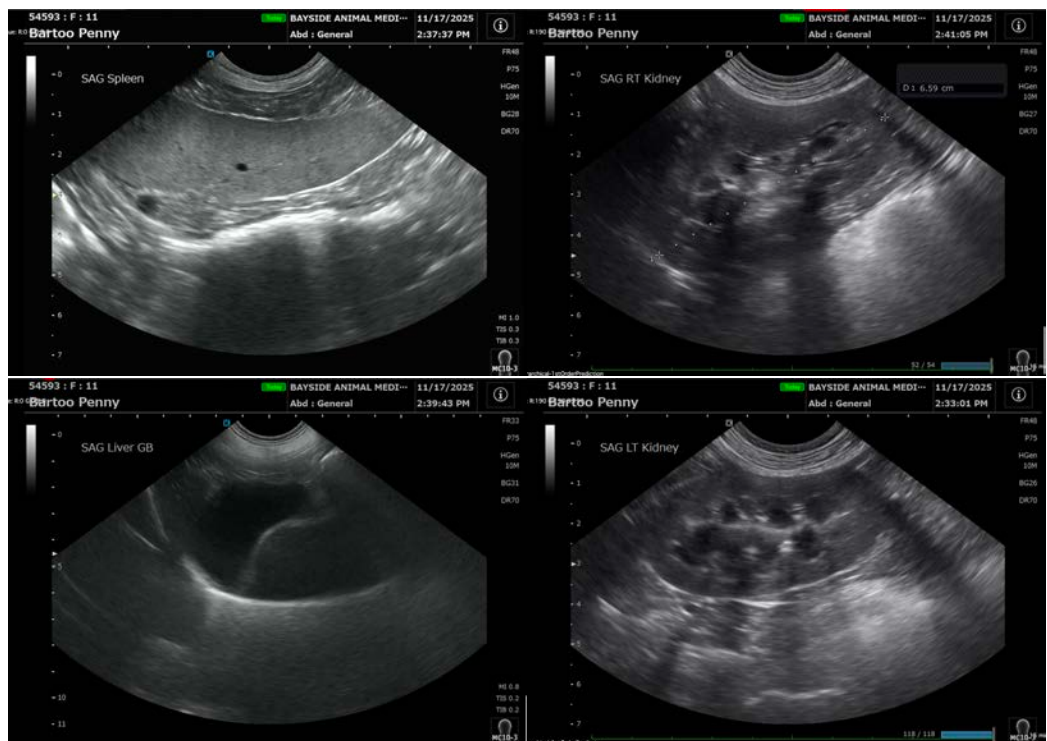
The base and limbs of the **pancreas** were observed to be largely isoechoic to surrounding omental fat. Pancreatic duct and capsular contour were acceptably normal and parenchyma respected normal curvilinear patterns. No overt evidence of active inflammatory or neoplastic disease was noted.

ULTRASONOGRAPHIC FINDINGS

- Age related hepatic changes, unremarkable abdomen otherwise.

INTERPRETATION OF THE FINDINGS & FURTHER RECOMMENDATIONS

Structurally unremarkable abdomen. No evidence of visceral disease responsible for the clinical signs. Given the vague clinical signs, screening for orthopedic pain related disease, CNS or thoracic disease should be considered. No evidence of masses.





PATIENT

Penny Bartoo

SPECIES

Canine

BREED

Goldendoodle

SEX

Spayed Female

AGE

11 Years 4 Months

WEIGHT

65 lbs

INTERPRETED BY

Eric Lindquist, DMV,
DABVP (CFM), Cert.
IVUSS

IMAGING PERFORMED BY

Not Provided

HOSPITAL NAME

Bayside Animal
Medical Center.

REFERRING VET

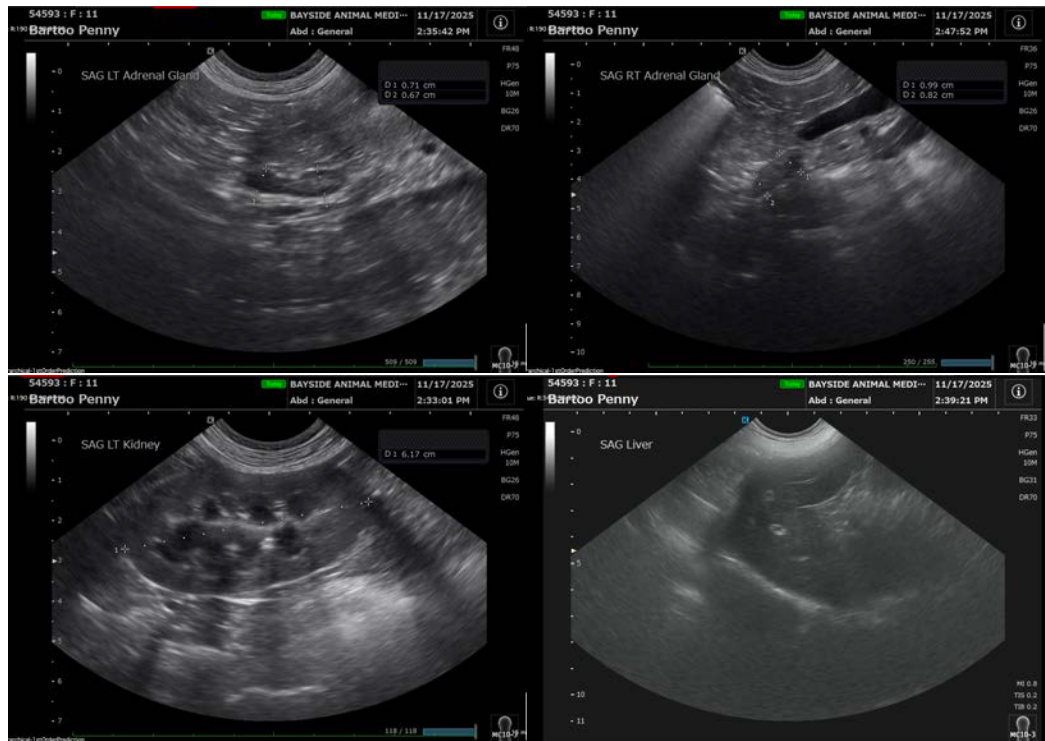Not Provided

INVOICE

71884

DATE

11/17/25



The information and recommendations provided are based on the images presented by the referring veterinarian/sonographer. No evaluation can be communicated regarding pathology that was not visible in the image/video clips provided.

Thank you for this referral. If the clinical or image interpretation does not parallel your findings or if I can be of any further assistance please contact me.

Eric Lindquist, DMV, DABVP(CFM), Cert. IVUSS,
CEO, Owner, Founder -- SonoPath.com
info@SonoPath.com