



PATIENT

Nikita Keating

SPECIES

Canine

BREED

Shiba Mix

SEX

Spayed female

AGE

13 years

WEIGHT

48 lbs

INTERPRETED BY

Eric Lindquist, DMV
DABVP, Cert. IVUSS

IMAGING PERFORMED BY

Dr. Petrone

HOSPITAL NAME

Long Branch AH

REFERRING VET

Dr. Petrone

INVOICE

68713

DATE

11/17/25

PRESENTING CLINICAL SIGNS

History: Geriatric dog with marked dental disease. ALP increased from 350 to 1490 in 1 year. ALT normal, clinically doing well.

ULTRASONOGRAPHIC EXAMINATION OF THE ABDOMEN

Urinary System

The **urinary bladder**, trigone, and pelvic urethra presented normal thicknesses and normal tone. The ureters were not visible which is normal. No uroliths or sediment were visualized and anechoic urine was present. No evidence of inflammatory or neoplastic changes was noted. Ureteral papillae were normal.

The **kidneys** revealed normal size and structure, corticomedullary definition and ratio for this age. The cortices presented largely uniform texture with normal echogenic relationship to liver and spleen. Medullary structure differed distinctly from the cortex and no evidence of pelvic dilation was present. The capsules were acceptably uniform without significant irregularities. The left kidney measured 5.56 cm. The right kidney measured 5.1 cm.

Adrenal Glands

Both **adrenal glands** were visualized and recognized as having normal shape, size, position and echogenicity for this breed. The phrenic vasculature, glandular echogenicity and detail were unremarkable. Capsule, cortex, and medullary definition were normal for this age patient. The left adrenal gland measured 0.75 cm. The right adrenal gland measured 0.6 cm at the cranial pole and 0.4 cm at the caudal pole.

Spleen

The **spleen** presented a smooth homogeneous parenchyma hyperechoic to liver and renal cortical parenchyma. The capsule was smooth without noticeable expansion or deviation from within the spleen or adjacent pathology. The splenic vasculature demonstrated normal volume without signs of congestion or thrombosis. No sonographic evidence of acute or chronic inflammatory, neoplastic, or infarctual changes was noted.

Liver

The **liver** images from right and left intercostal as well as subcostal views revealed subjectively normal liver size, contour, and structure. Some age-related parenchymal remodeling was noted but likely not clinically significant at this time. Vascular and biliary tracts were of normal volume and no evidence of congestion was noted. The gallbladder presented some dependent debris with essentially normal contour. Minor, physiological gallbladder content was noted. This is normal for an n.p.o. patient. The



PATIENT

Nikita Keating

SPECIES

Canine

BREED

Shiba Mix

SEX

Spayed female

AGE

13 years

WEIGHT

48 lbs

INTERPRETED BY

Eric Lindquist, DMV
DABVP, Cert. IVUSS

IMAGING PERFORMED BY

Dr. Petrone

HOSPITAL NAME

Long Branch AH

REFERRING VET

Dr. Petrone

INVOICE

68713

DATE

11/17/25

cystic and common bile ducts were normal. No overt evidence of active inflammatory, infiltrative or regenerative pathology was noted but should be paired with current or past LE elevations regarding any clinical significance to this presentation. The hepatic lymph nodes were unremarkable.

Gastrointestinal

Examination of the **gastrointestinal tract** revealed a stomach and intestine free of stasis, of normal wall thickness, acceptable curvilinear mural detail, and peristaltic activity. Small and large intestine demonstrated normal luminal chyme and stool consistency respectively. No obstructive or overt infiltrative disease was noted. No associated abnormal lymphatic activity was noted.

Pancreas

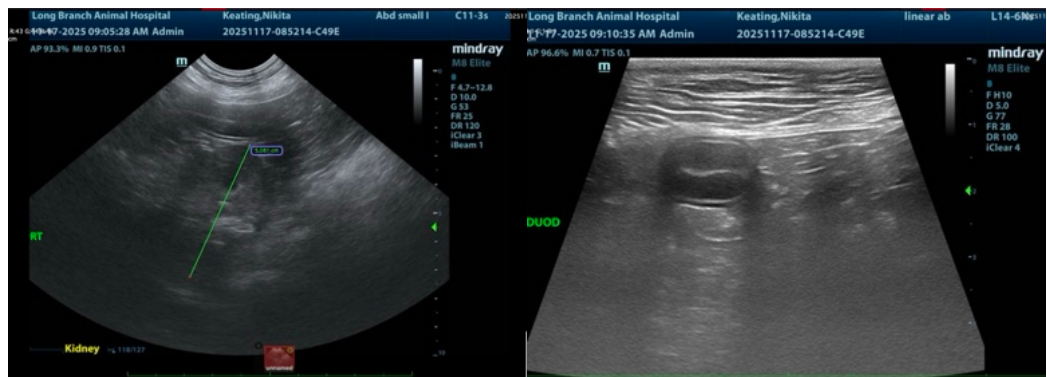
The base and limbs of the **pancreas** were observed to be largely isoechoic to surrounding omental fat. Pancreatic duct and capsular contour were acceptably normal and parenchyma respected normal curvilinear patterns. No overt evidence of active inflammatory or neoplastic disease was noted.

ULTRASONOGRAPHIC FINDINGS

- Age related abdominal changes, no contraindication to anesthetic procedure.

INTERPRETATION OF THE FINDINGS & FURTHER RECOMMENDATIONS

There is no necessity for Ursodiol or other treatment. There is no contraindication to anesthetic procedure.





PATIENT

Nikita Keating

SPECIES

Canine

BREED

Shiba Mix

SEX

Spayed female

AGE

13 years

WEIGHT

48 lbs

INTERPRETED BY

Eric Lindquist, DMV
DABVP, Cert. IVUSS

IMAGING PERFORMED BY

Dr. Petrone

HOSPITAL NAME

Long Branch AH

REFERRING VET

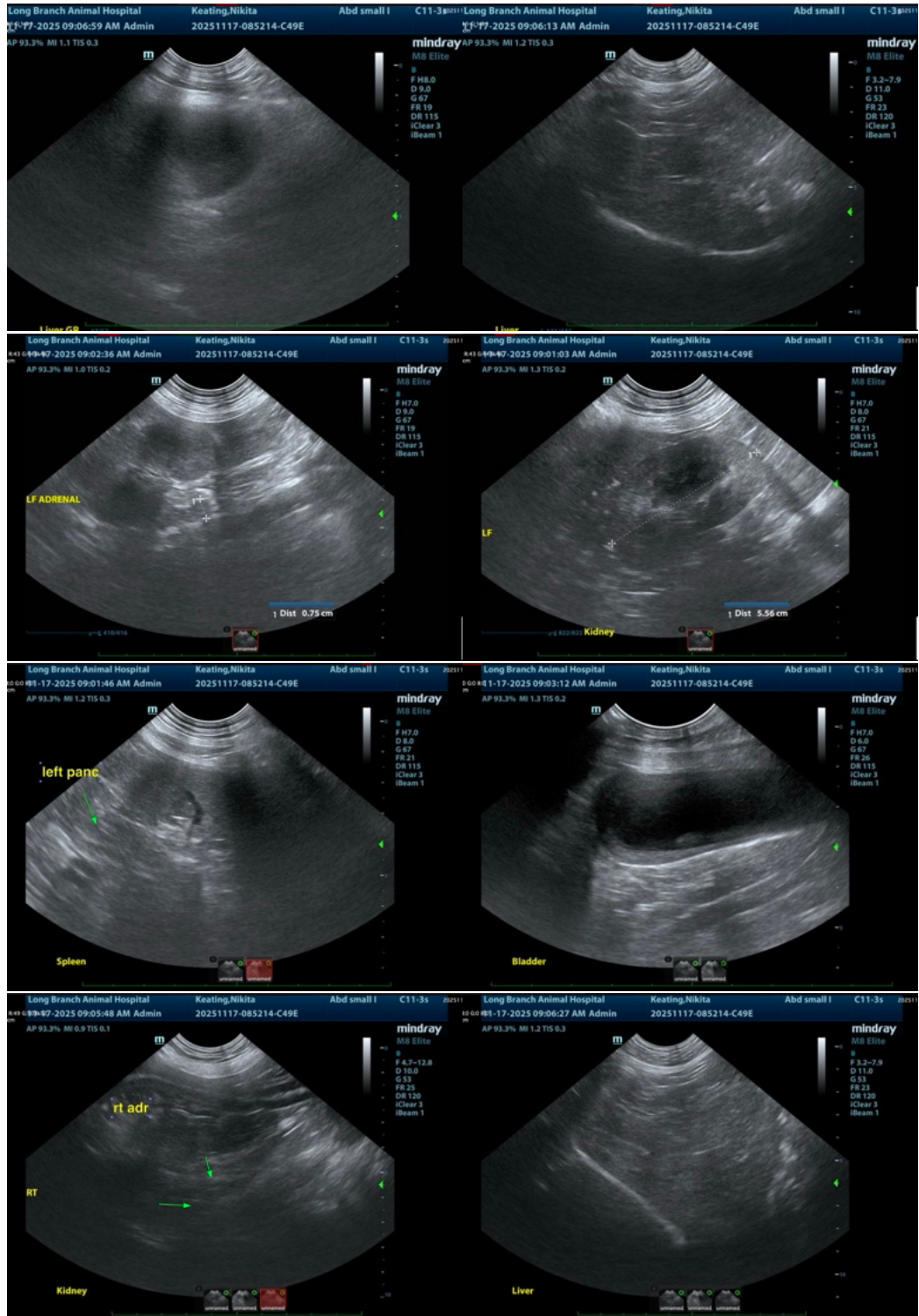
Dr. Petrone

INVOICE

68713

DATE

11/17/25





PATIENT

Nikita Keating

The information and recommendations provided are based on the images presented by the referring veterinarian/sonographer. No evaluation can be communicated regarding pathology that was not visible in the image/video clips provided.

SPECIES

Canine

Thank you for this referral. If the clinical or image interpretation does not parallel your findings or if I can be of any further assistance please contact me.

BREED

Shiba Mix

Eric Lindquist, DMV, DABVP (CFM), Cert. IVUSS, CEO of SonoPath.com

SEX

Spayed female

AGE

13 years

WEIGHT

48 lbs

INTERPRETED BY

Eric Lindquist, DMV
DABVP, Cert. IVUSS

IMAGING PERFORMED BY

Dr. Petrone

HOSPITAL NAME

Long Branch AH

REFERRING VET

Dr. Petrone

INVOICE

68713

DATE

11/17/25