



PATIENT

Milo Madigan

SPECIES

Feline

BREED

Domestic Shorthair

SEX

Neutered male

AGE

9 years

WEIGHT

14 lbs

INTERPRETED BY

Eric Lindquist, DMV
DABVP, Cert. IVUSS

IMAGING PERFORMED BY

Dr. Leal

HOSPITAL NAME

Wellesley AH

REFERRING VET

Dr. Bunn

INVOICE

68724

DATE

11/17/25

PRESENTING CLINICAL SIGNS

History: Pt presents for pre-anesthetic screening echo prior to COHAT next week. Pt problem list: mild HCM diagnosed in April 2025, hypertension (well controlled), CKD IRIS stage 2, Overconditioned, Dental Dz. Medications: Amlodipine (0.625mg PO SID), gabapentin PRN
Abnormal PE/Chem/CBC/UA Results: PE: BCS 7/9, significant dental disease, 4/6 parasternal systolic murmur 9/2025 labwork CBC WNL Chem Creat 1.6, BUN 31 T4 2.6 UA: DNP (last in 4/2025: USG 1.019 with creat 1.9, BUN 41) ProBNP 111 BP: 135 doppler ---Previous BP was 200 prior to starting amlodipine)

ULTRASONOGRAPHIC EXAMINATION OF THE HEART

8 efficiency video clips from SDEP protocol provided.

All four chambers revealed normal volumes and contractility. No evidence of volume overload nor pressure overload. No pericardial or pleural effusion noted.

No gross abnormalities that would preclude anesthesia.

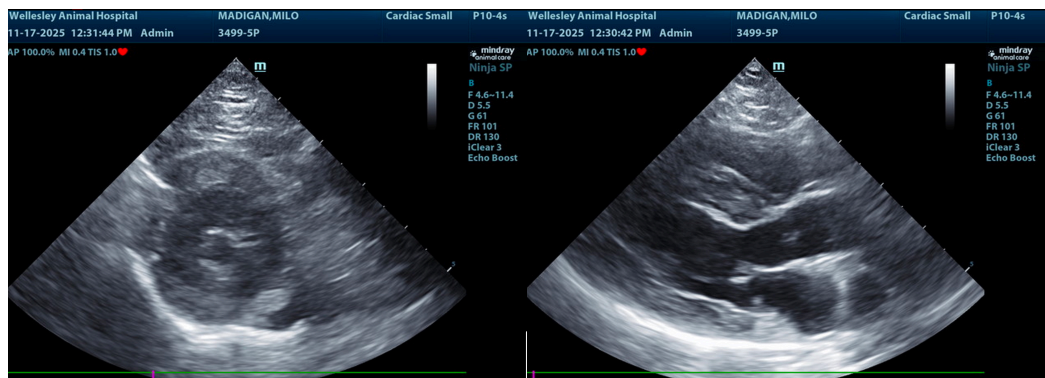
ULTRASONOGRAPHIC FINDINGS

- Normal pre-anesthetic echocardiogram.

INTERPRETATION OF THE FINDINGS & FURTHER RECOMMENDATIONS

Anesthetic risk is considered minimal: No gross abnormalities noted on SDEP^R Screening Echo to contraindicate anesthesia. No volume overload noted on the images presented.

1. Monitoring of blood pressure, SpO₂, CO₂, and auscultation of heart and lungs during anesthesia should be done during every procedure.





PATIENT

Milo Madigan

SPECIES

Feline

BREED

Domestic Shorthair

SEX

Neutered male

AGE

9 years

WEIGHT

14 lbs

INTERPRETED BY

Eric Lindquist, DMV
DABVP, Cert. IVUSS

IMAGING PERFORMED BY

Dr. Leal

HOSPITAL NAME

Wellesley AH

REFERRING VET

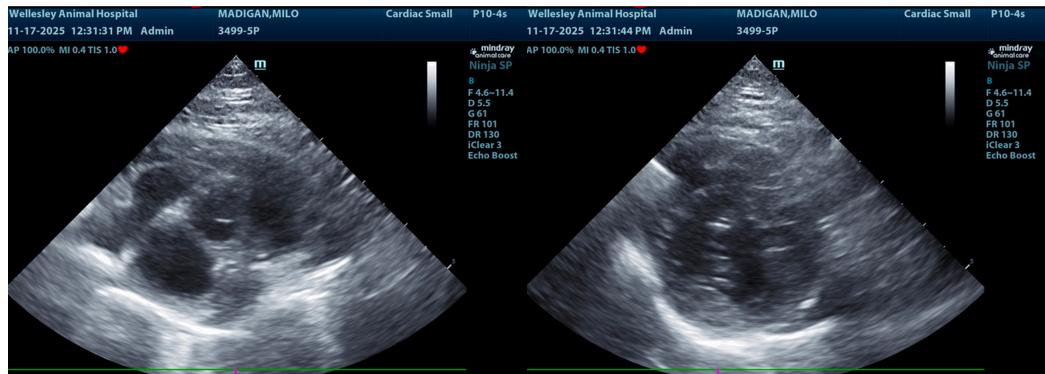
Dr. Bunn

INVOICE

68724

DATE

11/17/25



The information and recommendations provided are based on the images presented by the referring veterinarian/sonographer. No evaluation can be communicated regarding pathology that was not visible in the image/video clips provided.

Thank you for this referral. If the clinical or image interpretation does not parallel your findings or if I can be of any further assistance please contact me.

Eric Lindquist, DMV, DABVP (CFM), Cert. IVUSS, CEO of SonoPath.com

info@SonoPath.com